Magnetic Resonance Imaging

F.R.C.R. Physics Lectures

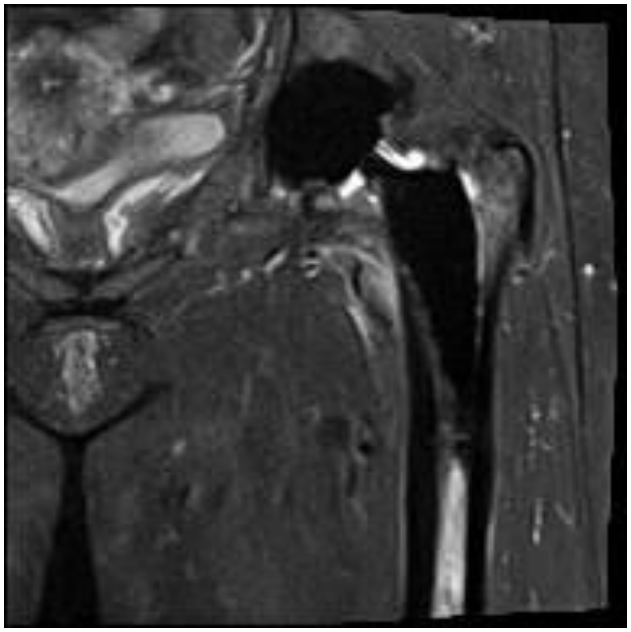

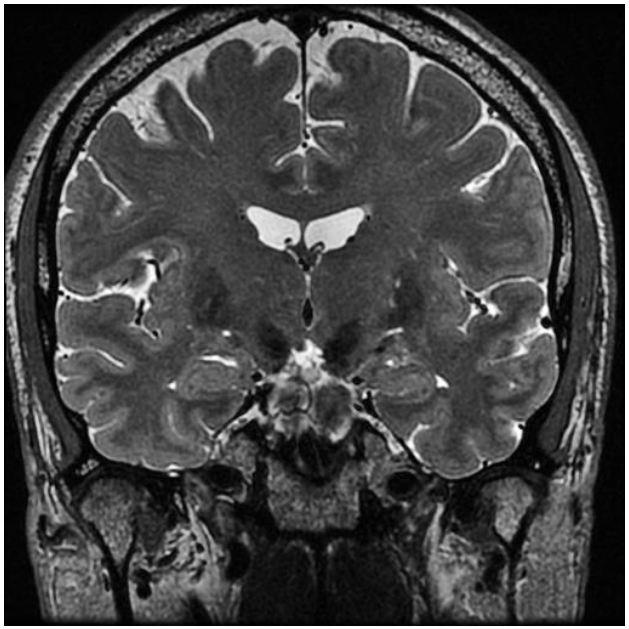

Lawrence Kenning PhD

7.9 MR artefacts and artefact reduction techniques

- Causes and potential solution for artefacts found in MRI, including:
- Motion artefacts, respiratory gating, navigated sequences, saturation bands, radial-type k-space acquisitions
- B_0 inhomogeneities, e.g. air/tissue interfaces or metal implants
- B_1 inhomogeneities especially at 3T
- RF interference: instantaneous (RF spikes); continuous RF interface
- Phase wrap
- Truncation artefact (Gibb's ringing)
- Chemical shift, receiver bandwidth
- Fat-water swaps in Dixon MRI
- Poor geometry-factor with high acceleration factors in parallel imaging
- *Other MR Artefacts*

What is an artefact?

- An image artefact in MRI is any unwanted image feature that does not represent the true anatomical structure or physiological information on the subject/object being scanned

- May degrade image or be more subtle

- Often can be related to a particular encoding direction

- Causes of artefacts broadly divided into three groups:

  - **Patient-related artefacts** tend to appear as ghosts along the phase-encoding direction. May be produced by physiological motion or involuntary movement by the patient.

  - **Physics and Hardware artefacts** usually cause signal intensity changes and image distortions, and are due to hardware imperfections and to the susceptibility effects within the human body; for example, air in the sinuses or blood breakdown products.

  - **Image reconstruction artefacts** have a variety of appearances, and include phase wrap-around artefacts and problems arising from the Fourier transform

Motion

- Most common artefact in MRI is patient motion
- Causes a range of ghosting artefacts depending on the severity of the motion
- Continuous movement during the scan causes a generalised blurring, often making the scan useless
- A few twitches or only small movements cause a few subtle ghosts which may leave an acceptable image
- In some cases, it is necessary to sedate or anesthetise the patient order to produce a diagnostic quality study

- Part of anatomy changes its location relative to encoding resulting in spatial blurring

- Ghosts can be discrete (periodic motion: cardiac beats, arterial pulsations, respiration) or diffuse (non-periodic), e.g. bowel peristalsis

- Principally occurs in **phase encoding** direction due to disparity in sampling times for frequency (msec) and phase (sec) encoding times
  - Also, motion along any magnetic field gradient results in abnormal phase accumulation, which mismaps the signal along the phase encoding gradient.

- To minimise the number of phase encoding steps (scan time), it is often desirable to orientate the phase-encoding direction to the shortest dimension of the patients anatomy

- However, consideration should always be given to potential sources of motion.

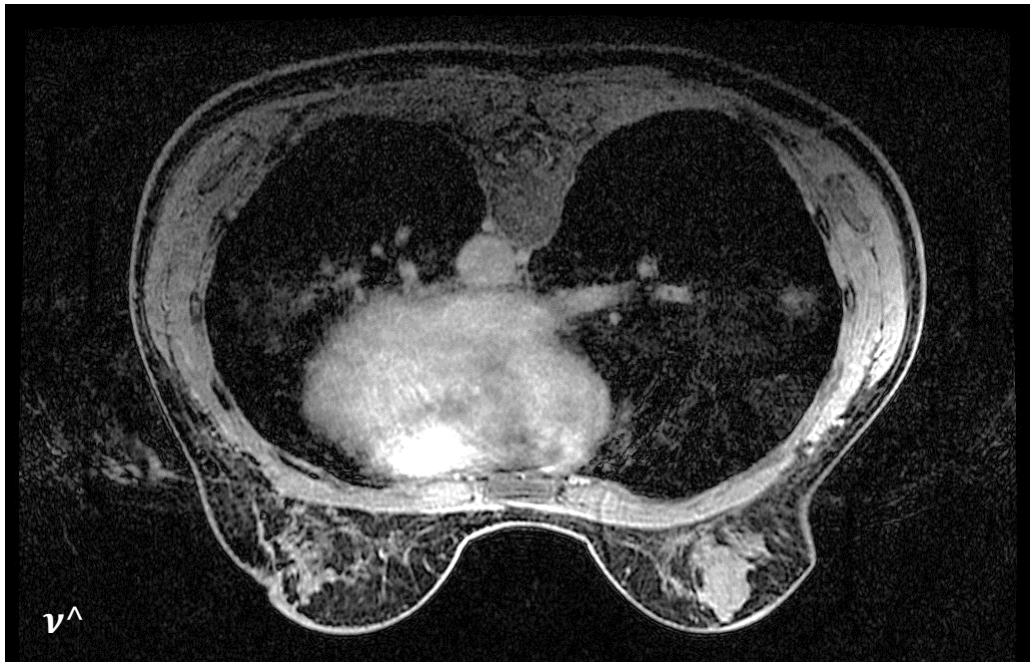

nu (ν) denotes the frequency encoding direction

^ or >

Motion/Ghosting Examples - Gross Patient Motion

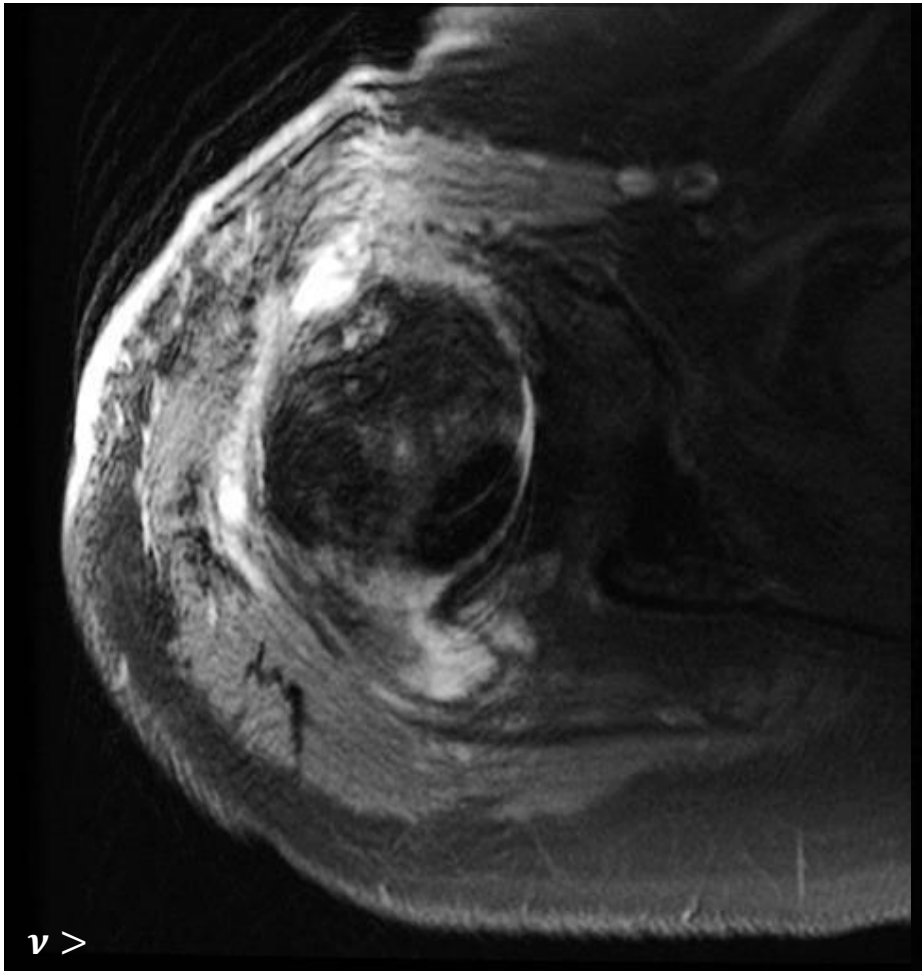

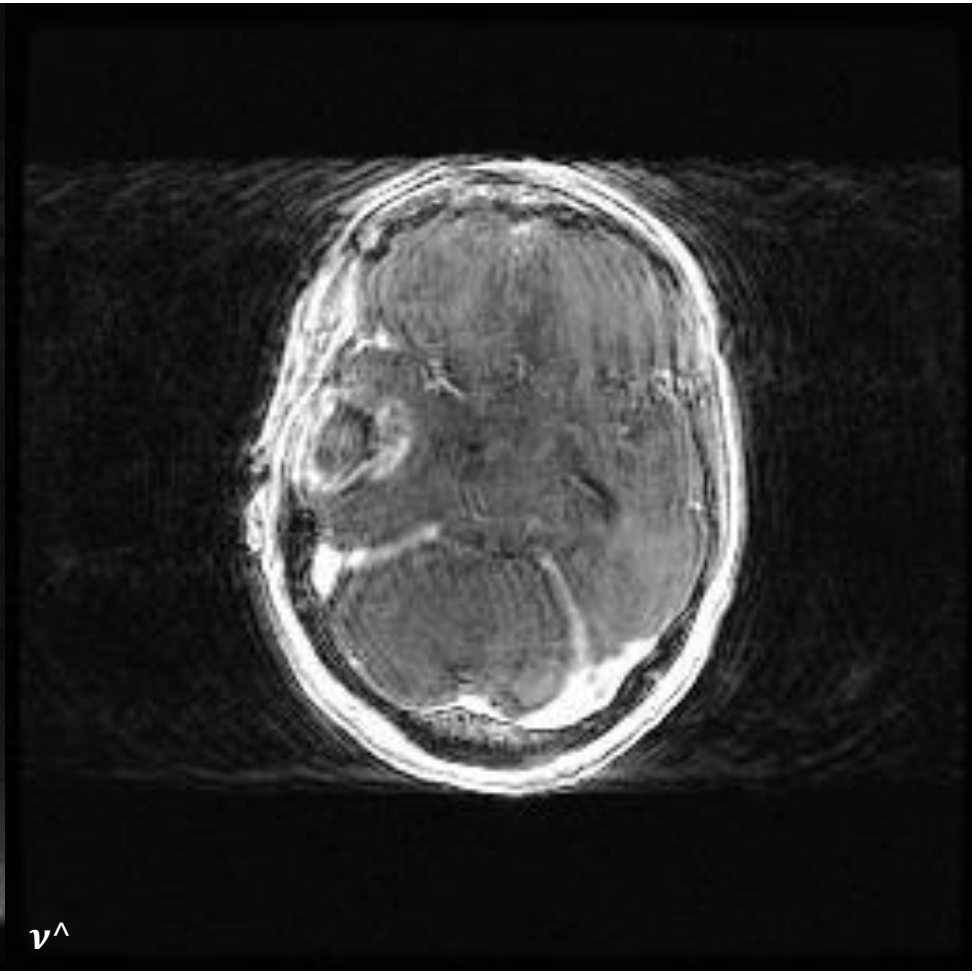

Motion/Ghosting Examples - Gross Patient Motion

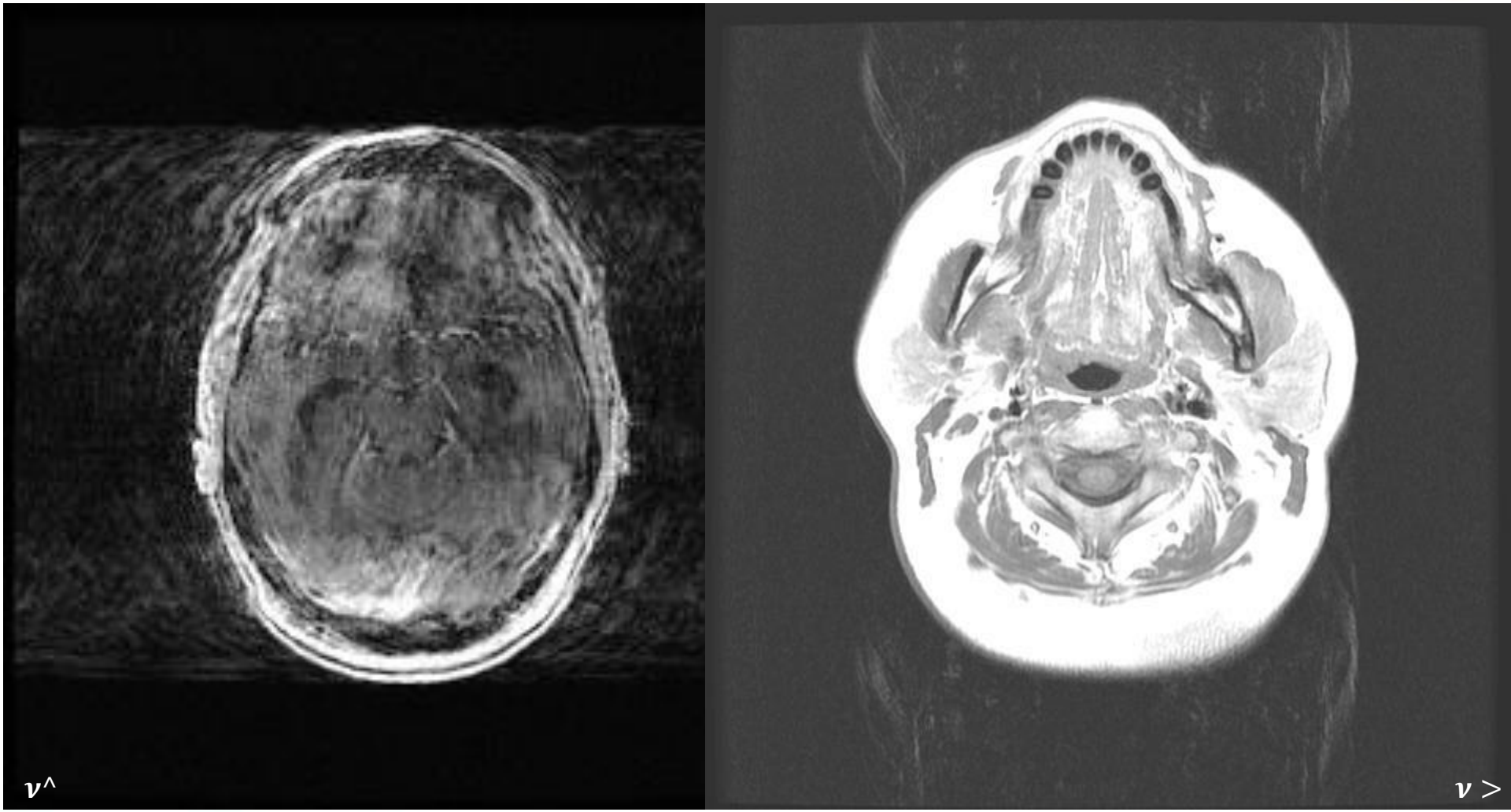

Motion/Ghosting Examples – Respiratory Motion

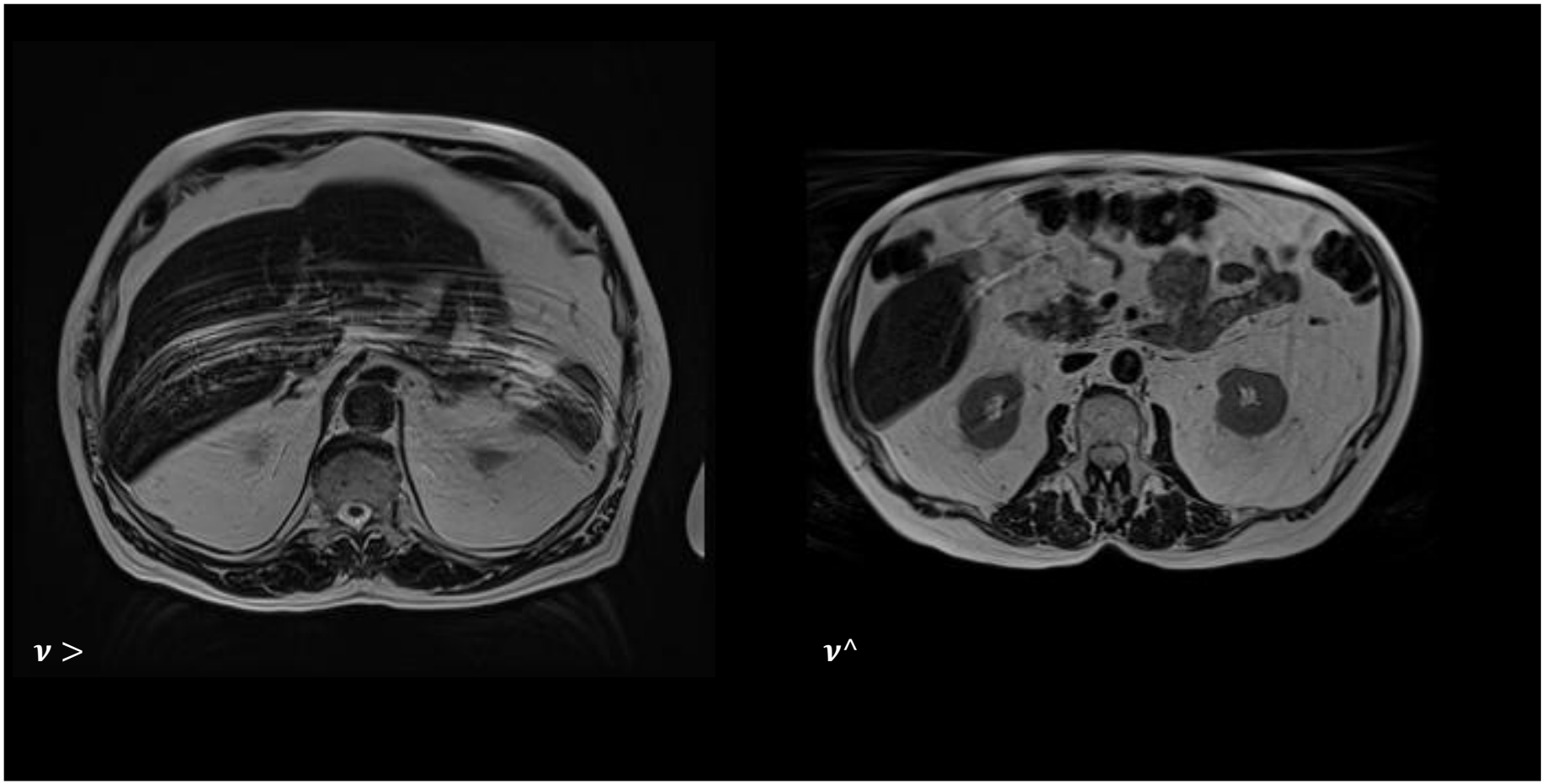

Flow artefacts

- Constitute a particular subset of physiological motion artefacts.
- The pulsatile motion of blood within the vascular system can produce ghosting in the image.
- Occur in the phase encoding direction
  - Separation of the ghosts determined by the frequency of the pulsating blood
- Same principle at motion/ghosting artefacts

Motion/Ghosting Examples – Flow





CSF flow related dephasing

- Flow-related dephasing is greater in sequences with longer TEs
  - exaggerates the dephasing, as there is a longer delay before the echo is measured

- Turbulent flow is too unpredictable to compensate even with flow compensation



Motion/Ghosting: Reduction

- Restrict patient motion (pads / sedation)
- Optimise PE & FE direction
- Respiratory gating
  - Periodic motion can be ‘gated’. Cardiac/respiratory triggered scanning / Longer scan times
- Navigated sequences
- Saturation bands
  - Suppress the signal from moving tissues with signal suppression techniques
- Radial-type k-space acquisitions
- Alternatively use ‘breath hold’ or ‘single shot’ techniques
- Non-periodic motion more difficult
  - Anti-peristalsis drugs (buscopan)

Respiratory Triggered

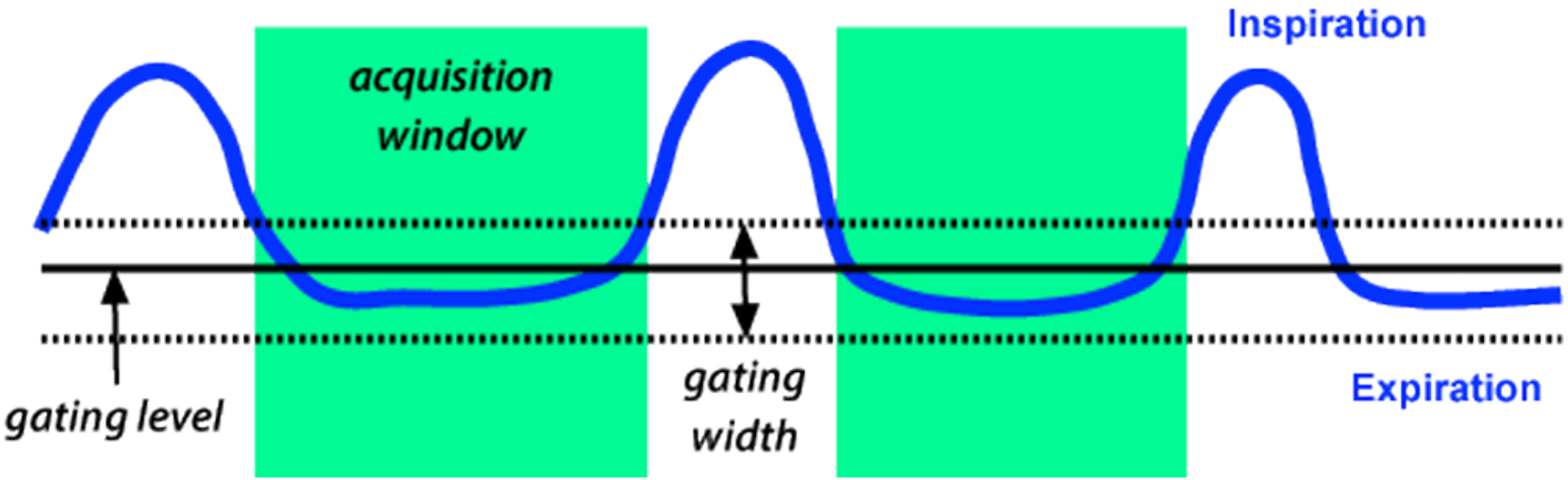



https://mriquestions.com/respiratory-comp.html

Respiratory Triggered - 2D T2 FSE (Failure)

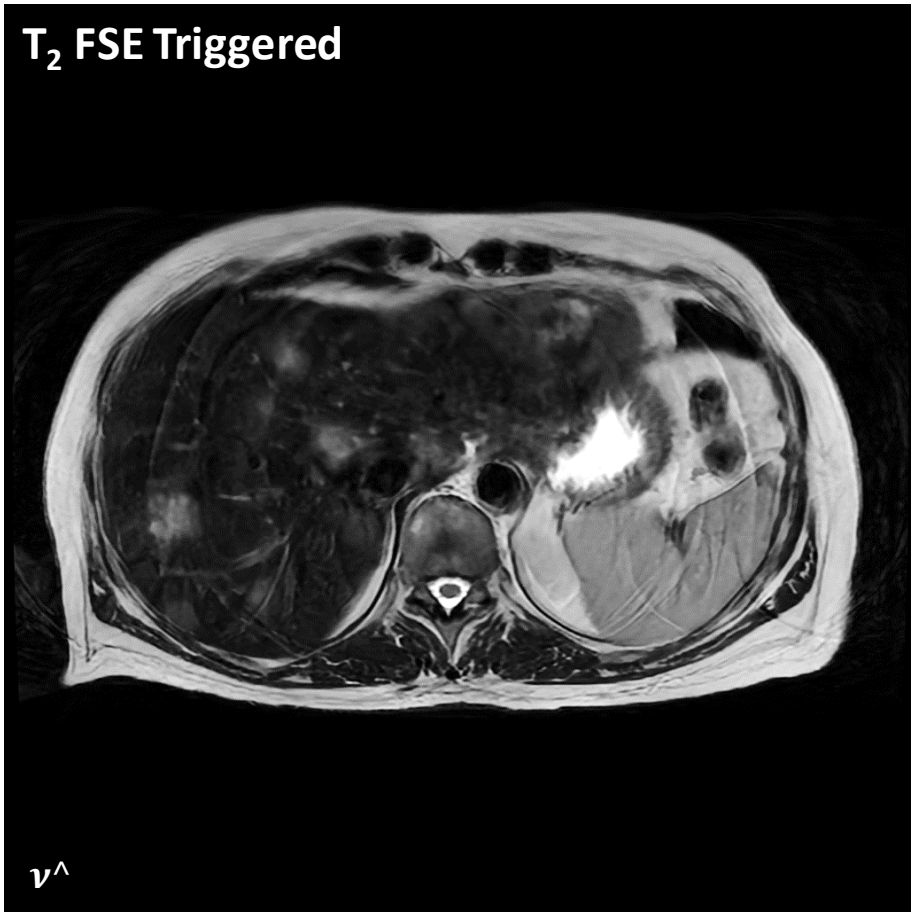



Navigated sequences

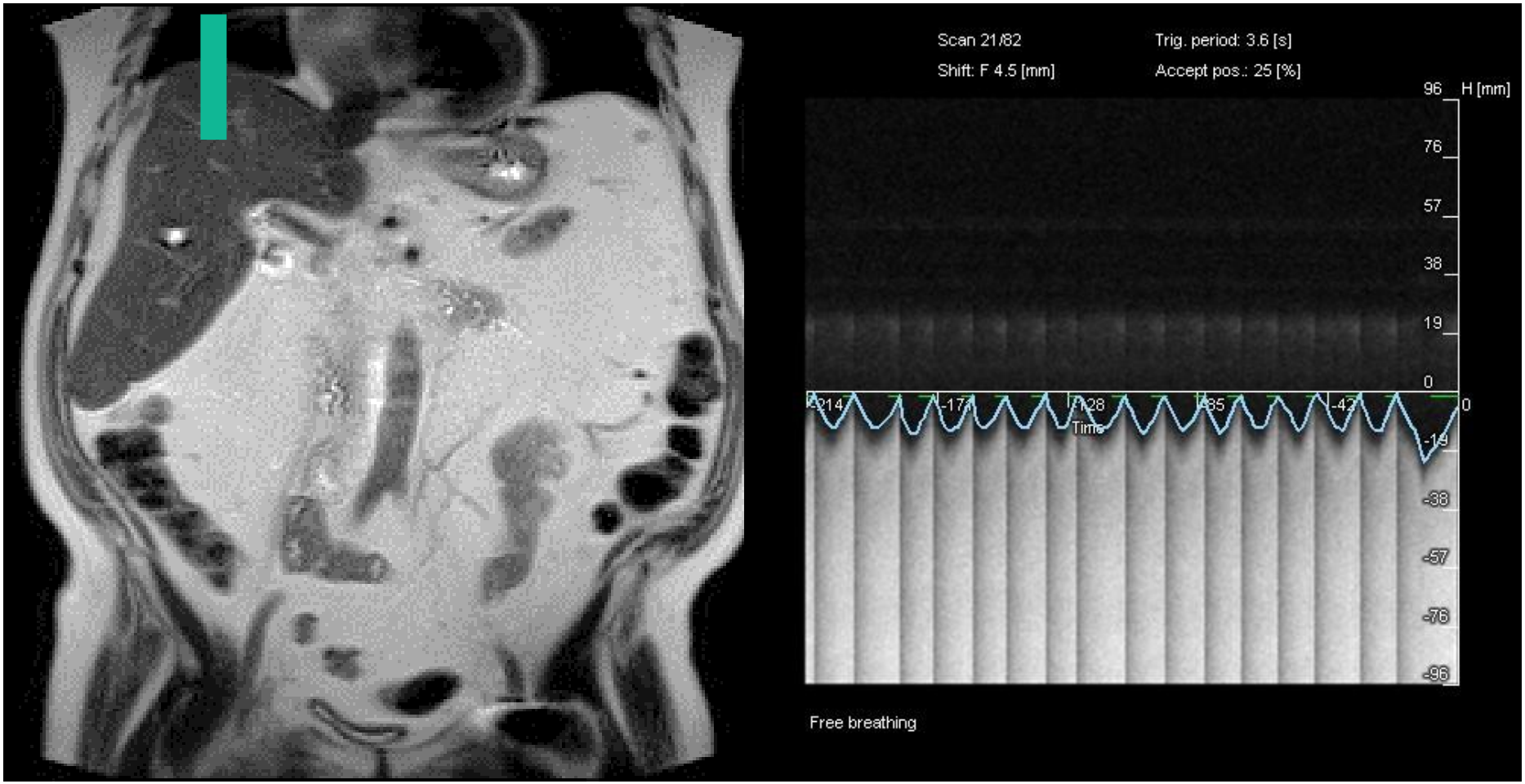

Navigated sequences

Navigators are additional RF-pulses used to dynamically track anatomic motion, especially superior-inferior position of the diaphragm.

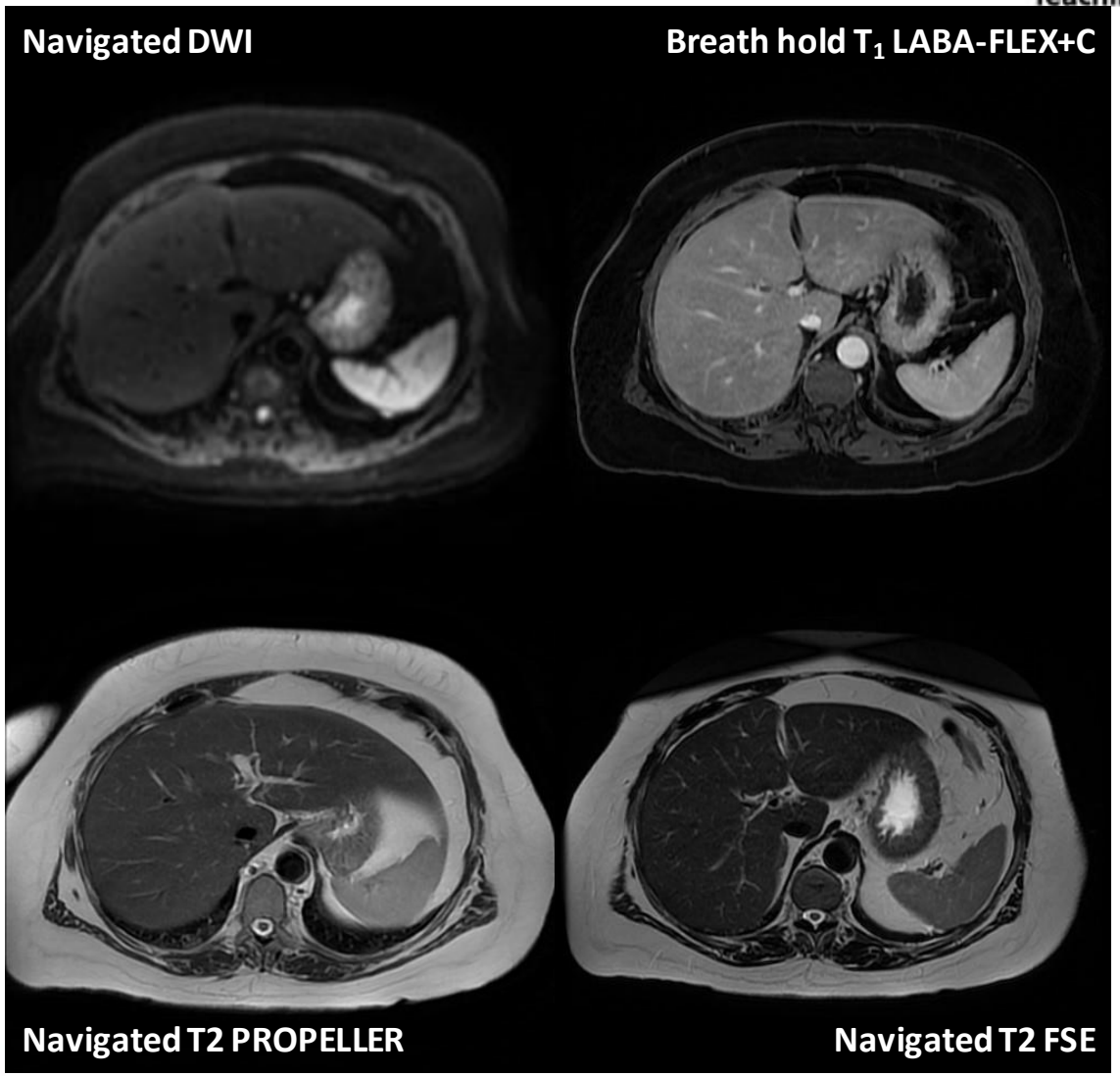

ECG Triggered

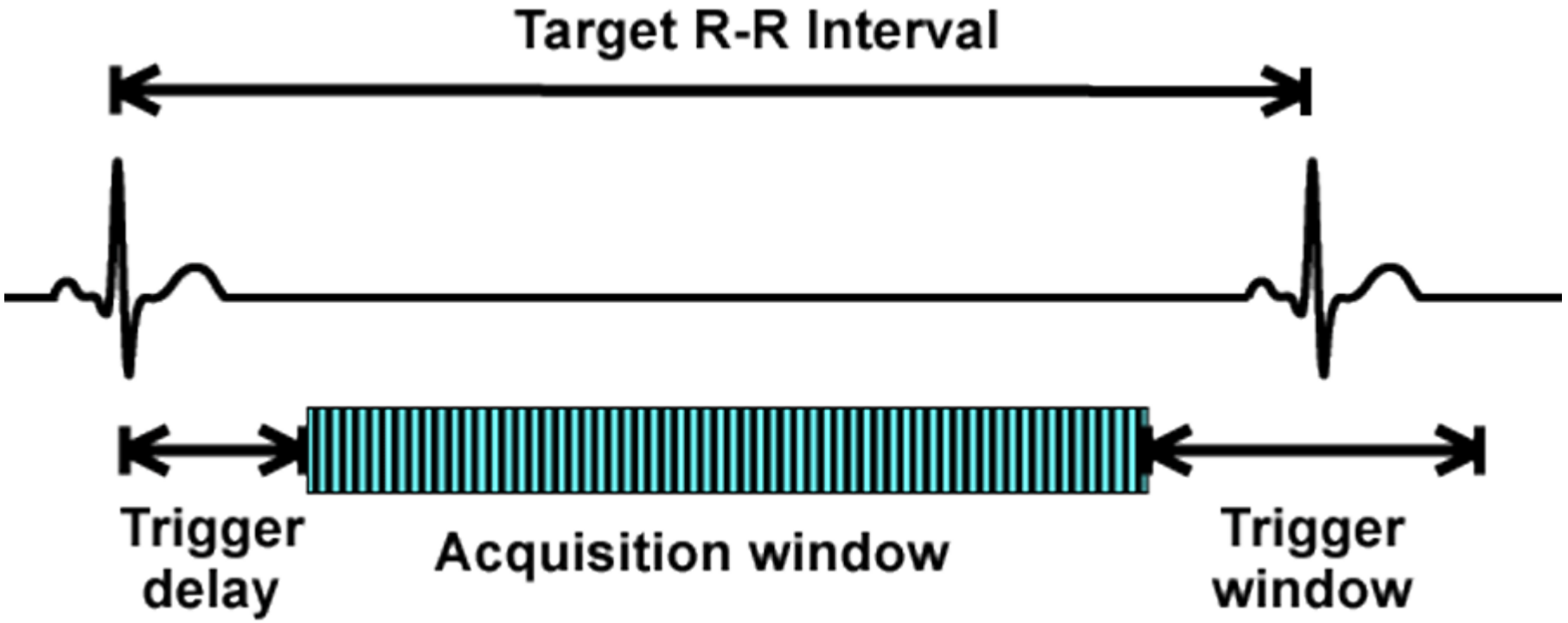

The R-R interval in milliseconds (msec) and the heart rate in beats per minute (bpm) are inversely related by the formula:

R-R (msec) = 60,000 ÷ heart rate (bpm)

Heart rates of 60–100 bpm therefore correspond to R-R intervals of 1000–600 msec.

ECG Gated - 2D Gated CINE-SSFP Breath hold

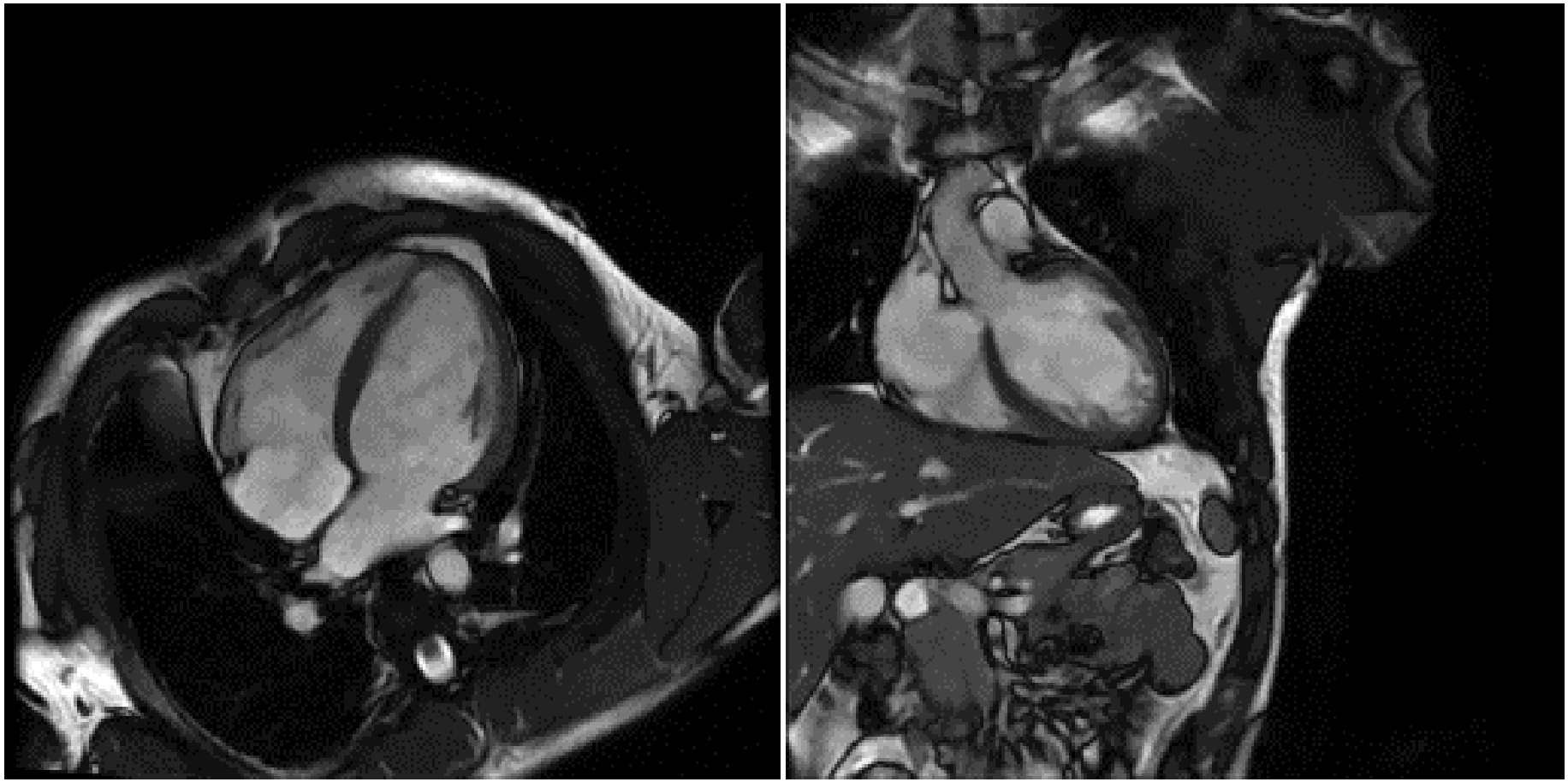

Radial-type k-space acquisitions

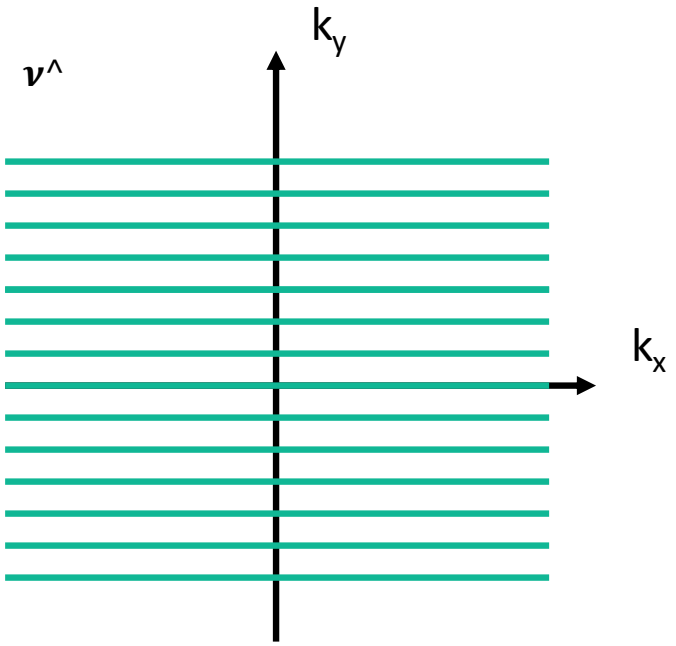

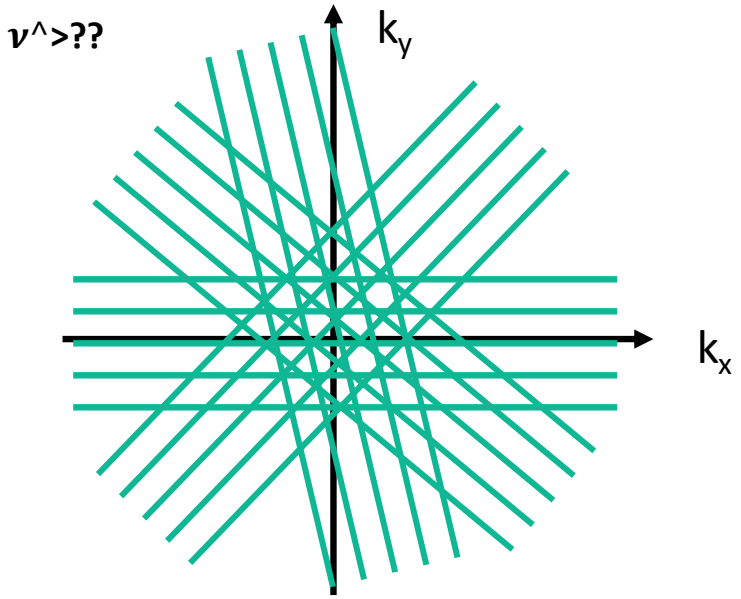

GRE or SE: one line of k-space per TR
(usually 256, 512 lines)
Image time = $N_{phase} \times TR$

Radial:
Centre oversampled
Motion compensation

Radial-type k-space acquisitions

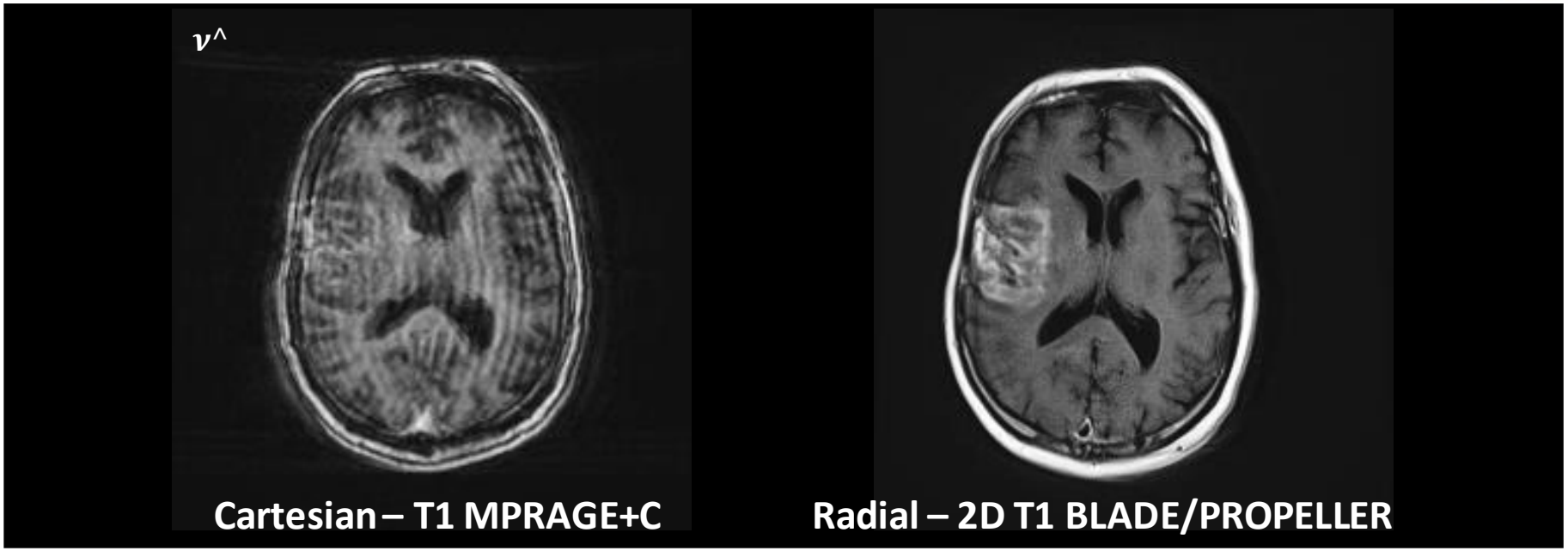

k-space trajectory	Advantages	Disadvantages
Cartesian	Simple to acquire. Minimal distortion artefacts. Works with parallel imaging	Prone to ghosting in PE direction. Requires complete filling of k-space. Image contrast generated ½ way through acquisition.
Radial	Motion insensitive Generally high SNR	The corners of k-space are not sampled slightly reducing image sharpness. Complete coverage of the k-space circle (without gaps between the blades) takes ≈ 1.57 times as long than Cartesian filling method. FSE/TSE variants are SAR intensive.

PROPELLER (Periodically Rotated Overlapping ParallEL Lines with Enhanced Reconstruction)

2D TSE/FSE BLADE/PROPELLER

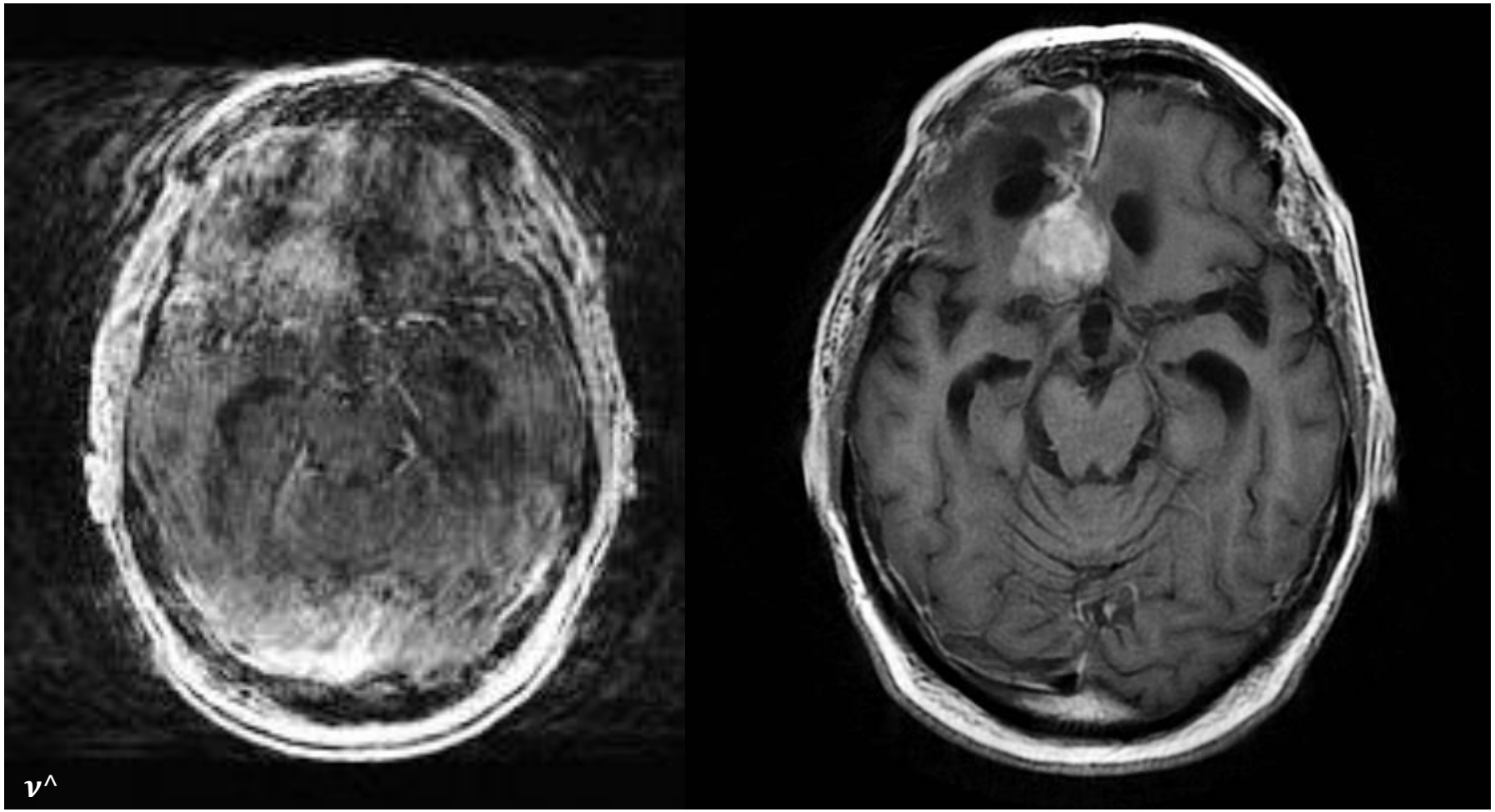

PROPELLER (Periodically Rotated Overlapping ParallEL Lines with Enhanced Reconstruction)

2D TSE/FSE BLADE/PROPELLER



T_1 Weighted PROPELLER

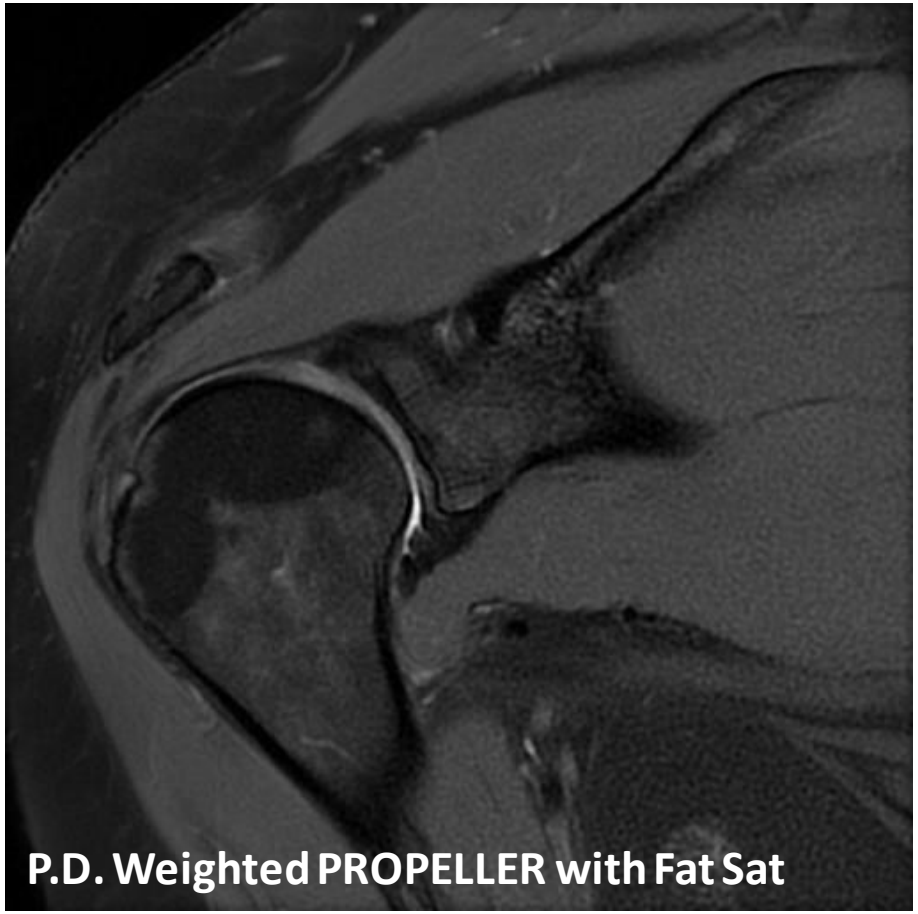

P.D. Weighted PROPELLER with Fat Sat

PROPELLER (Periodically Rotated Overlapping ParallEL Lines with Enhanced Reconstruction)

2D TSE/FSE BLADE/PROPELLER





PROPELLER (Periodically Rotated Overlapping ParallEL Lines with Enhanced Reconstruction)

2D TSE/FSE BLADE/PROPELLER



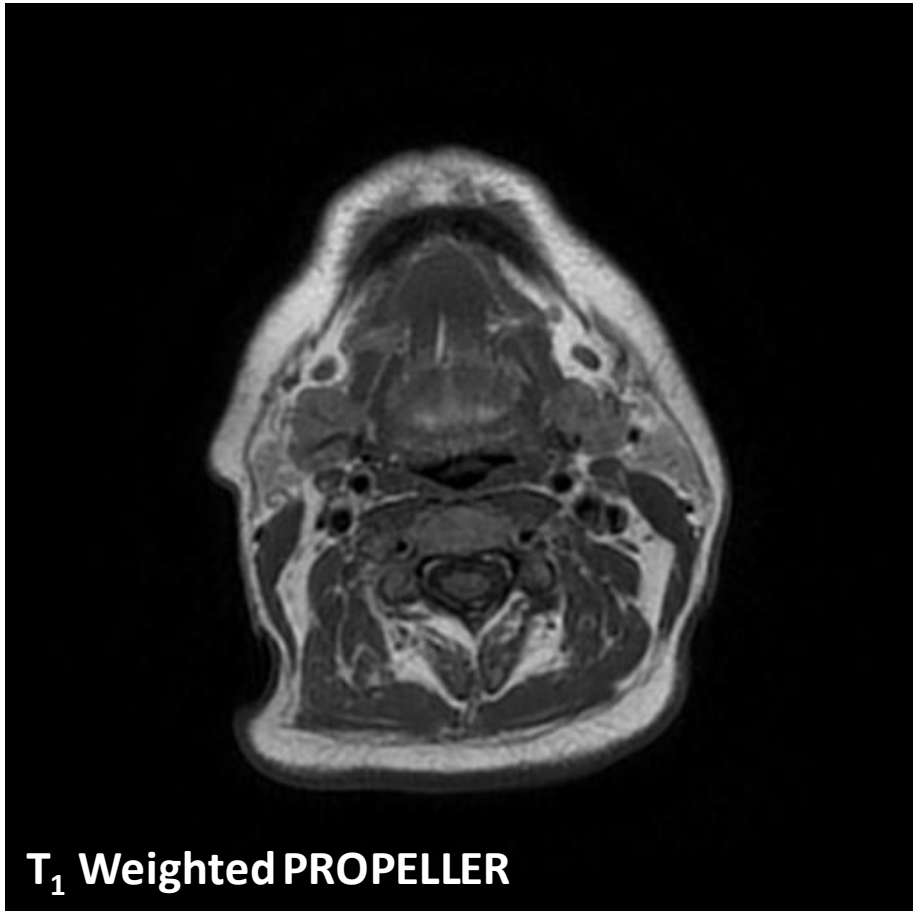

PROPELLER (Periodically Rotated Overlapping ParallEL Lines with Enhanced Reconstruction)

LAVA-STAR
3D-Radial Stack of Stars

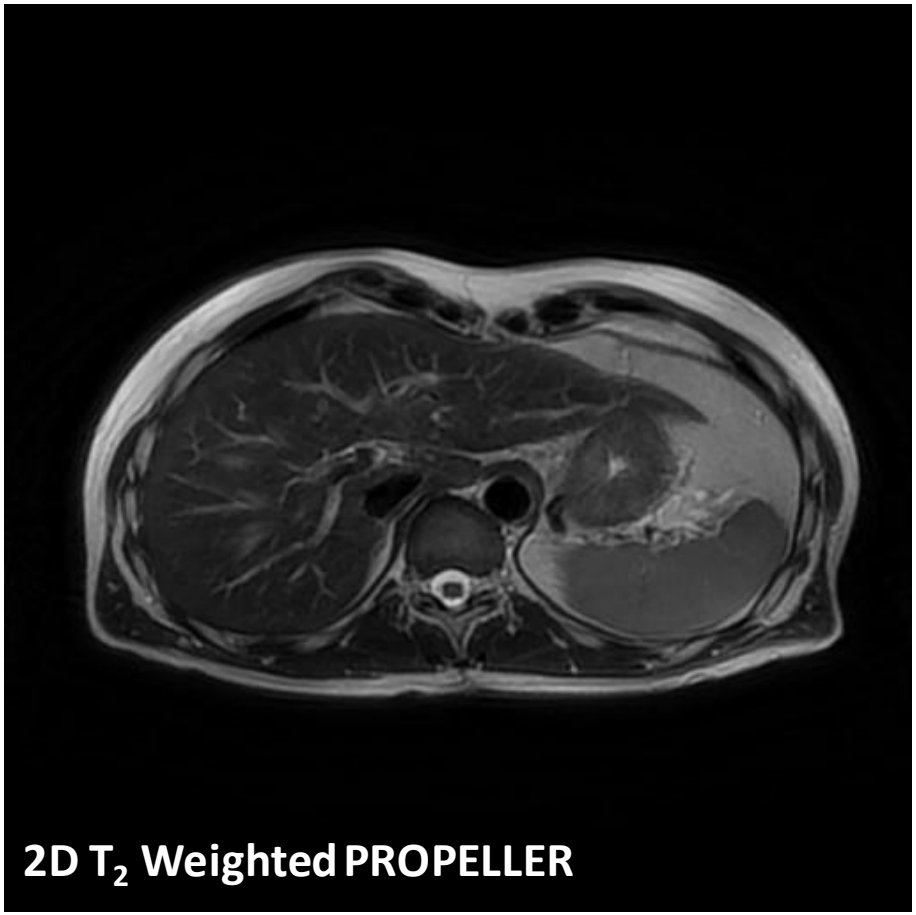

2D T_2 Weighted PROPELLER

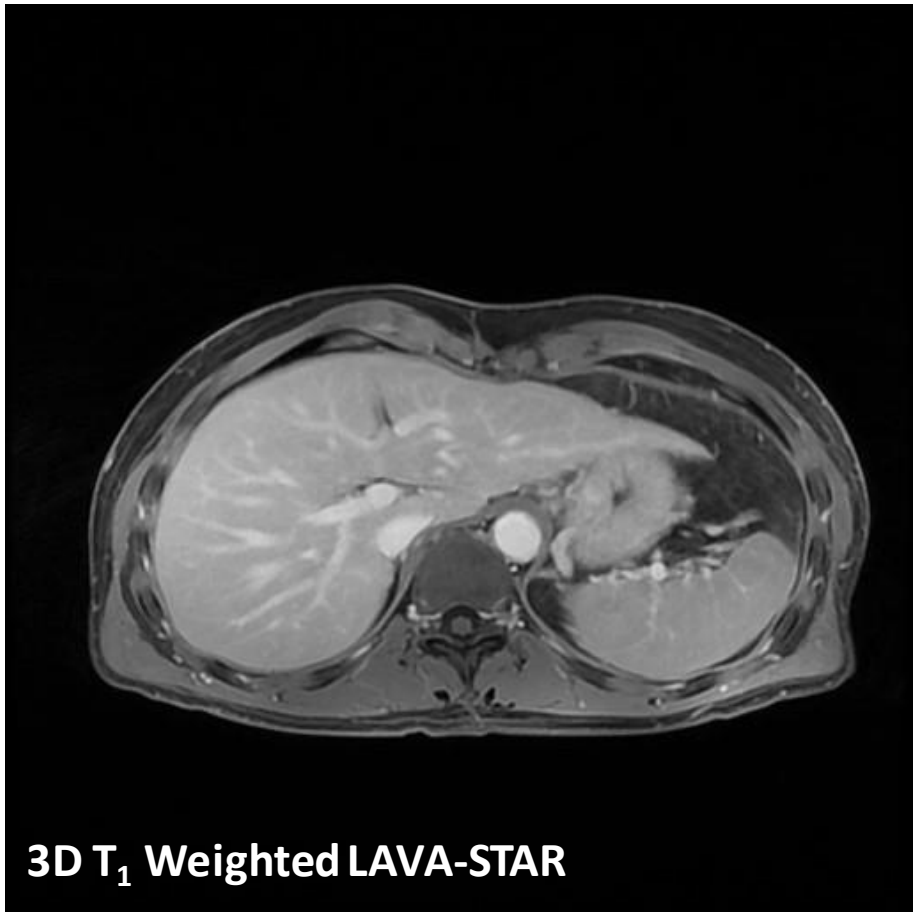

3D T_1 Weighted LAVA-STAR

Phase/Frequency Direction & Saturation Bands







No anterior saturation band **anterior saturation band**

Saturation Bands are based around a spatially selective 90° RF pulse that flips magnetisation into the transverse plane. Utilise a different carrier frequency to imaging pulses and are designed to produce maximal phase dispersion across the saturation band. Followed by strong spoiler gradients placed along the FE and PE axes to further suppress residual transverse magnetisation.

https://mriquestions.com/saturation-pulses.html

Asymmetric Saturation band

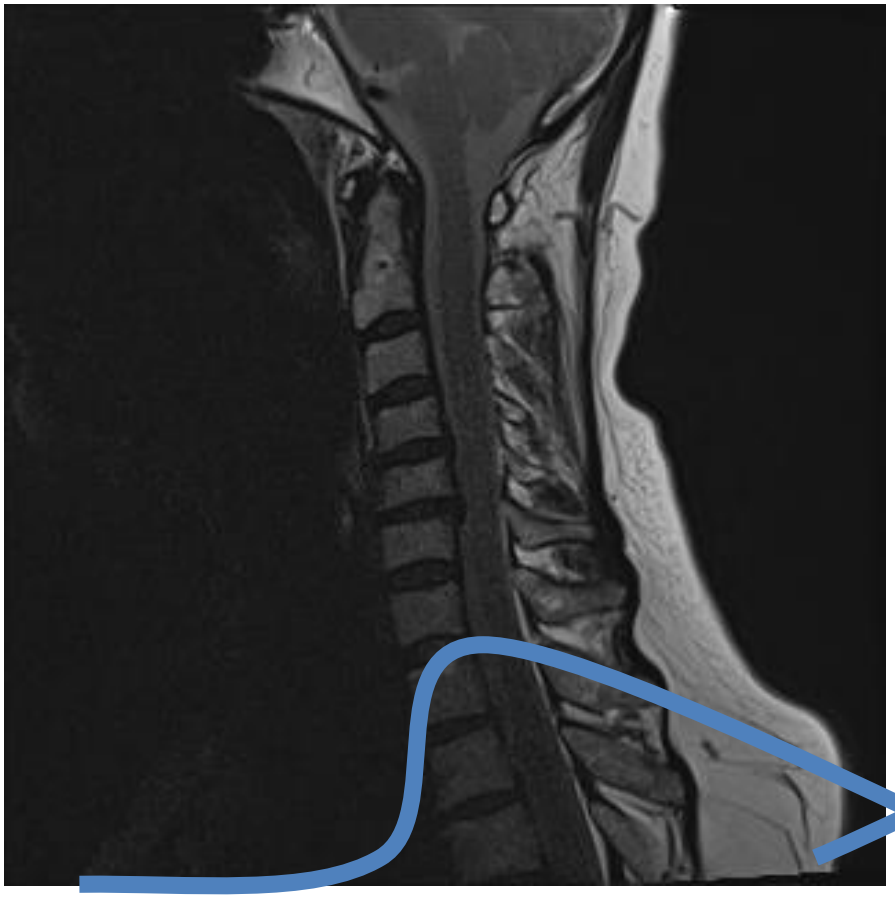

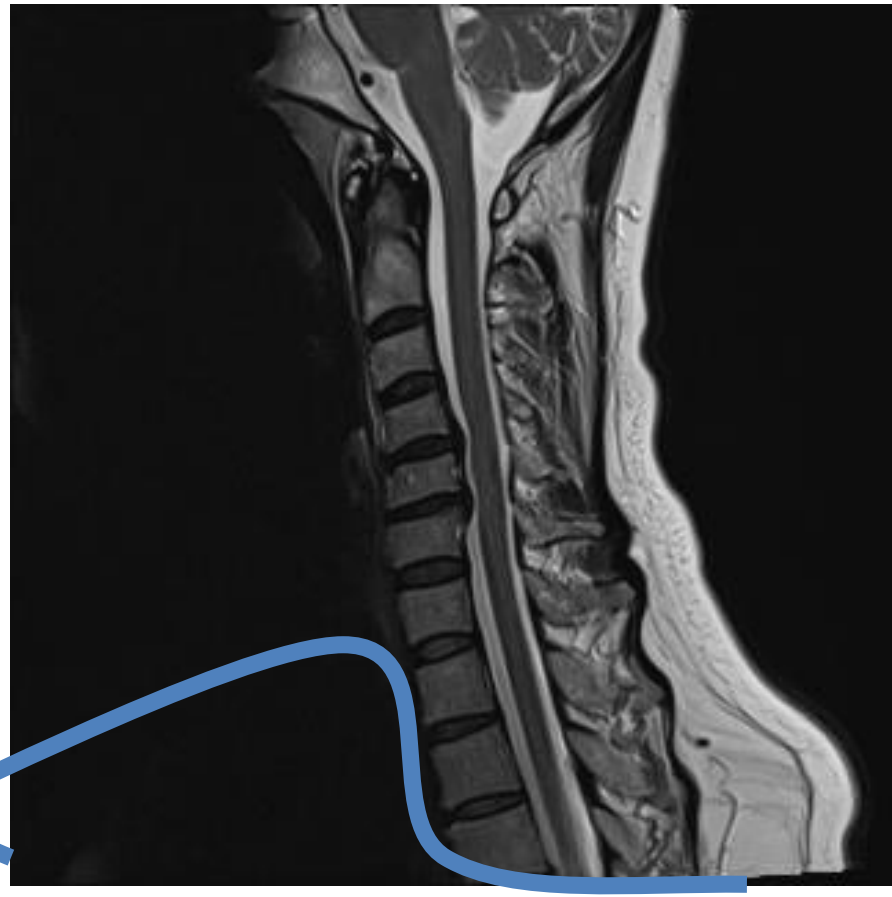

Asymmetric Saturation band

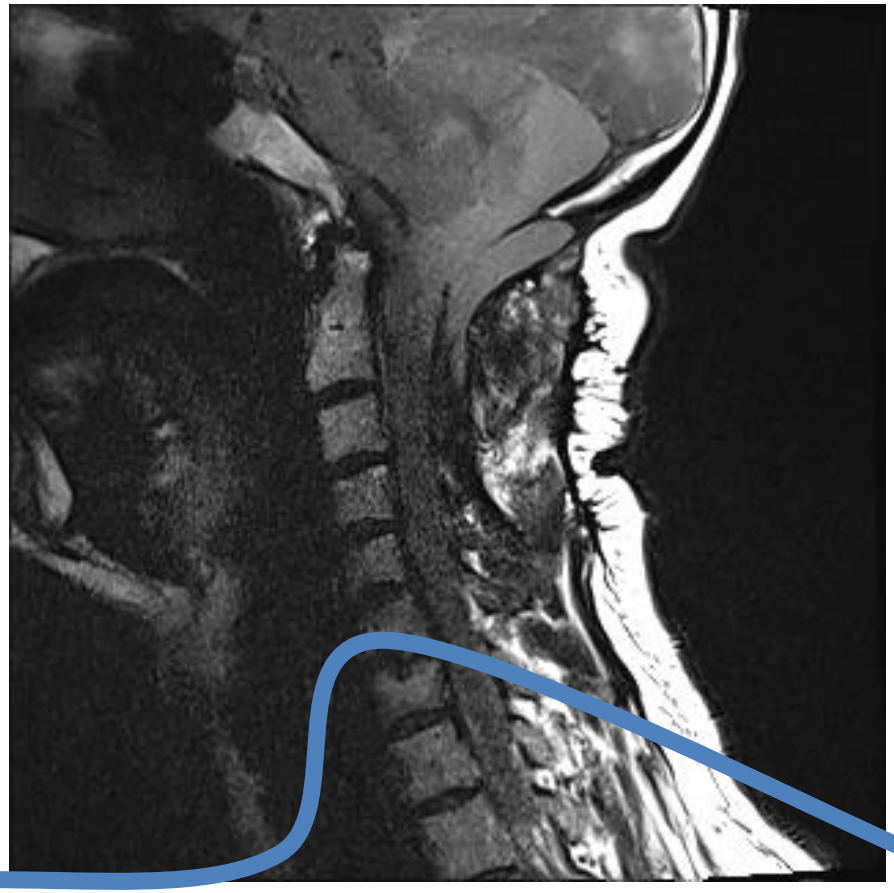

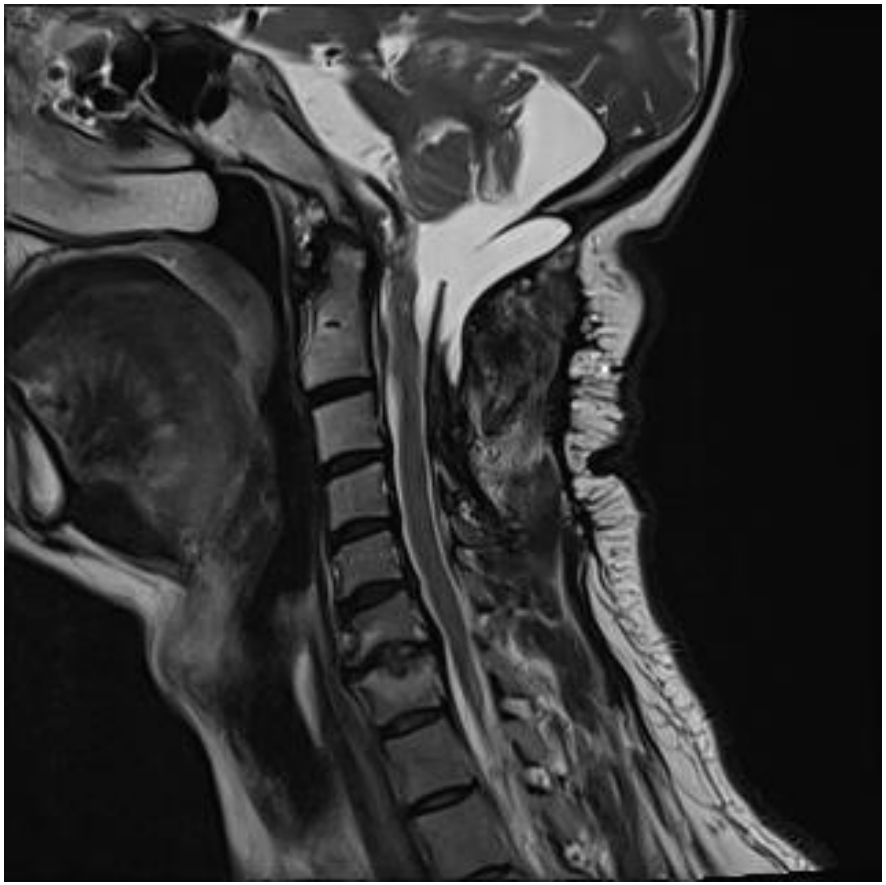

Magnetic Susceptibility (χ – "chi")

Susceptibility is defined as the magnitude of the internal polarization (J) divided by the strength of the external field (B): $\chi = J / B_0$

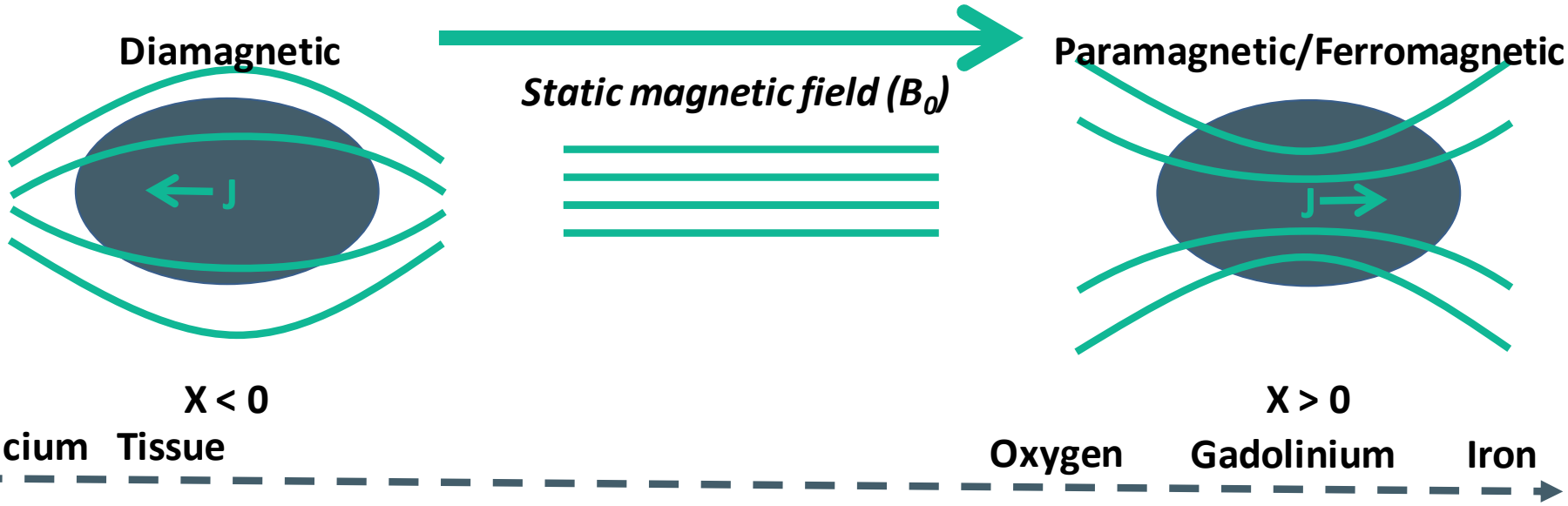

- Nearly all biological tissues are weakly **diamagnetic**
- Some tissues contain focal accumulations of metals such as iron, gadolinium, copper, or manganese that concentrate the magnetic field and are therefore **paramagnetic**
- A few tissues also contain chunky iron-based protein conglomerates (ferritin and hemosiderin) that are **superparmagnetic**.

Magnetic Susceptibility Artefact

- Although the magnetic susceptibility of tissues is small, the differences between the tissues & air are large enough generate local magnetic field gradients.
  - Hydrogen atoms on either side of the boundary will be in different magnetic fields & will relax more quickly as they interact with each other

- Artefacts occur at interfaces between materials of very different susceptibilities as local distortions are caused in the magnetic field.
  - Natural boundaries e.g. air / tissue or tissue/bone
  - Also any metal (not just ferromagnetic)

- Results in local distortions
  - Local field distortion can lead to precessional frequency shift → when G_{ss} is performed there is an absence of spin excitation and absence of signal
  - When signal is acquired → shift of spatial localisation which causes signal loss and/or image distortion.

Susceptibility Examples

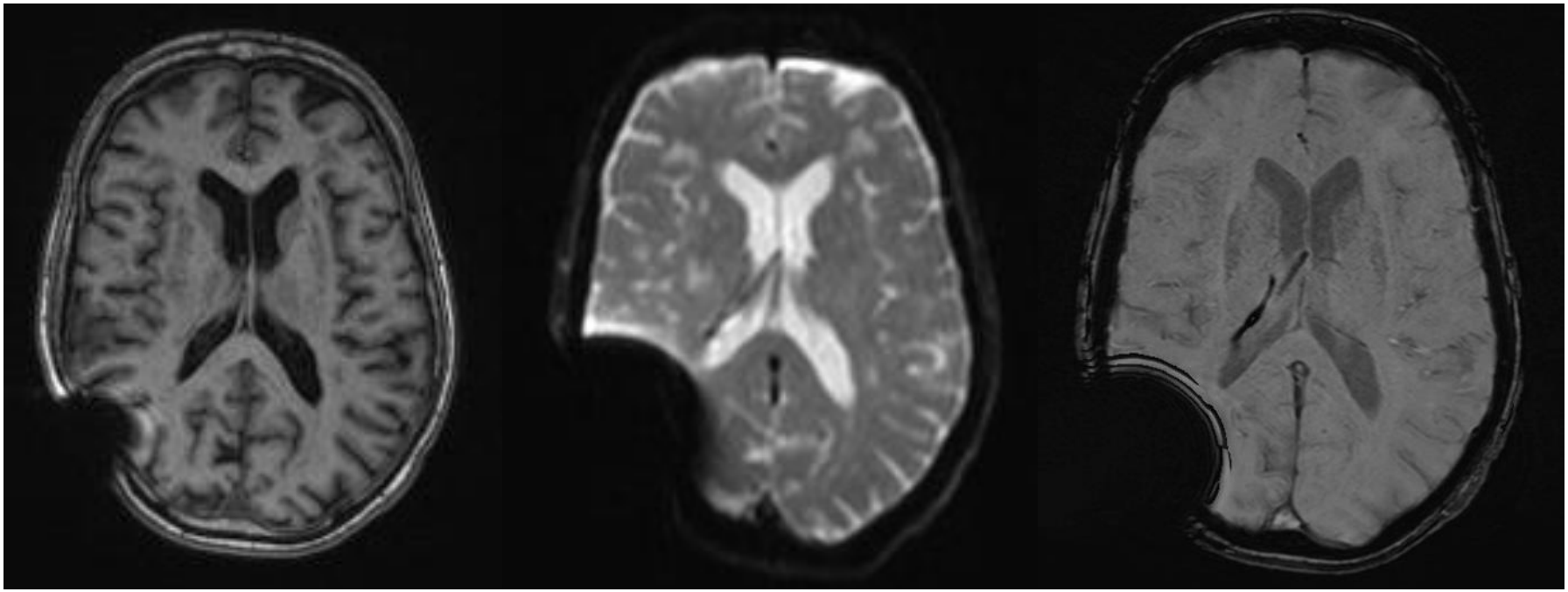

- Shunt producing a large susceptibility artefact
  - Signal void
  - distortion of anatomy

- Artefact worse at long TE (short TE allows less time for signal loss)

Susceptibility Examples

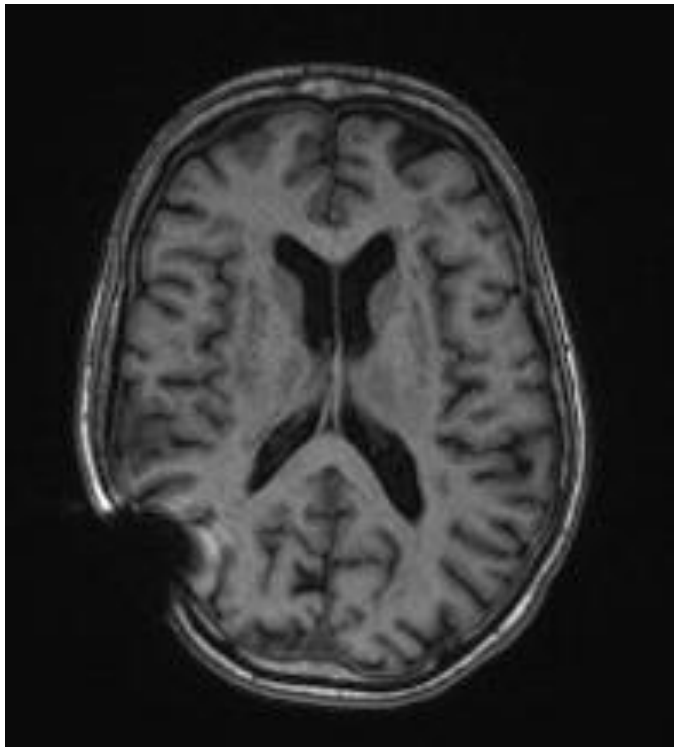

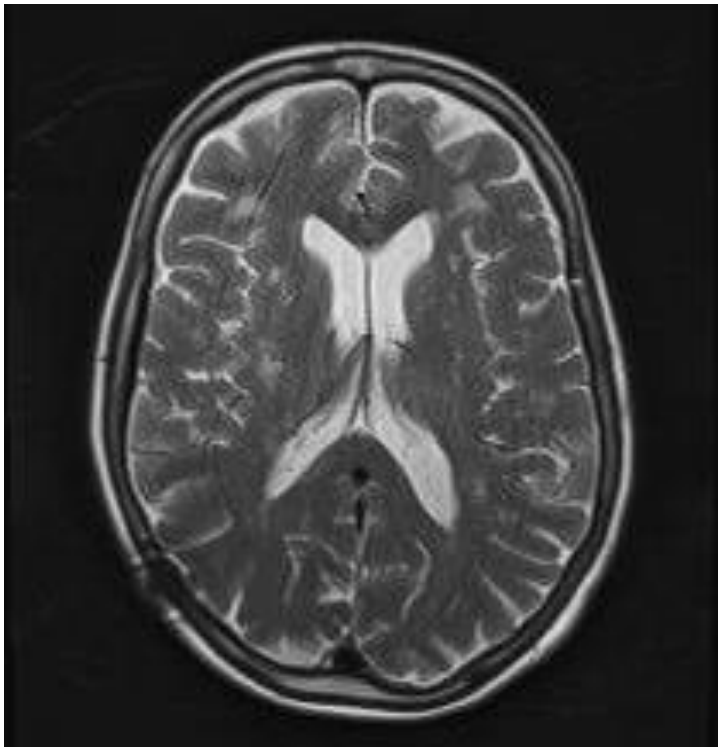

- Can be reduced by using SE (not GRE) or high bandwidths
- Special metal artefact reduction sequences (MARS)
  e.g. MAVRIC SL / SEMAC

Susceptibility Examples

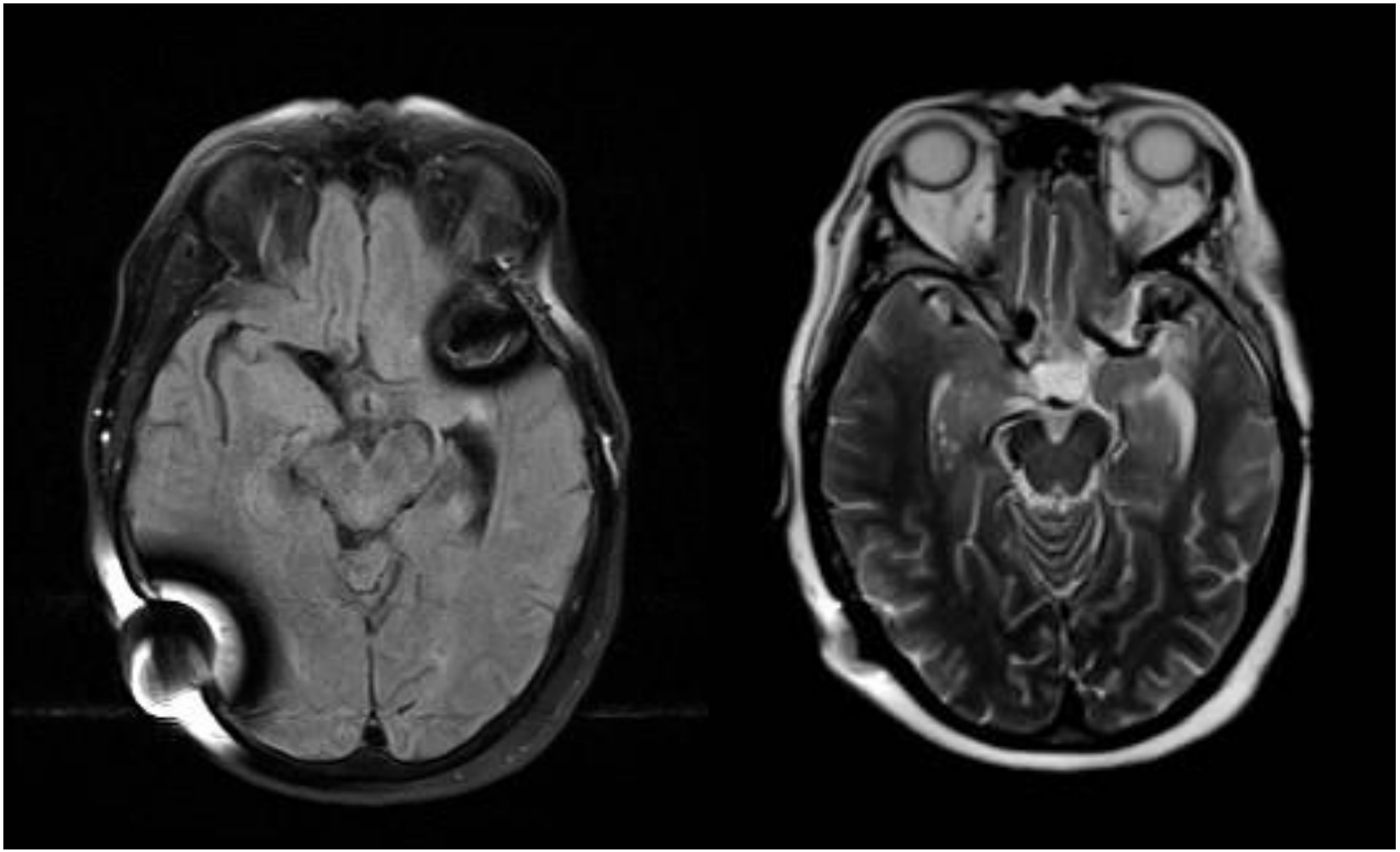

B_0 inhomogeneities, e.g. air/tissue interfaces or metal implants

NHS
Hull University Teaching Hospitals
NHS Trust

Braces

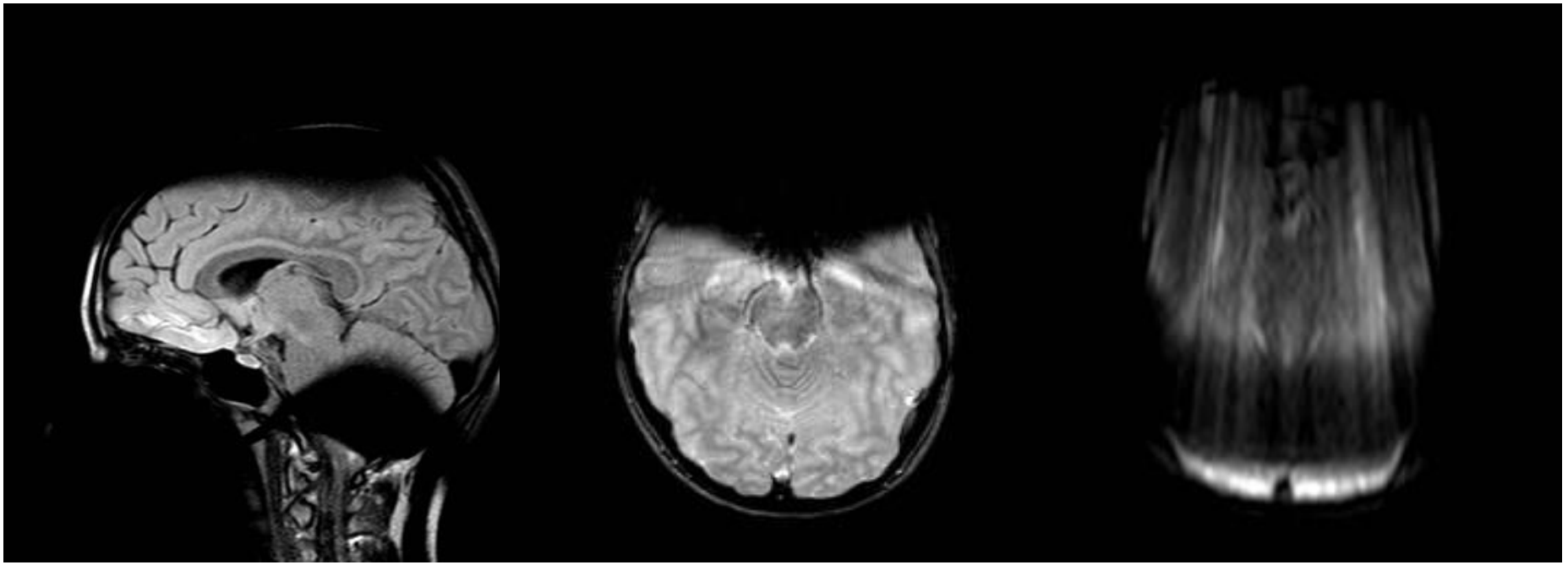

B_0 inhomogeneities, e.g. air/tissue interfaces or metal implants

Braces

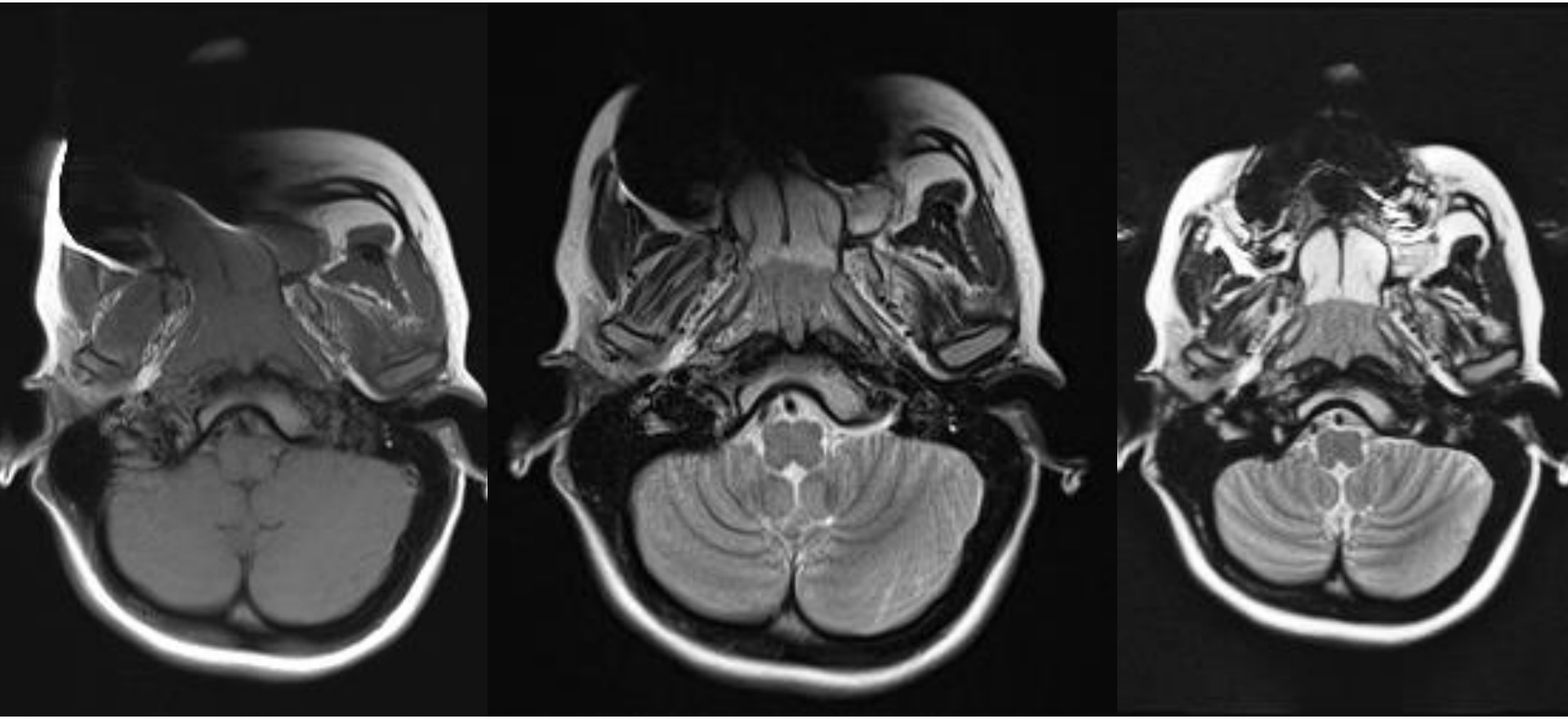

B_0 inhomogeneities, e.g. air/tissue interfaces or metal implants

EPI vs FSE DWI

EPI-DWI

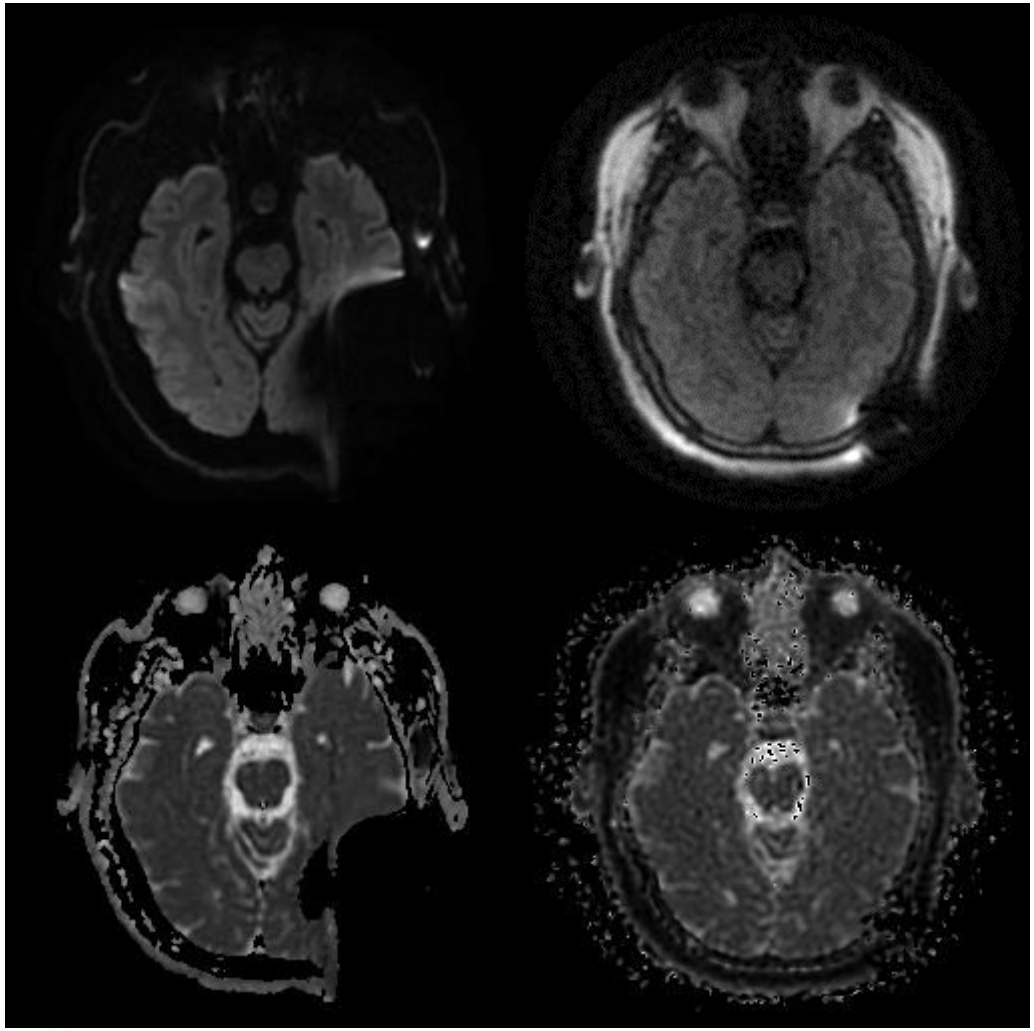

FSE-DWI

EPI-DWI ADC

FSE-DWI ADC

B_0 inhomogeneities, e.g. air/tissue interfaces or metal implants

Susceptibility Examples

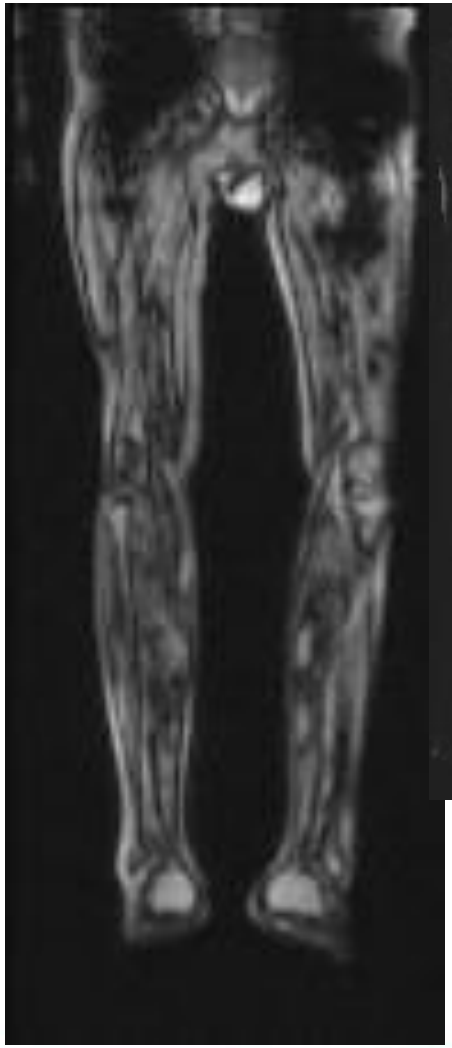

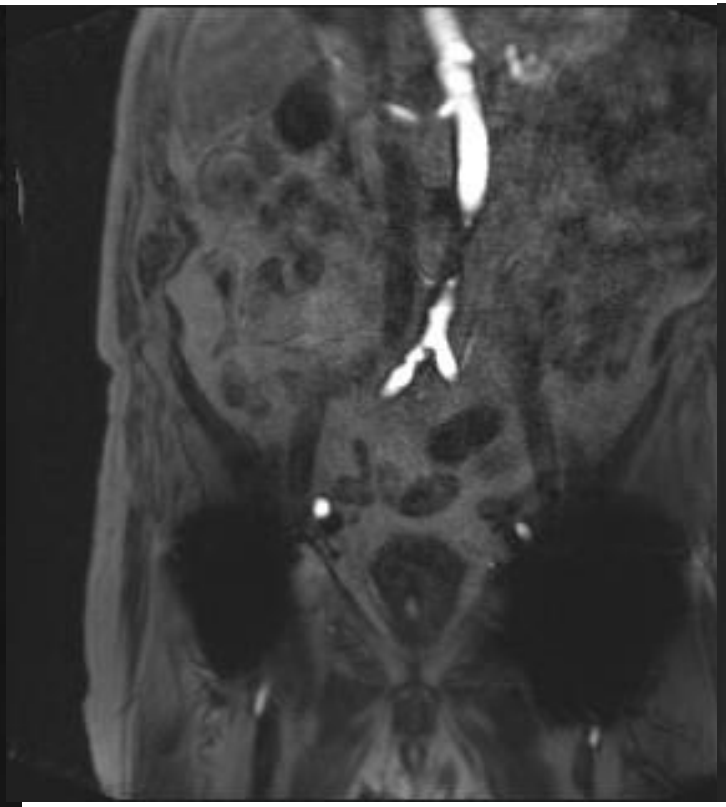



B_0 inhomogeneities, e.g. air/tissue interfaces or metal implants

DIXON

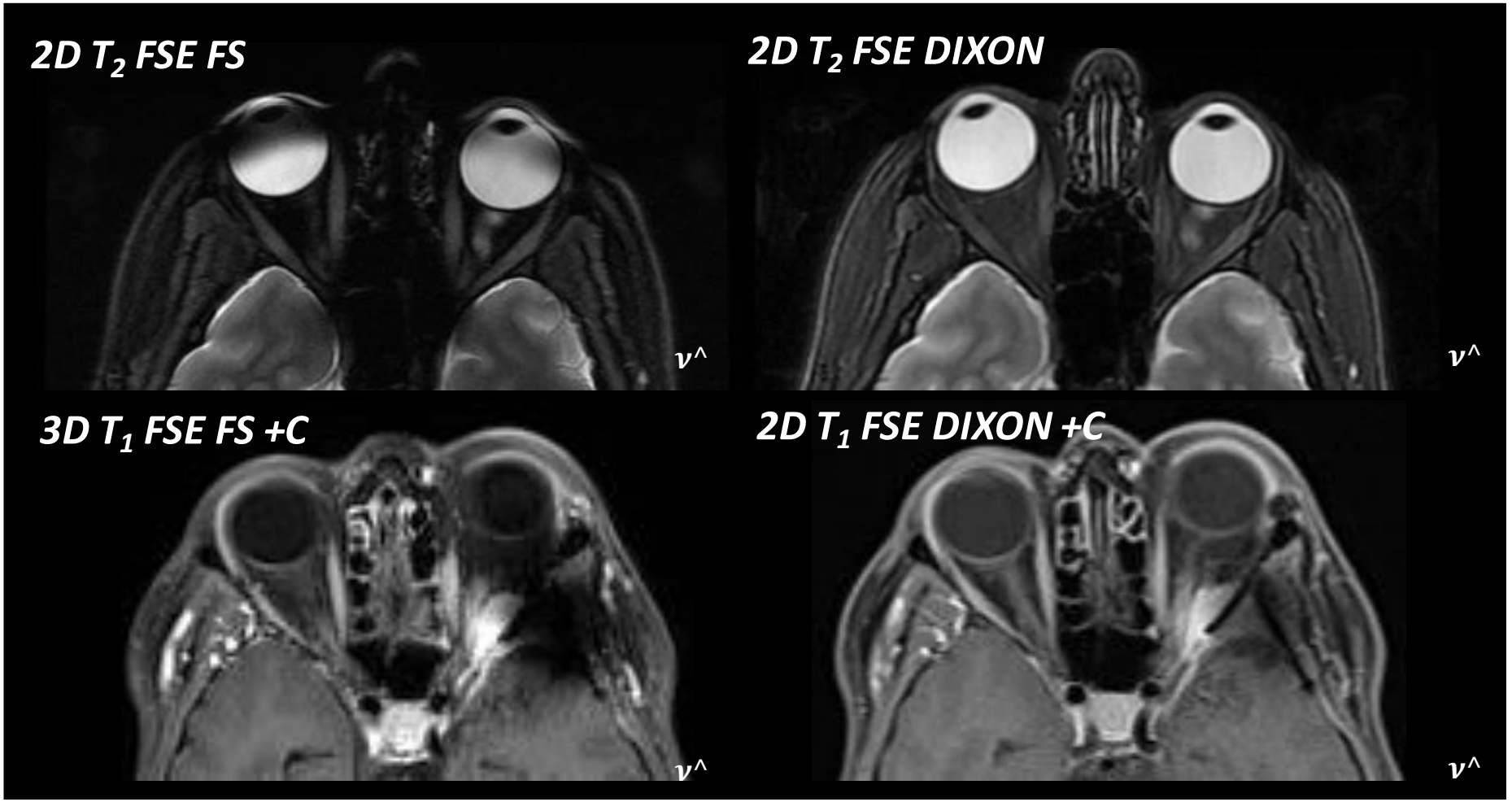

B_0 inhomogeneities, e.g. air/tissue interfaces or metal implants

Hull University Teaching Hospitals NHS Trust

Distortions of the static magnetic field (B_0) due to metallic implants result in:

- Intra-voxel dephasing
  - Signal voids are visible as black areas in the image
- Changes in tissue contrast
  - Failure of fat suppression
- In-plane distortion
  - Shift of image pixels in the frequency encoding direction
- Through-plane distortion
  - The local field offset leads to curved and frayed slices instead of the expected flat

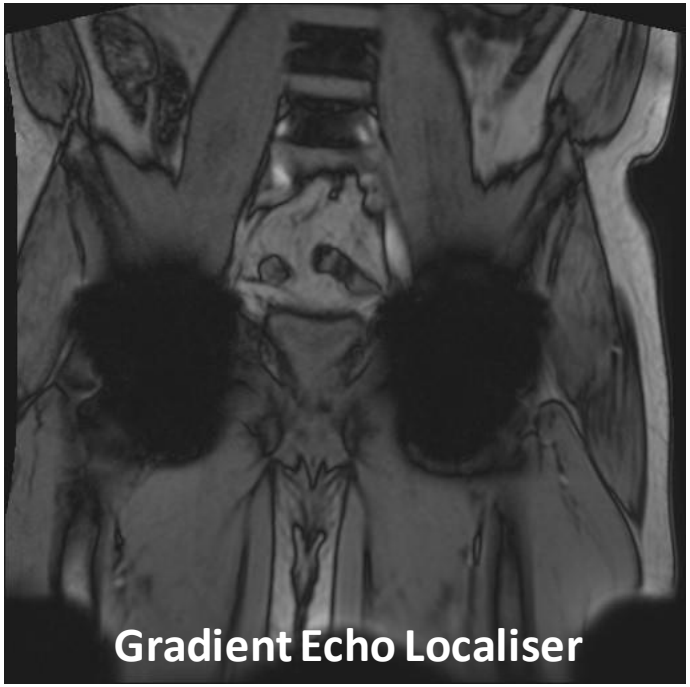

http://clinical-mri.com/wp-content/uploads/new_technologies/WARP_Nittka_MAGNETOM_Flash_RSNA2012.pdf

B_0 inhomogeneities, e.g. air/tissue interfaces or metal implants

The following terms are all techniques to reduce artefacts due to the presence of metal in MR studies:

- WARP (collection of tools)
  - High bandwidth sequence
  - TSE, STIR-TSE
  - Low artefact RF pulses

- **V**iew **A**ngle **T**ilting (VAT)
  - In-plane artefact reduction

- **S**lice **E**ncoding for **M**etal **A**rtefact **C**orrection (SEMAC)
  - In- and through-plane distortion correction

- **M**ulti**A**cquisition with **V**ariable **R**esonance **I**mage **C**ombination (MAVRIC)
  - MAVRIC SL = **MAVRIC S**e**L**ective
  - In- and through-plane distortion correction



A lower field strength is always better

https://www.ncbi.nlm.nih.gov/pmc/articles/PMC4321802/

B_0 inhomogeneities, e.g. air/tissue interfaces or metal implants



B_0 inhomogeneities, e.g. air/tissue interfaces or metal implants

Metal Artefact Techniques

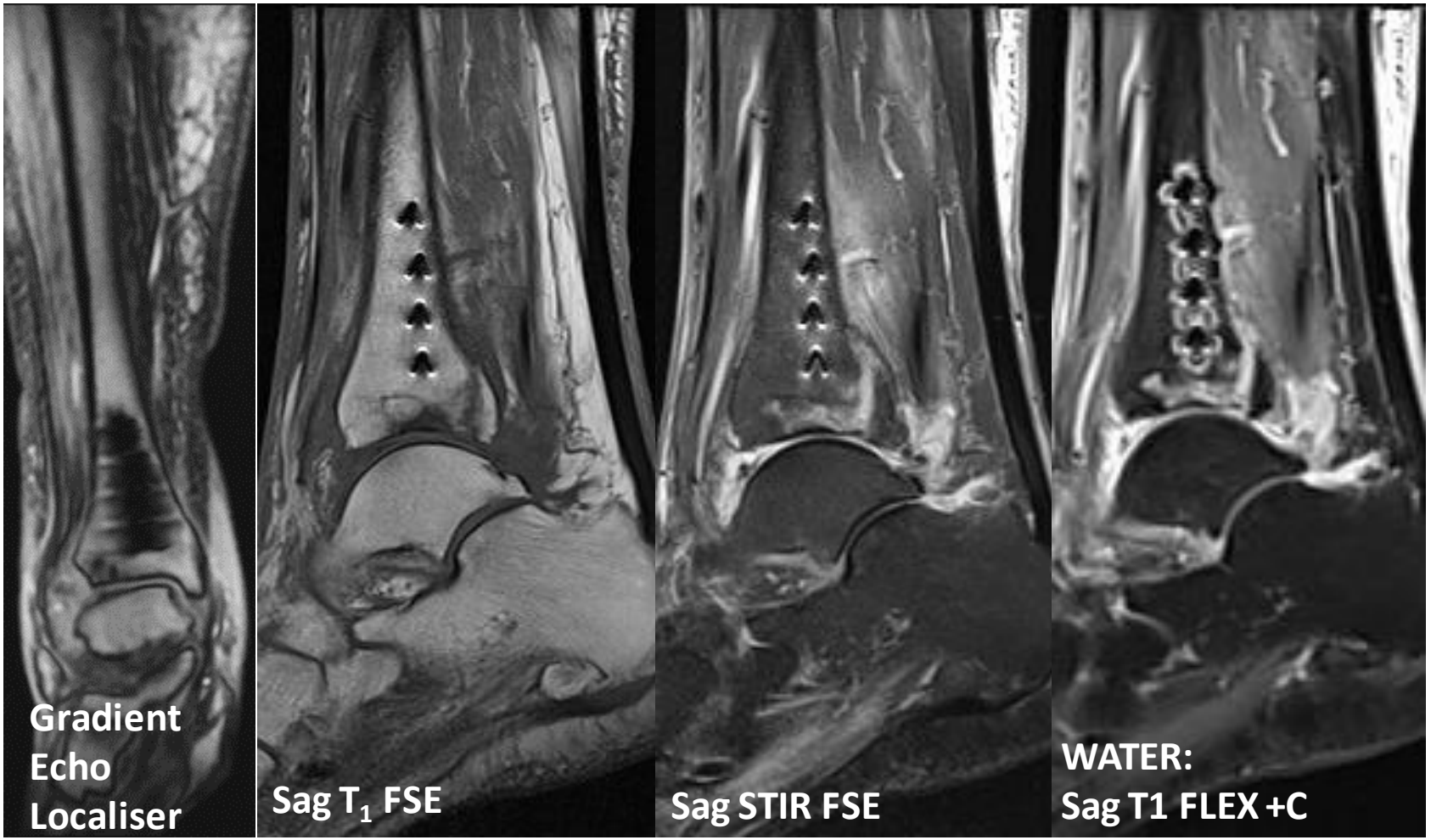

B_0 inhomogeneities, e.g. air/tissue interfaces or metal implants

SEMAC Examples

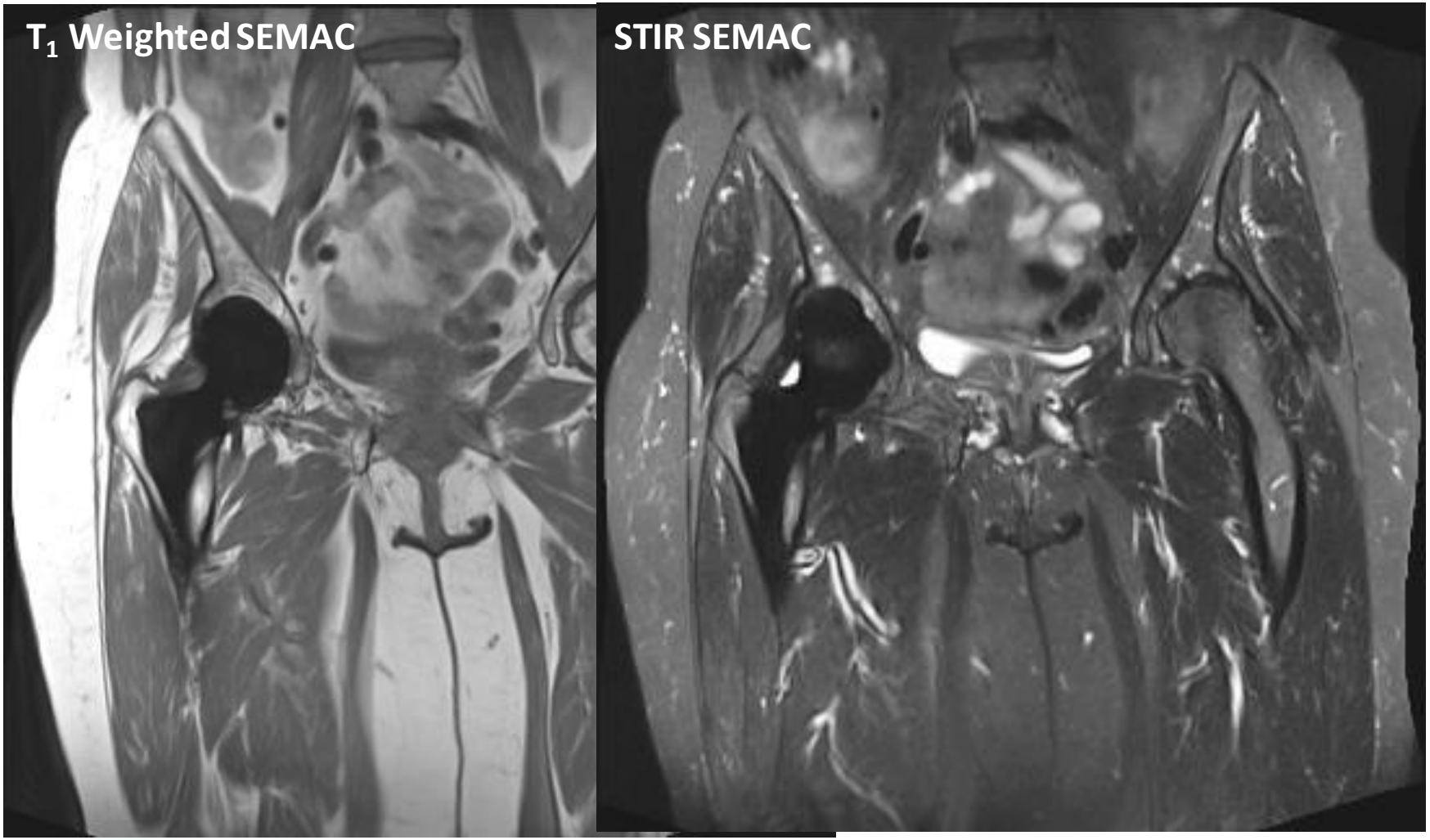

B_0 inhomogeneities, e.g. air/tissue interfaces or metal implants

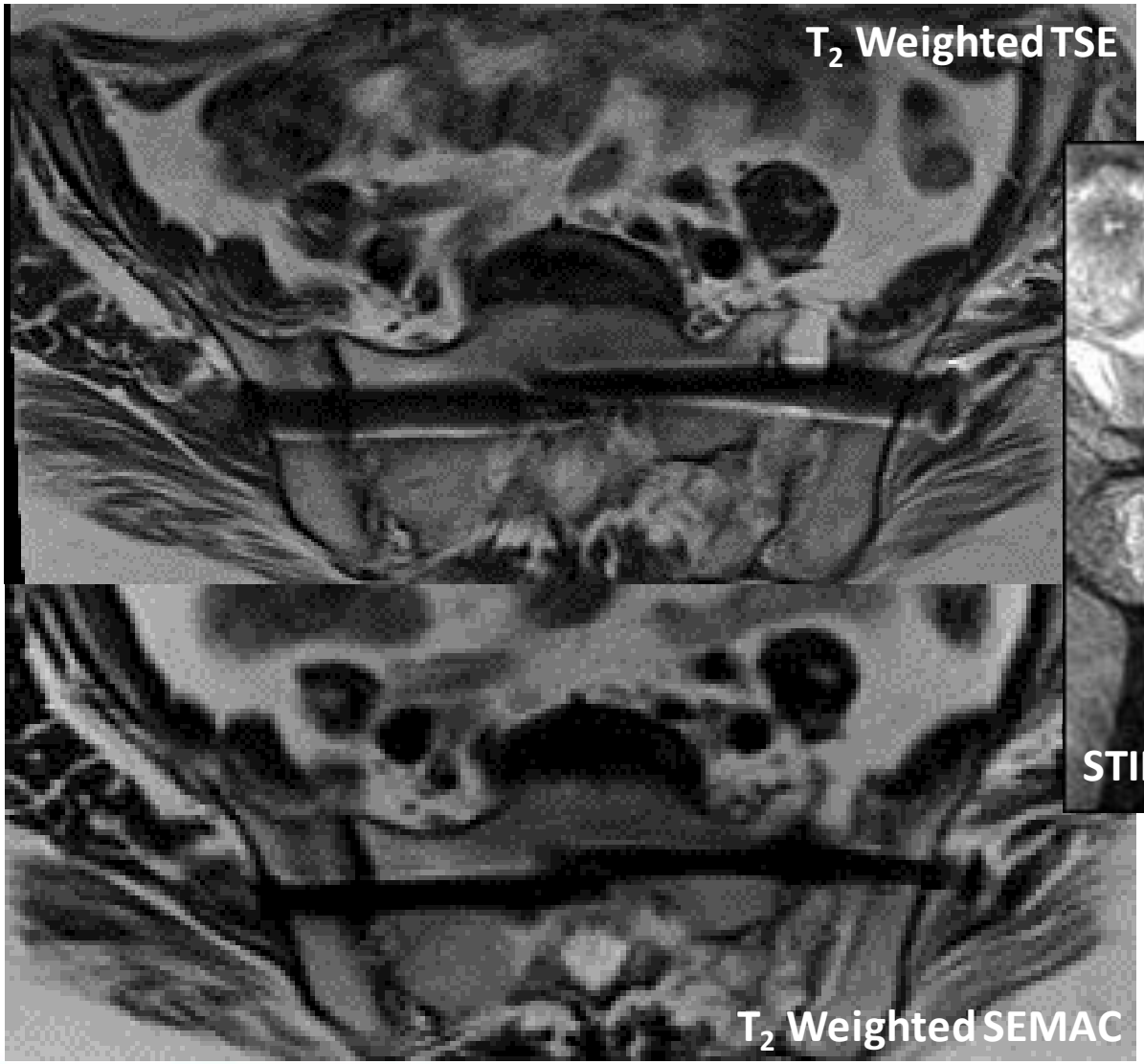



NHS
Hull University Teaching Hospitals
NHS Trust

Remarkable people.
Extraordinary place.

B_0 inhomogeneities, e.g. air/tissue interfaces or metal implants

NHS
Hull University Hospitals NHS Trust

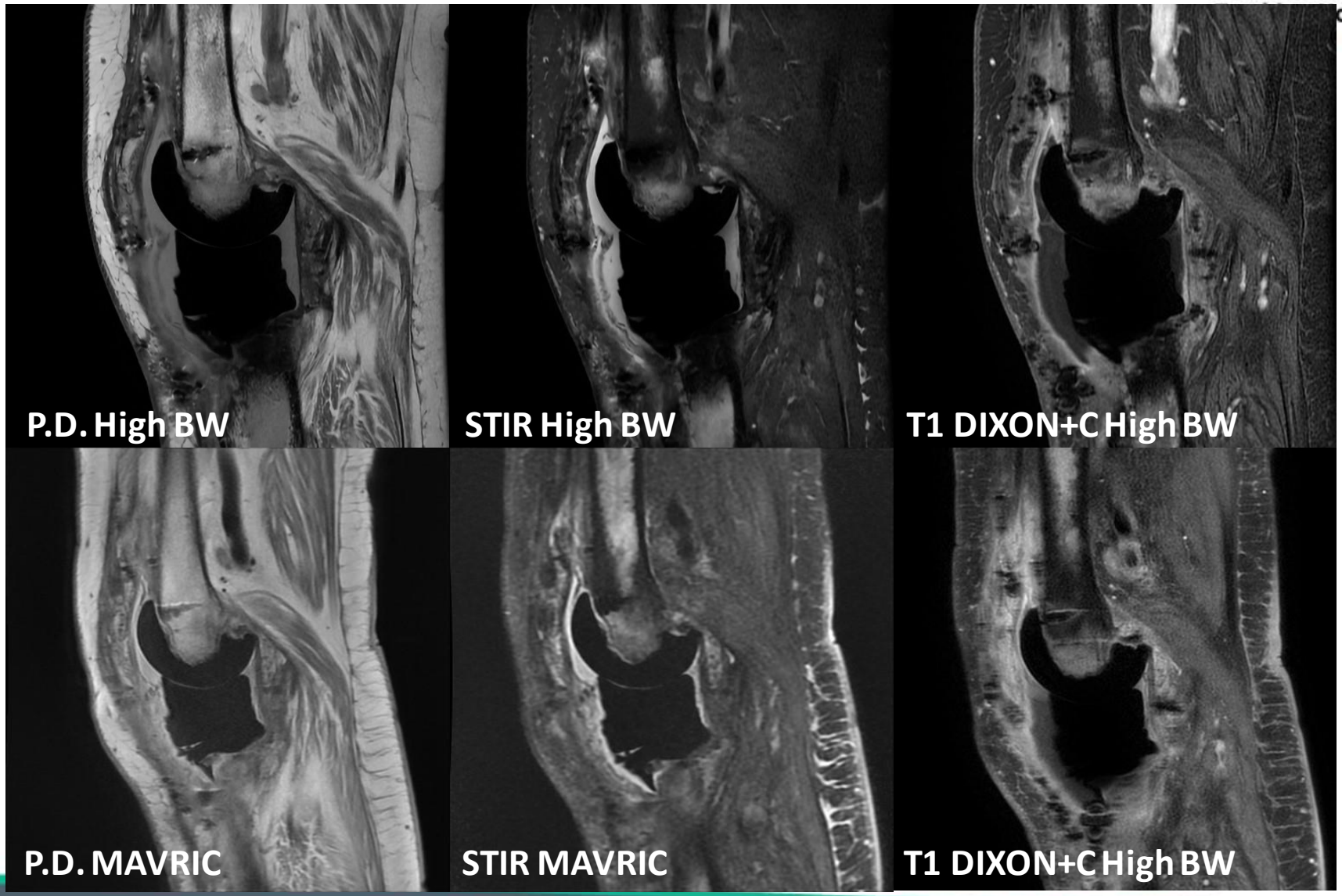

B_0 inhomogeneities, e.g. air/tissue interfaces or metal implants

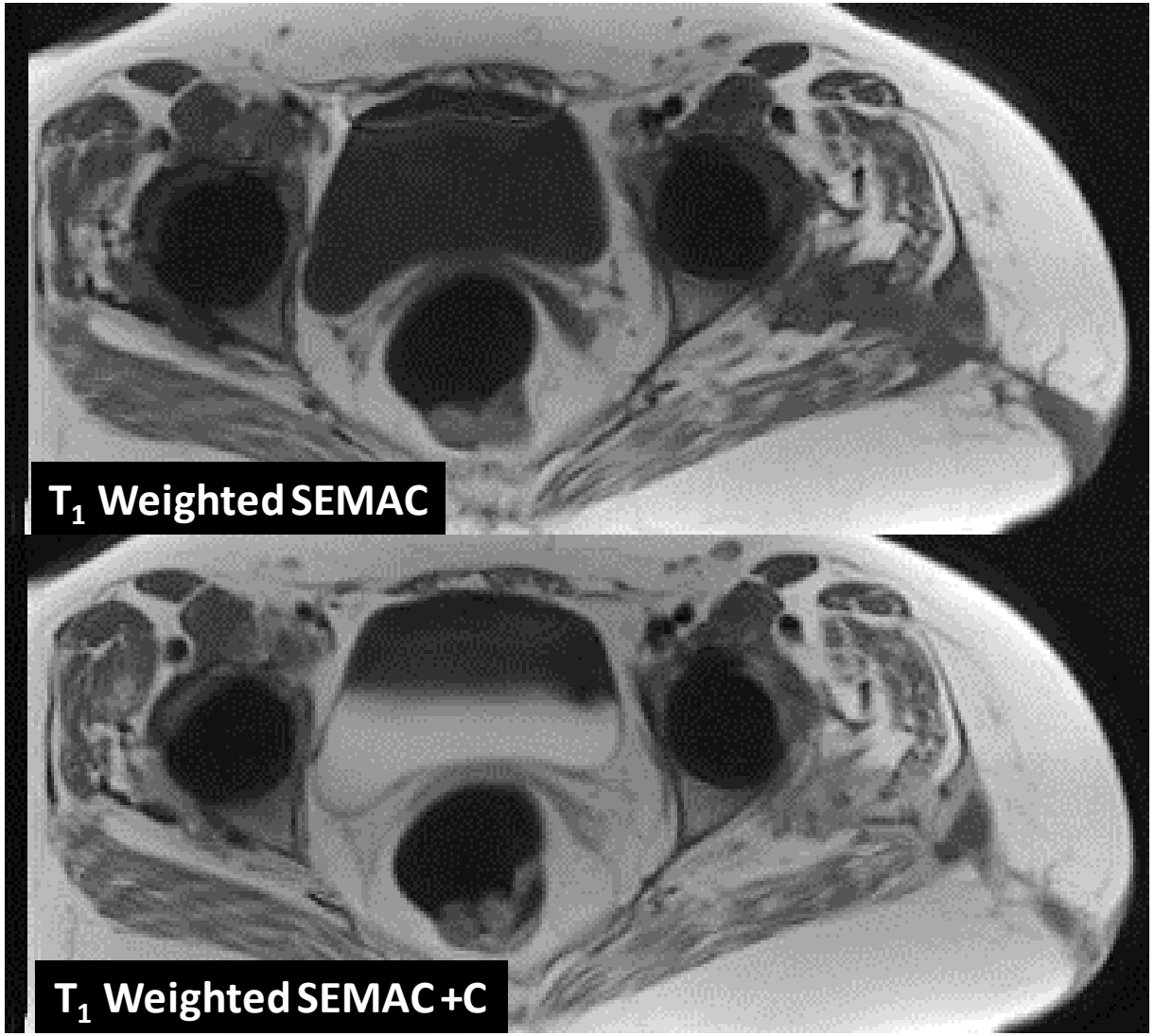

- Limited **MAVRIC SL** and **SEMAC** image contrasts

- T_1
- T_2
- P.D.
- STIR

- No CHESS fat-sat!

B_0 inhomogeneities, e.g. air/tissue interfaces or metal implants

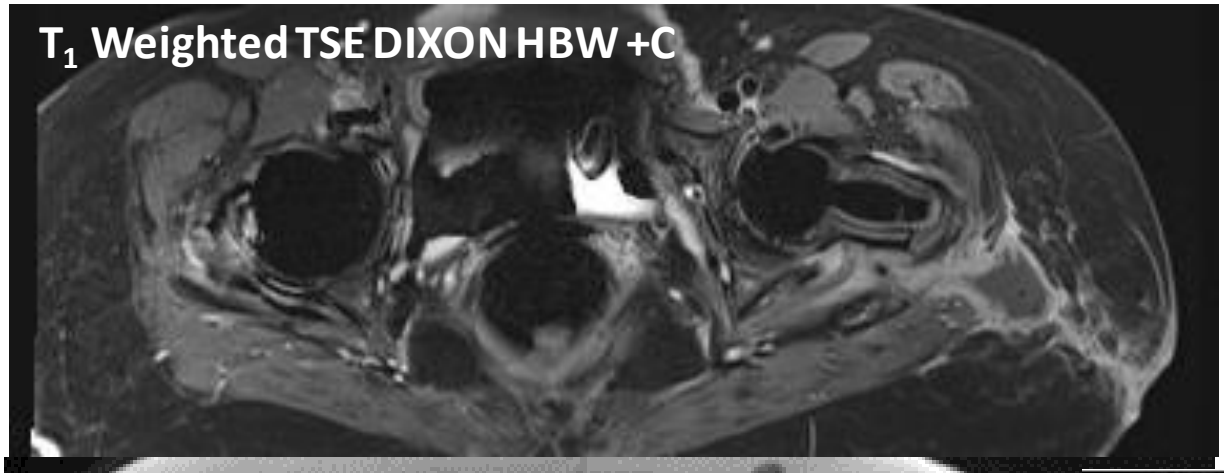

- Alternatives to CHESS fat-sat subtraction or high-bandwidth DIXON

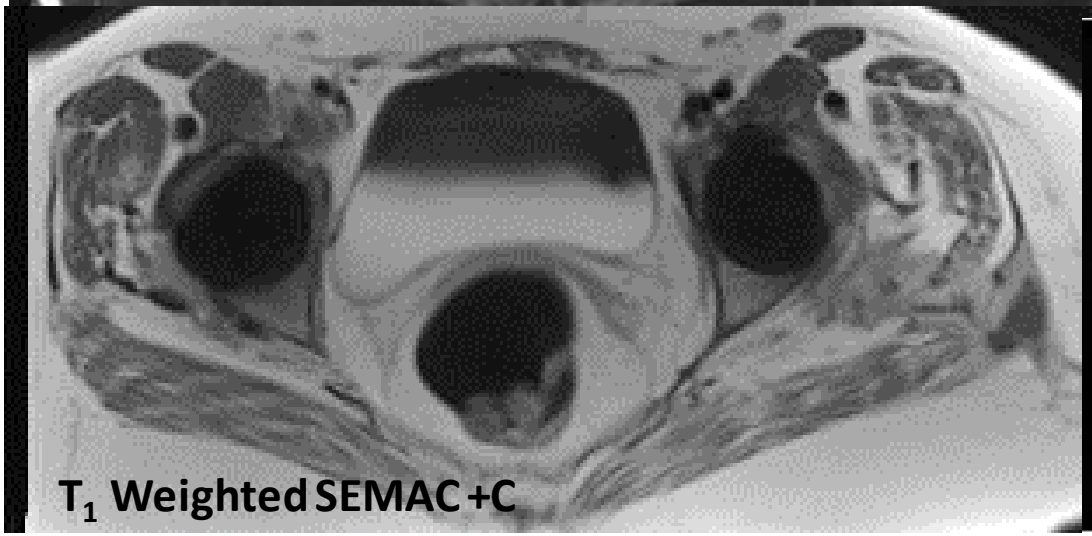



https://www.ncbi.nlm.nih.gov/pmc/articles/PMC4409347/

B_0 inhomogeneities, e.g. air/tissue interfaces or metal implants

NHS
Hull University Teaching Hospitals
NHS Trust

CHESS (Chemical Shift Selective) aka 'fat sat'

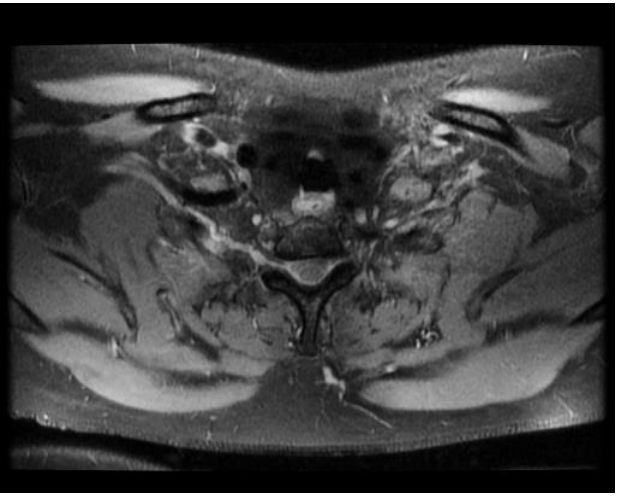

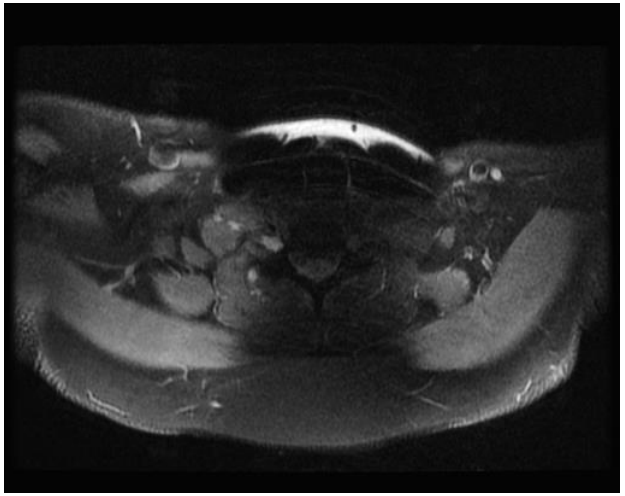

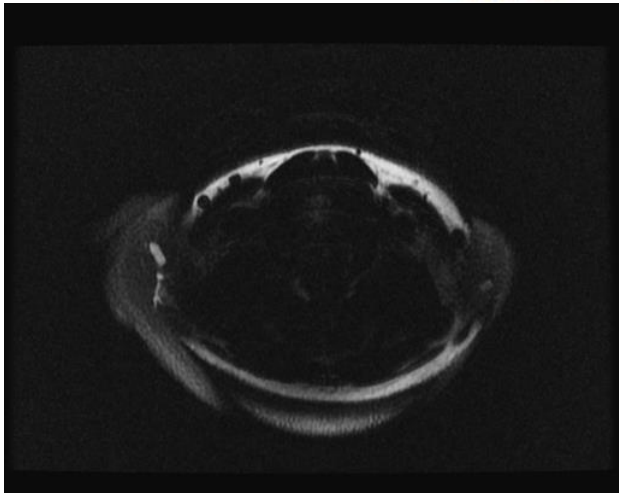

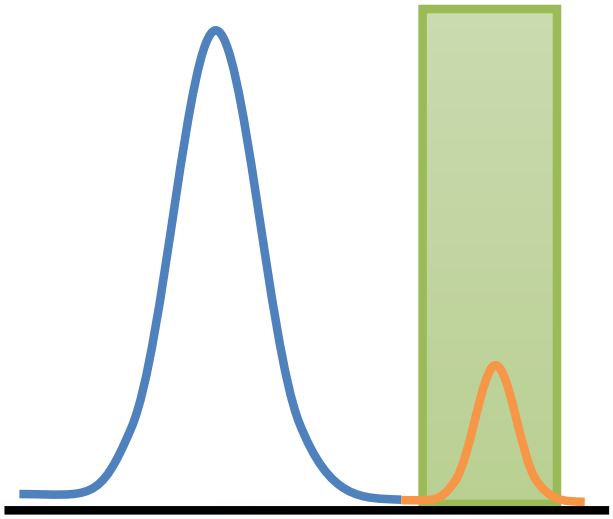

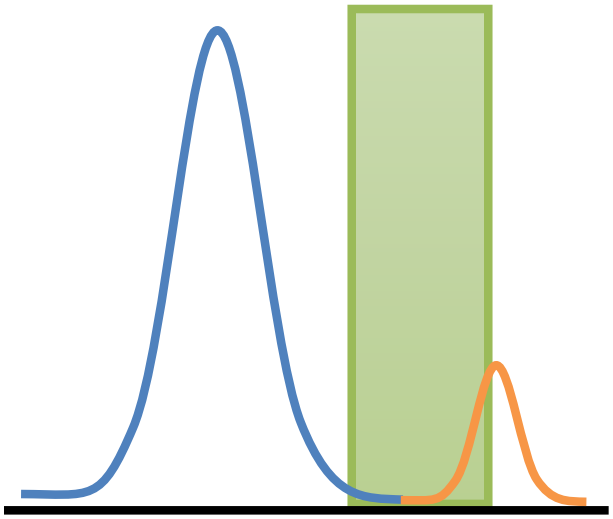

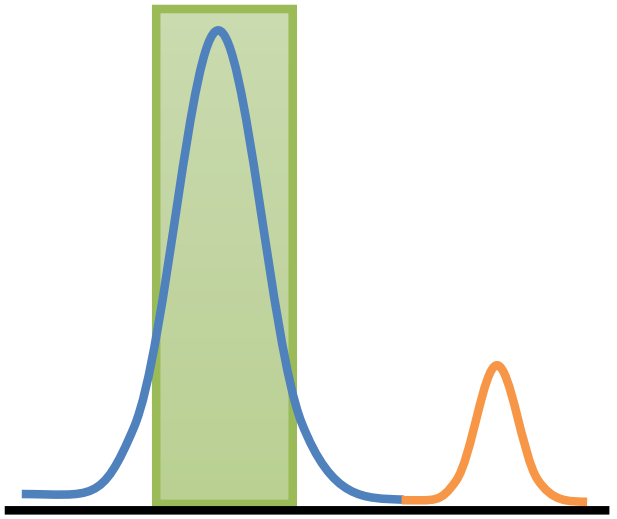

B_0 inhomogeneities, e.g. air/tissue interfaces or metal implants

CHESS (Chemical Shift Selective) aka 'fat sat'

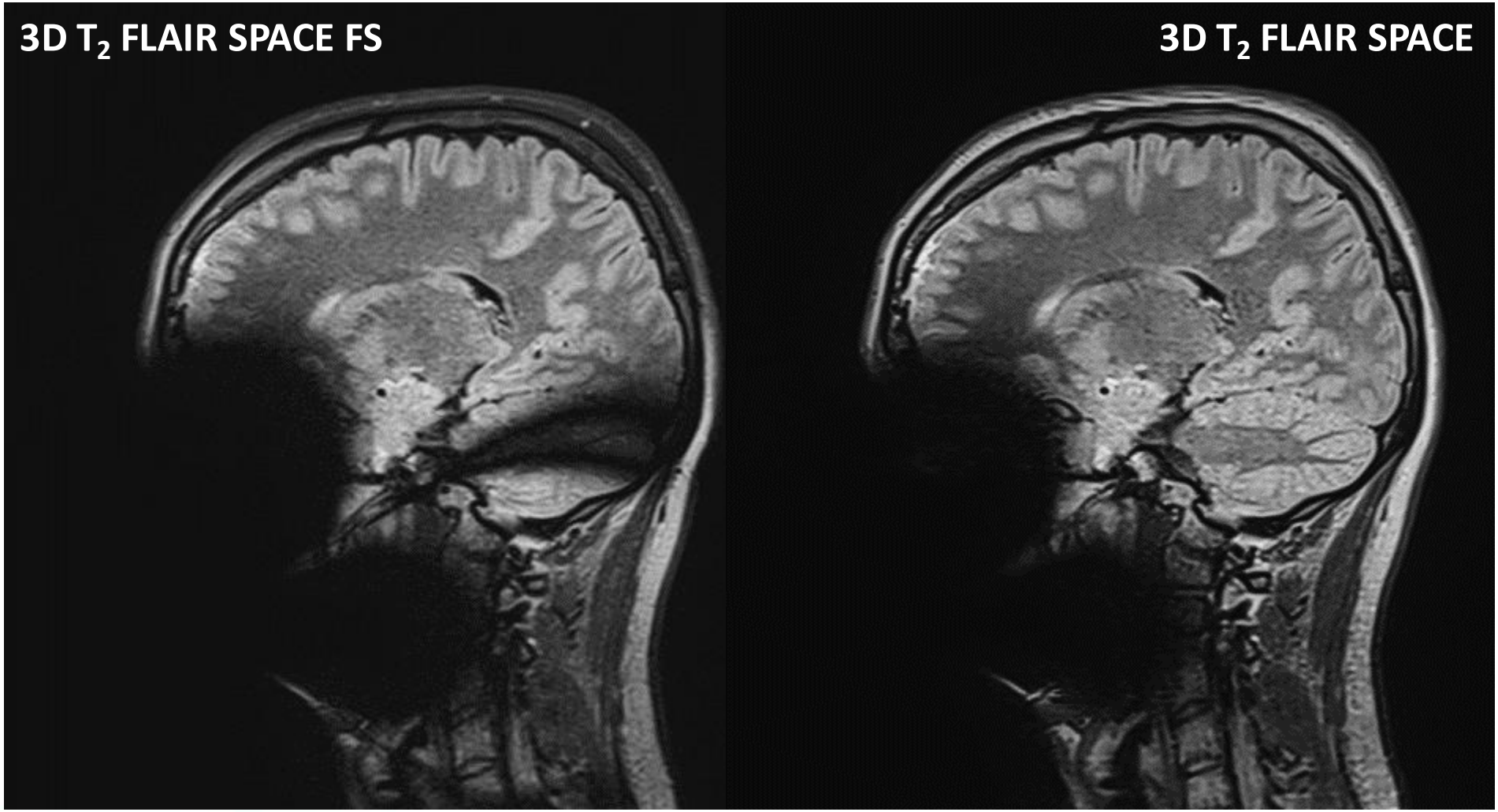

B_0 inhomogeneities, e.g. air/tissue interfaces or metal implants

CHESS (Chemical Shift Selective) aka 'fat sat'

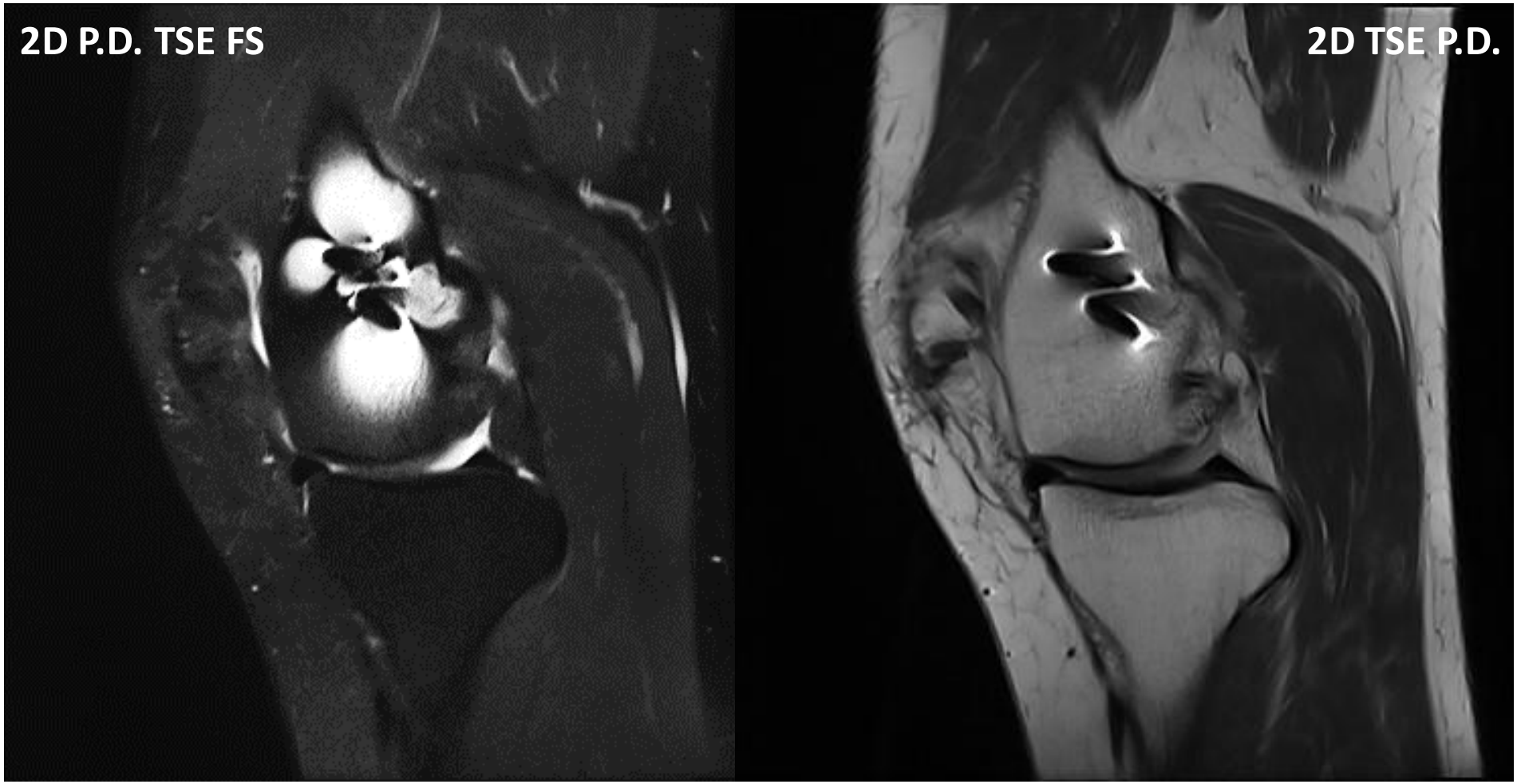

3.0T - B_1 inhomogeneities

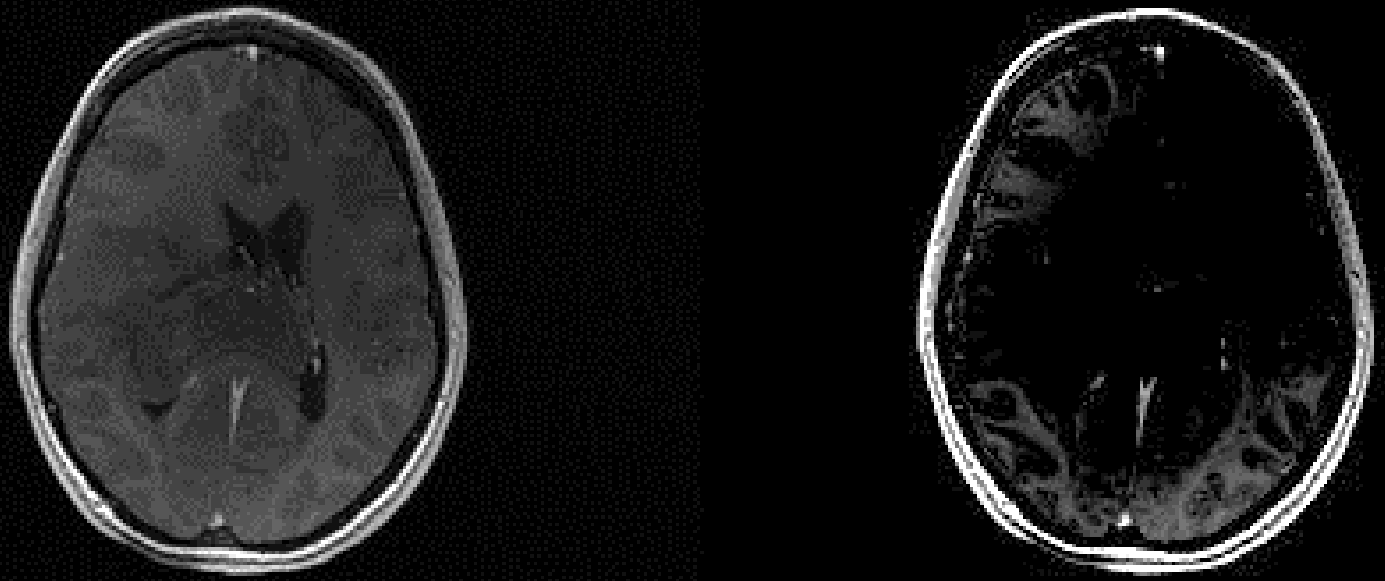

B_1 inhomogeneities in the local transmitted magnetic field degrade image quality and cause spatially varying errors in the transmitted flip angle (FA). Flip angle errors can lead to significant inaccuracies for quantitative T_1 mapping applications, including inversion recovery and variable flip angle acquisitions.

Parallel (Multi-) Transmit RF

Multi-transmit or parallel transmission technology is a recent development in MRI only commercially available at 3T and above

The basic idea is instead of the entire RF coil transmitting a single B_1 field, divide the coil into separate independently powered and controlled elements that each produce their own B_1 subfields.

The sum of these subfields constitutes the net B_1 field experienced by the tissue. In this manner it is possible to more carefully control the homogeneity of RF excitation

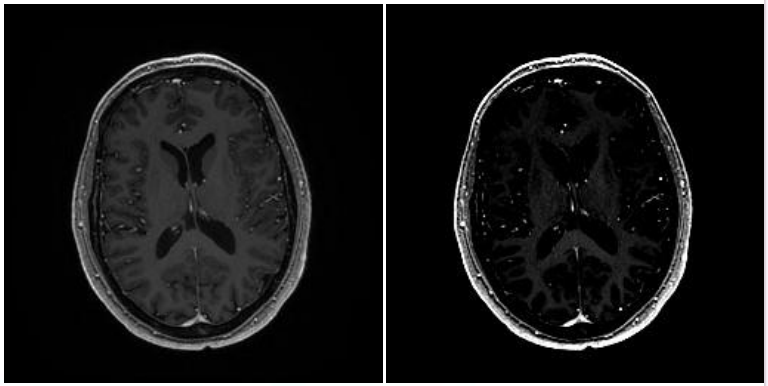

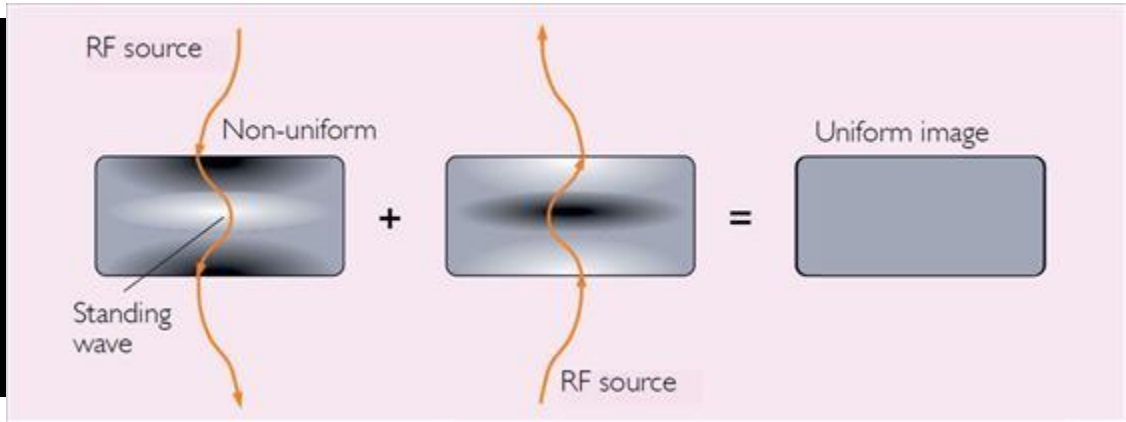

https://mriquestions.com/multi-transmit-rf.html

Radiofrequency magnetic field (B_1)

- RF pulses in MRI refer to electromagnet waves with orthogonal eclectic and magnetic fields
  - The B_1 pulse is orientated 90° to the B_0 z-direction

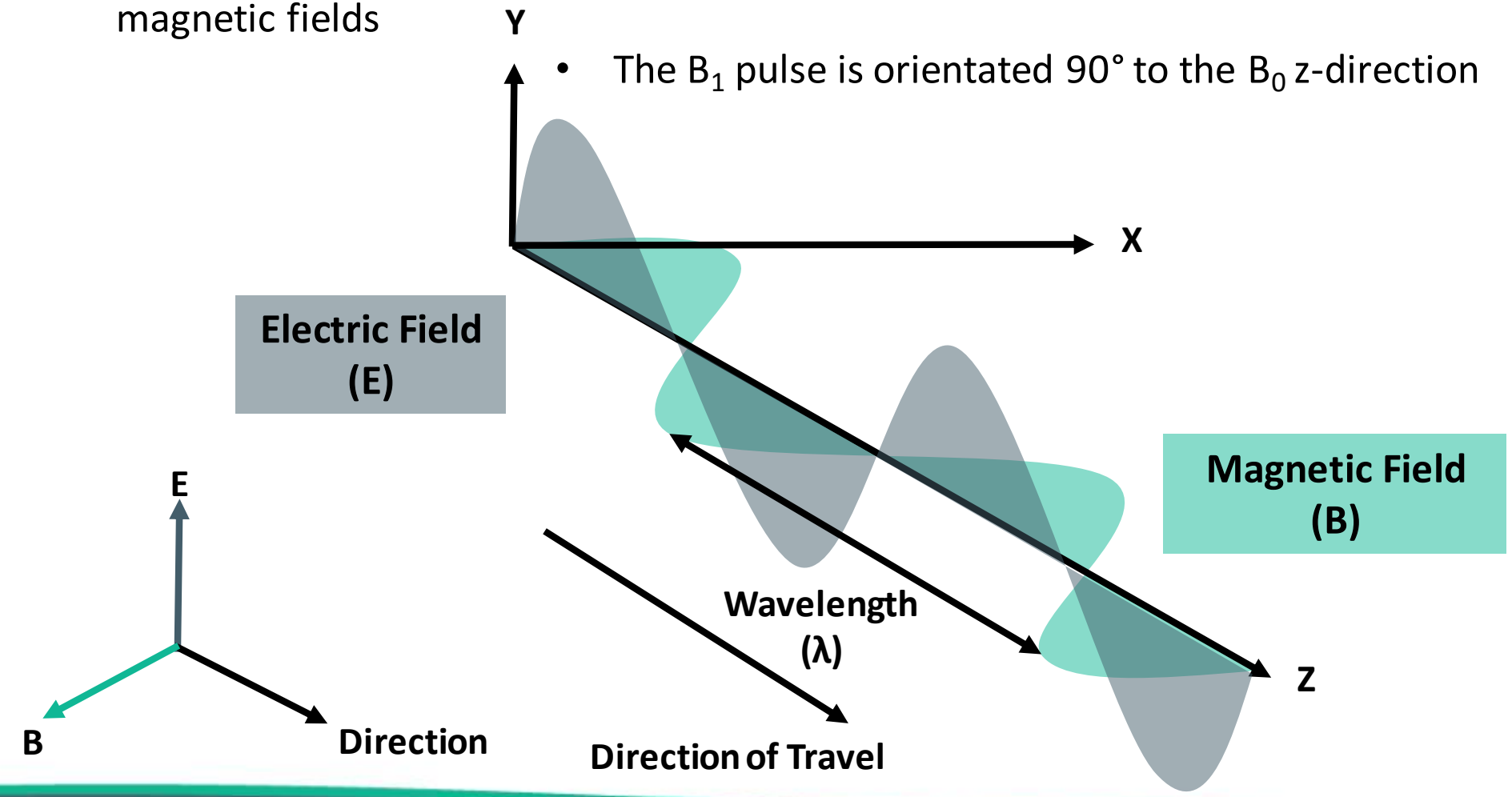

Radiofrequency magnetic field (B_1)

- Wavelength can be expressed as:

$$\lambda = c/f$$

- Where $c = 3x10^8$ m/s, $f = \gamma B_0$,

- This changes in a magnetic field to:

$$\lambda = c/(f\sqrt{\varepsilon_r})$$

- Where ε_r = relative permittivity of water/dielectric constant

- This means the wavelength of B_1 changes from 4.7m in air to 0.51m in tissue at 1.5T.

- At higher fields, the wavelength shortens in tissue proportionally

- The **wavelength of B_1 in tissue is 51cm @ 1.5T and 26cm @ 3.0T**

Dielectric Artefact

- At 3T, it has been proposed that the shorter RF wavelength causes standing electric waves to develop which interfere with each other resulting in constructive and destructive interference

- This spatially varying transmit B-field produces corresponding variations in the flip angle within the body and subsequent intensity variations across the image

- Such brightening and darkening artefacts have sometimes been incorrectly attributed to dielectric resonance, which is strictly a function of frequency rather than position.

Dielectric Artefact

- Abdominal MRI often suffers from regions of central darkening with body habitus often influencing the degree of artefact.

- With patient abdominal diameters that exceed the RF wavelength (e.g. patients with cirrhosis and ascites or pregnant patients), constructive and destructive interference patterns may emerge.

- Obese patients do not necessarily produce worse shading because:
  - a) the lower dielectric constant of fat compared to muscle causes the RF wavelength to be 2–3 times longer in fat, and
  - b) they have a more circular cross- section. Whereas artefacts can be substantially worse in thin patients because of less fat and a more elliptical cross- section.

- Patients with ascites are also problematic due to the high relative permittivity of the fluid as well as the high conductivity if it also has a high salt concentration

B_1 inhomogeneities especially at 3T

Dielectric Artefact

Hull University Teaching Hospitals NHS Trust

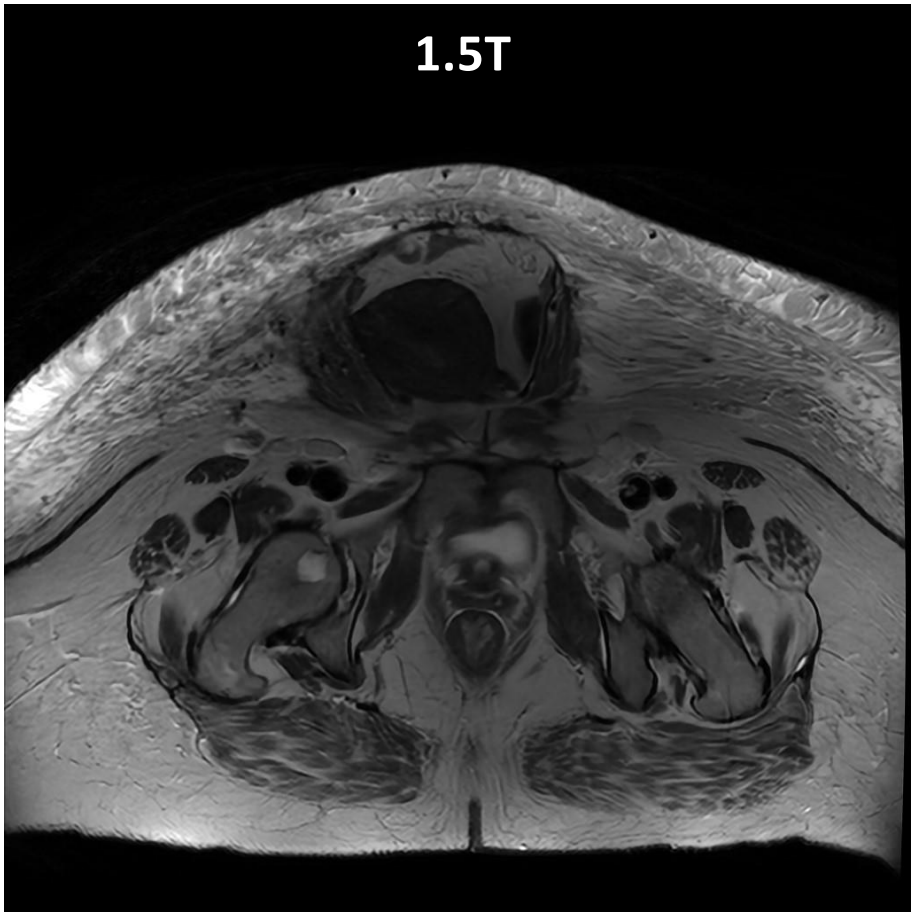

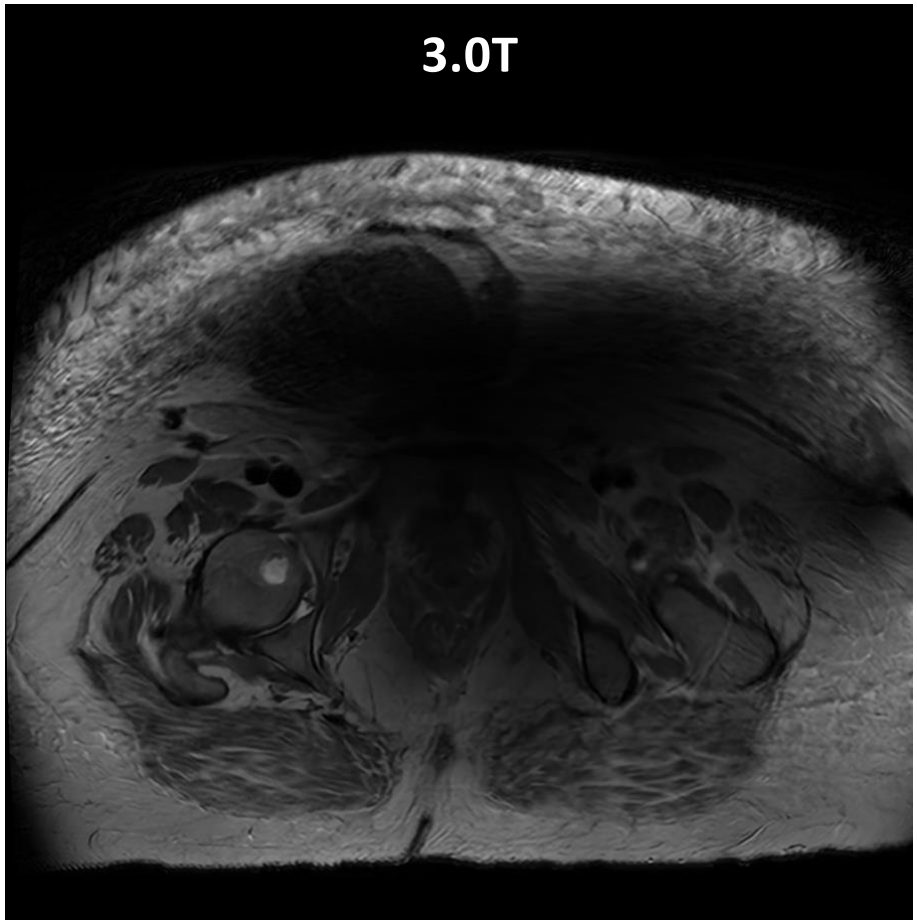

Dielectric Artefact

- The best way to reduce these artefacts are to switch to lower field systems where RF wavelength is longer

- Or in extreme cases drain ascites before imaging a patient to decrease the chance of the artefact occurring

Radiofrequency/ 'Zipper' Artefact

- MR signal is very weak, thus RF receiver is very sensitive
- Causes a discrete zip-like line in PE direction
- Caused by <u>continuous</u> RF interference
- Usually a breakdown in RF integrity of system
  - Break in RF Cage
  - Faulty patient monitoring
- LED Lightbulbs can interfere with MRI
- Artefact reduced by changing centre frequency or reducing bandwidth

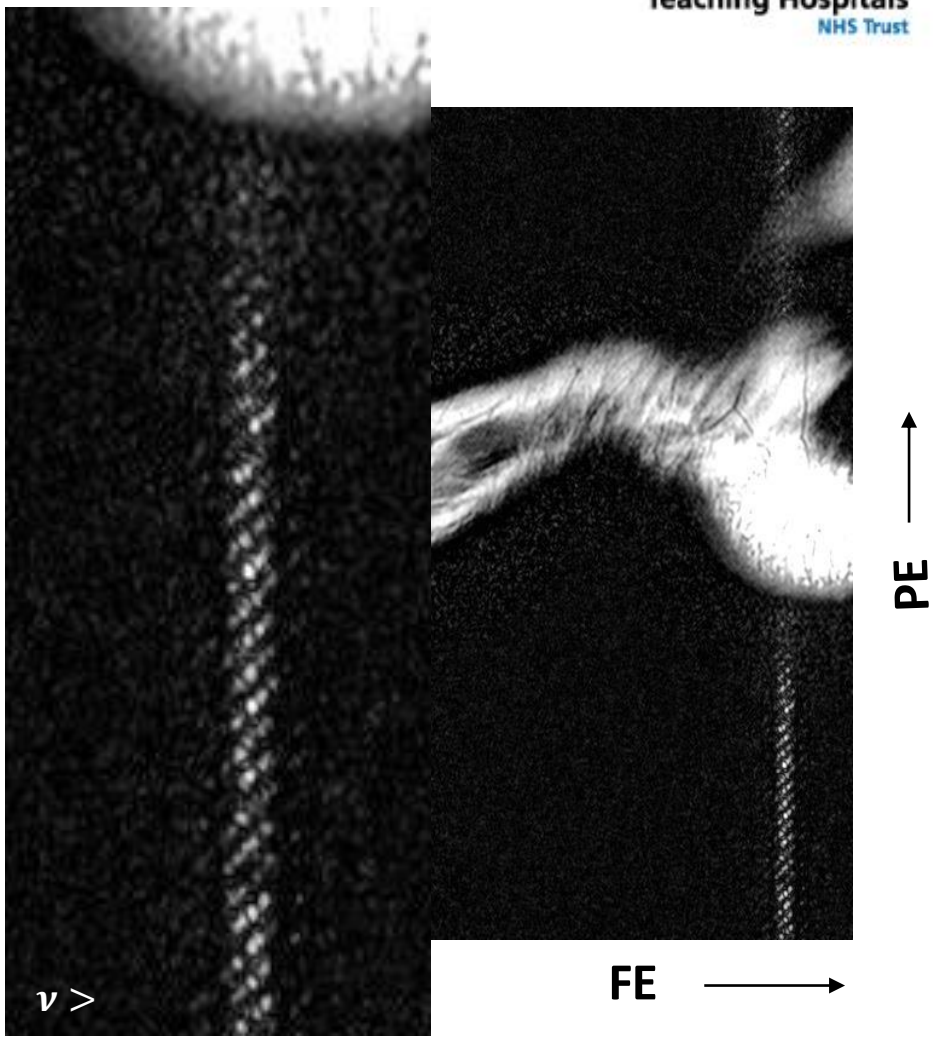

RF interference: instantaneous (RF spikes); continuous RF interface

RF or ‘Zipper’ Artefact

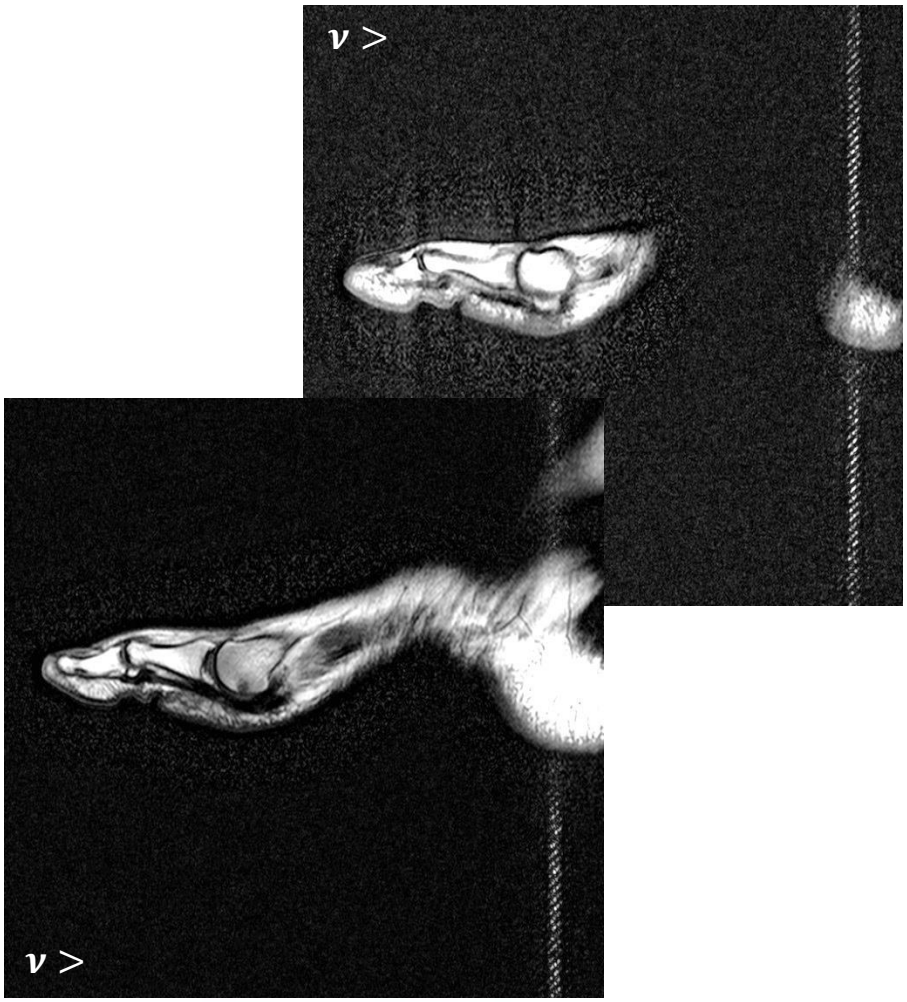

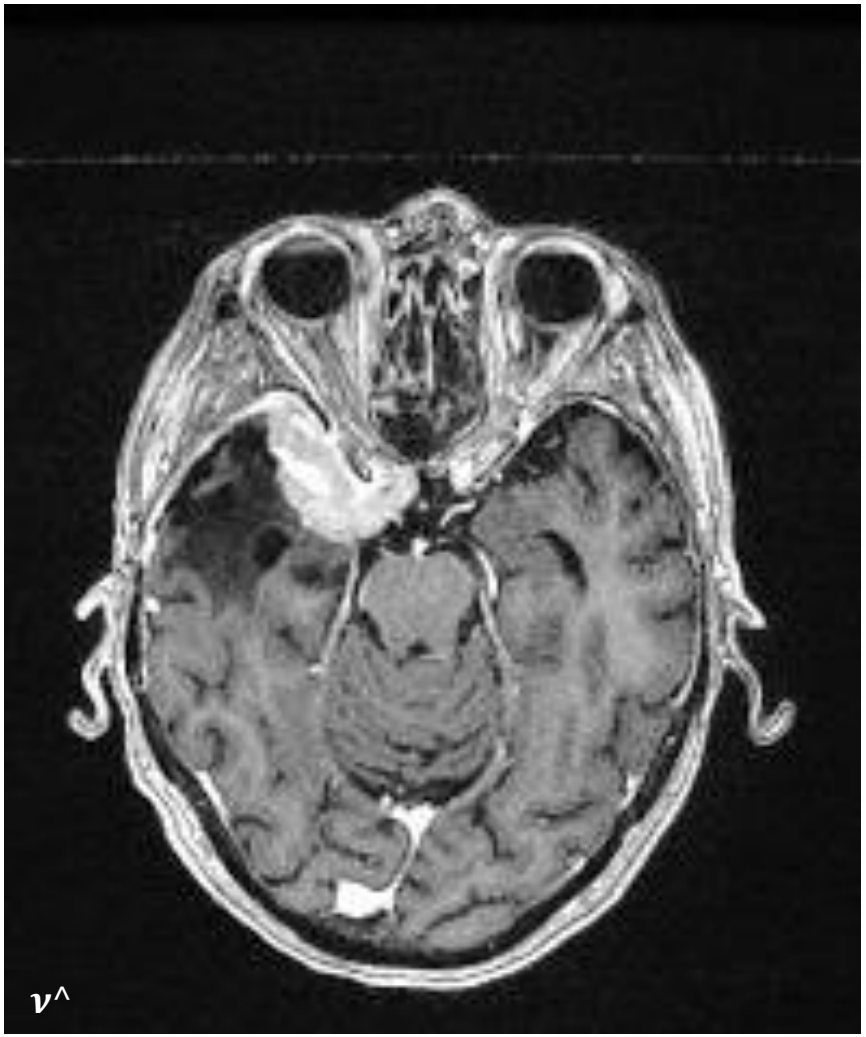

RF interference: instantaneous (RF spikes); continuous RF interface

RF or ‘Zipper’ Artefact



RF interference: instantaneous (RF spikes); continuous RF interface

Hull University Teaching Hospitals NHS Trust

RF or 'Zipper' Artefact

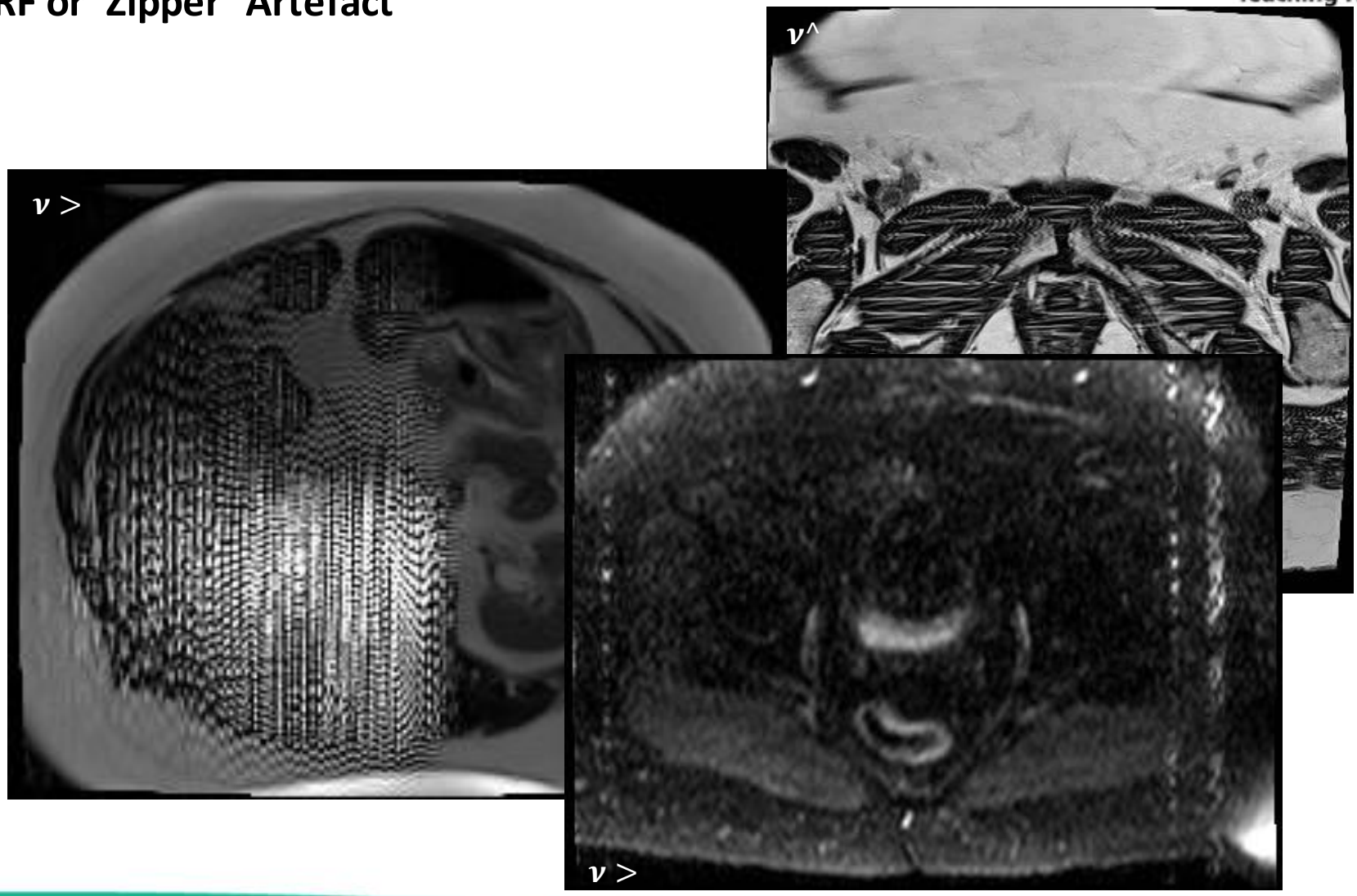

Hull University Teaching Hospitals NHS Trust

PROPELLER/BLADE – RF Interference

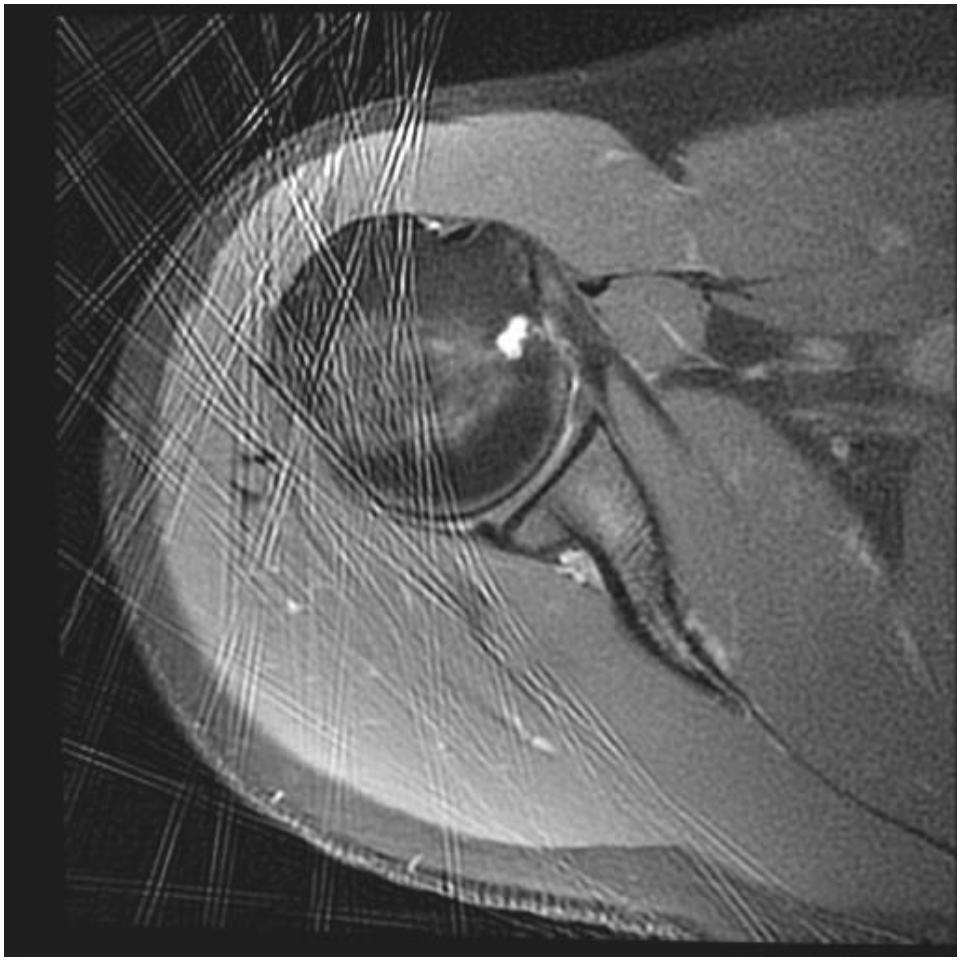

Herringbone artefact (Instantaneous RF Interference)

- Also known as “corduroy” artefact
- Series of high and low intensity stripes across the image
- Often appears on just one or two images in a multi-slice dataset
- Caused by spike noise in the raw data, whose FFT is then convolved with all the image information (instantaneous RF interference)
- A single image with this artefact could be bad luck (static electricity discharge), but issues with several different scans is a symptom of breakdown of either the RF coils or the decoupling system

Herringbone artefact

- Due to short RF spike whilst filling k-space during read-out
- RF spikes lead to points in k-space having higher intensities than the centre of k-space
- The spatial frequency of the pattern depends on which points of k-space were affected
- Remember every point in k-space goes to every point in image space!

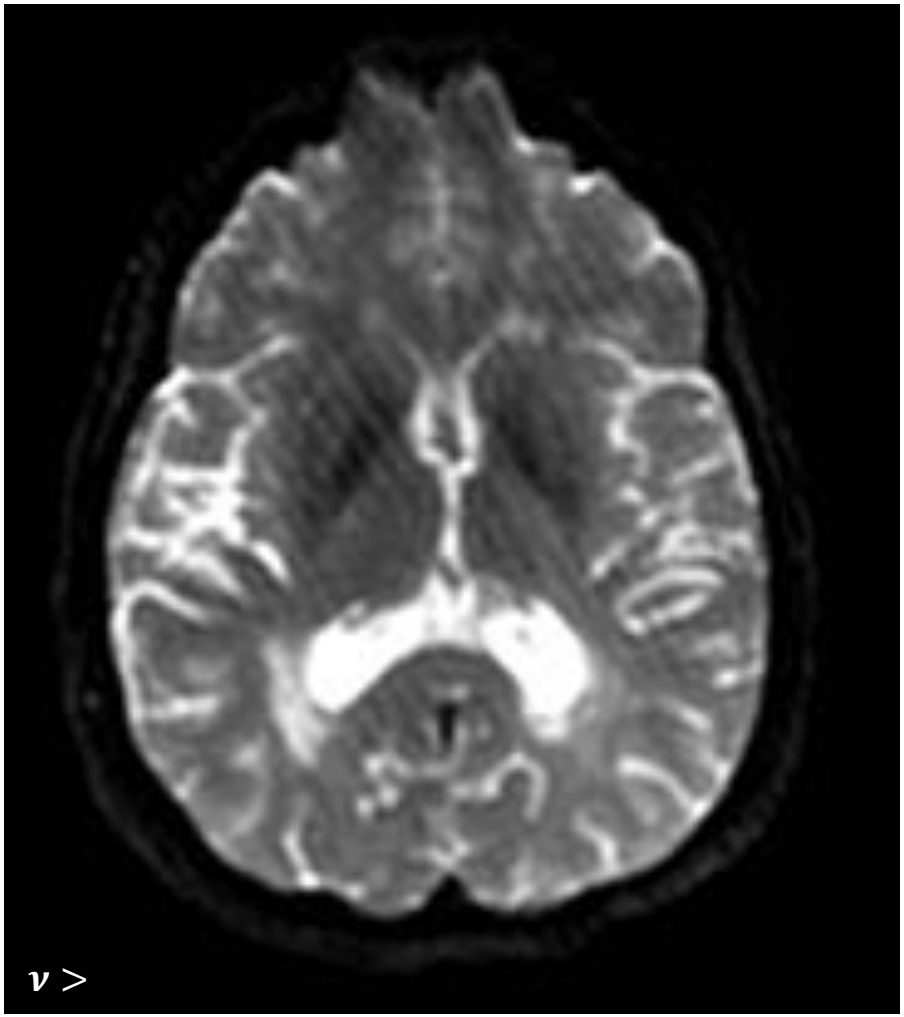

Phase Wrap

- Also know as: wrapping / aliasing / ‘foldover’ / ‘wrap around’
- Occurs when signal is detected from outside of the FOV in the **phase encoding direction**
- Regions outside FOV excited with RF are indistinguishable from those inside FOV
- These regions manifest within the image on the opposite side – “wrapping around”

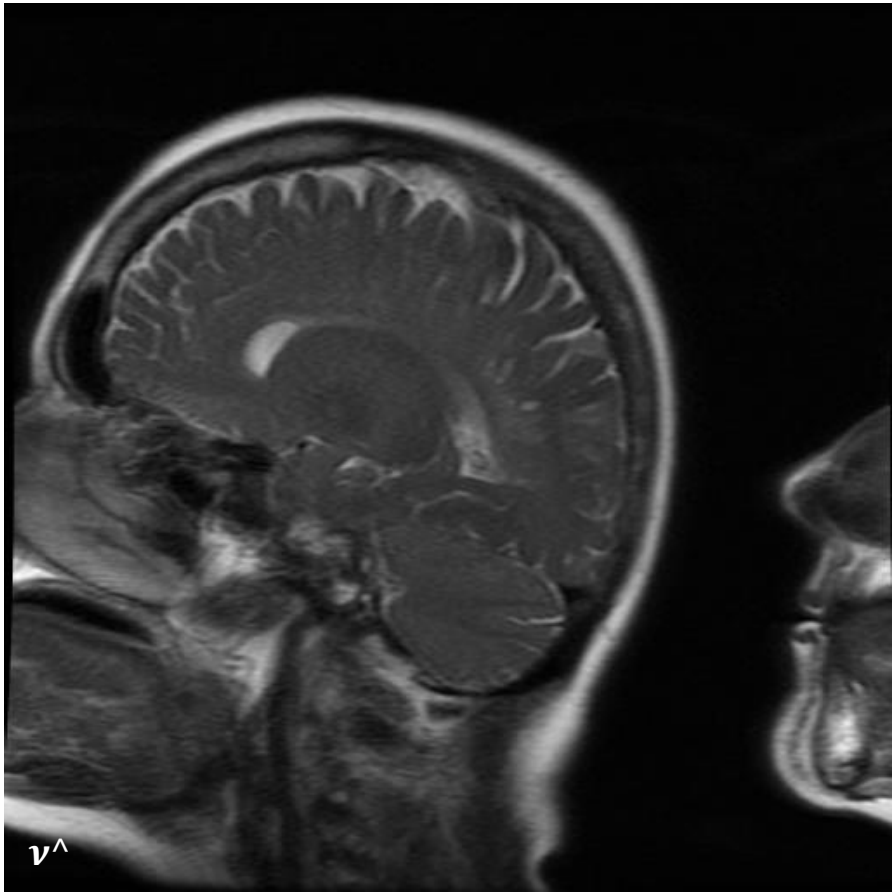

Phase Wrap

- For 3D sequences, phase wrap can occur in 2 directions

- In-plane and through-plane



Phase Wrap

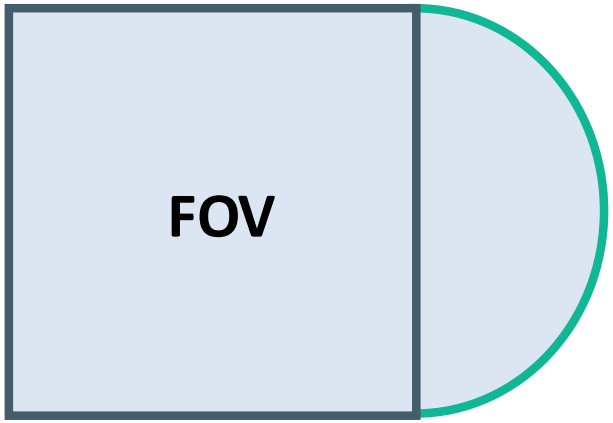

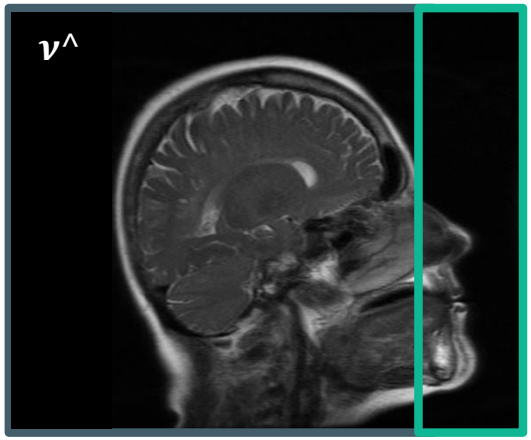



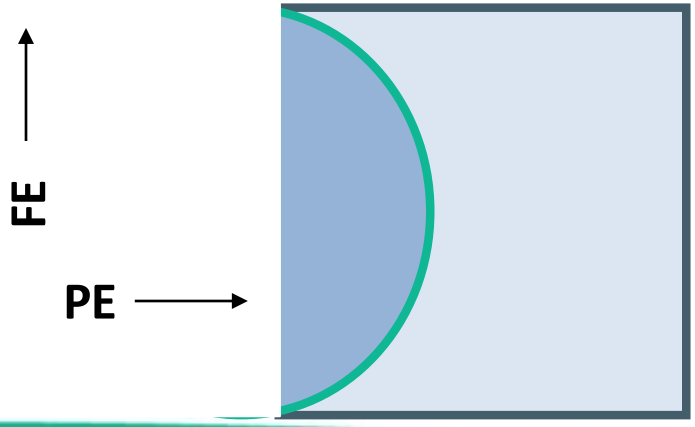

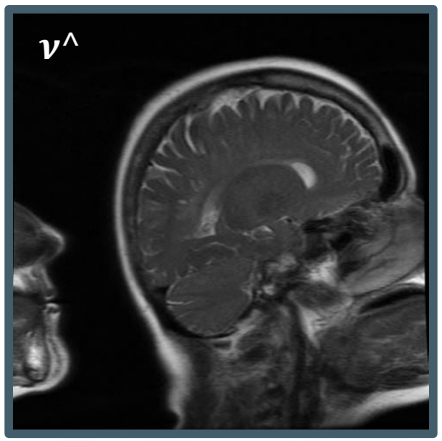

Phase-wrap: Elimination

- Increase the size of the FOV
  - Reduces spatial resolution (unless matrix is adjusted)

- Saturation of pulses from outside the FOV (not 100% effective)

- Selective excitation (3D)

- Use of 'No Phase-Wrap' (NPW) / Phase Oversampling
  - Doubles FOV in PE direction
  - Doubles no. of PE steps (to maintain spatial resolution, doubles scan time)
  - Halving no. of averages (same scan time, but lower SNR)

Gibbs Artefact (ringing or truncation artefact)

- Appears as parallel lines adjacent to high contrast interfaces (cord/CSF).
- Inability to approximate a step like change in signal intensity
- Consequence of using FT to reconstruct signals
  - Signal represented by infinite sum of sine waves (Fourier theory)
  - Series is truncated due to finite sampling
  - FT produced with ripples→ parallel bands

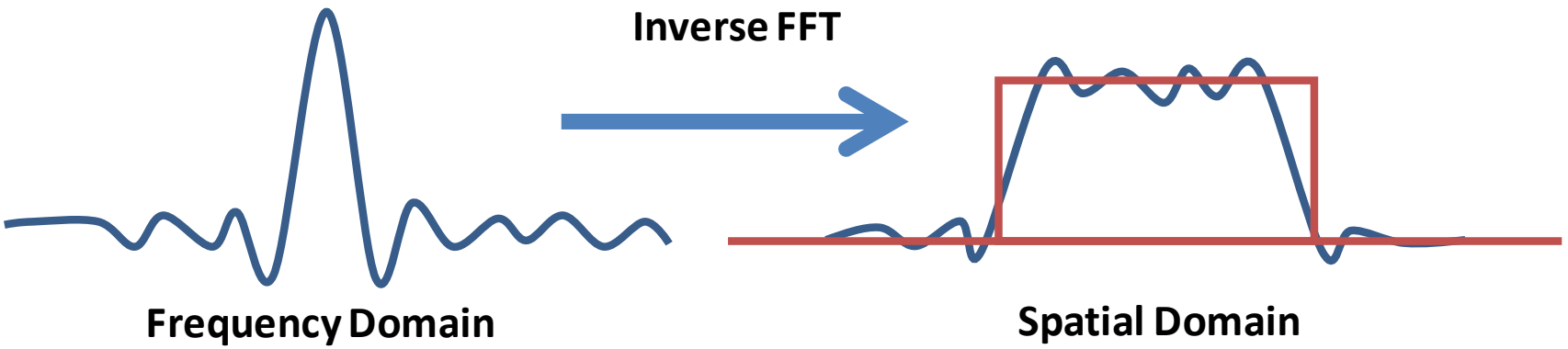

Gibbs Artefact

- Artefact appears at the edge of objects
- Reduced by
  - increasing the number of PE steps (256→ 320)
  - Increase sampling time
- Common in spine, where it can mimic appearance of syringomyelia



Truncation artefact (Gibb's ringing)

Gibbs Artefact

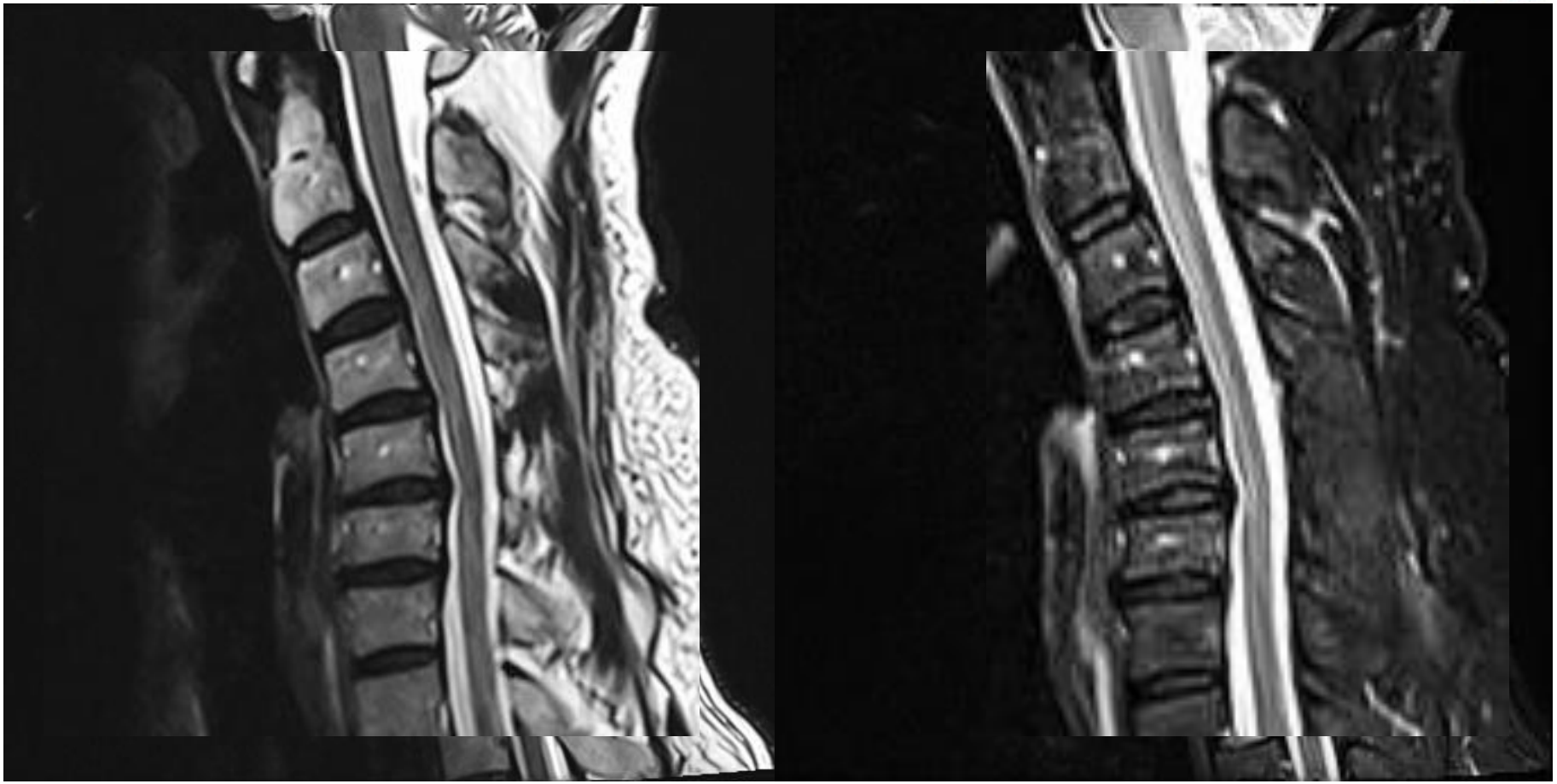

Truncation artefact (Gibb's ringing)

NHS
Hull University Teaching Hospitals
NHS Trust

Technique/Matrix	128 x 128 (1.56mm inplane) 00:20	256 x 256 (0.78mm inplane) 00:37	512 x 512 (0.39mm inplane) 01:11	1024 x 1024 (0.20mm inplane) 02:19
AirRecon DL (High)				
Original				

AirRecon DL: Increased SNR, increased resolution and artefact (Gibbs Ringing) reduction.
Reduction in signal averaging and/or matrix size can be utilised for time savings.

Truncation artefact (Gibb's ringing)

Hull University Teaching Hospitals NHS Trust

Technique/Matrix	256 x 256 (0.78mm inplane)		
AirRecon DL (High)			Reduction in Gibbs ringing artefact
Original			

Water molecule H_2O

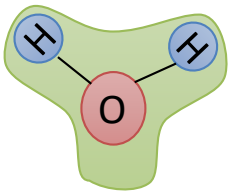

Fat molecule $–CH_2–$

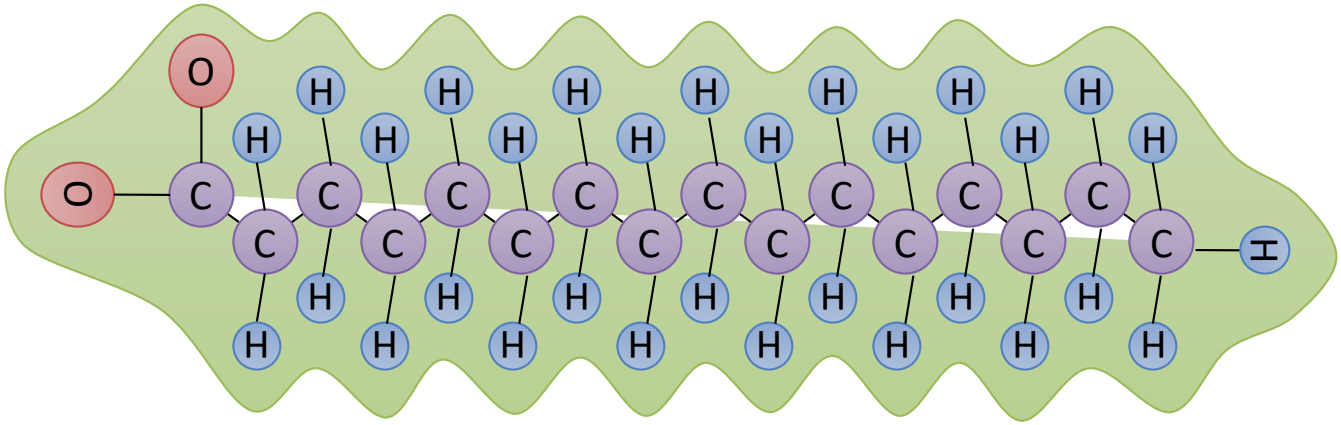

- Fat has a shorter T_1 relaxation rate than water
- The two dominate fat peaks (1.3ppm and 0.9ppm) experience a lower local magnetic field (B_0) due to the electron shielding compared to water (4.7ppm)
- Fat precesses at a lower frequency than water

Tissue	T_1 1.5T (ms)
Fat	260
Liver	500
Grey Matter	900
CSF	2400

Chemical Shift

- electron cloud around an atom shields the nucleus from the magnetic field (σ):

- different resonant frequencies for different molecules

$$\omega_0 = \gamma(1 - \sigma)B_0$$

γ = gyromagnetic ratio

B_0 = magnetic field strength

ω_0 = resonant frequency

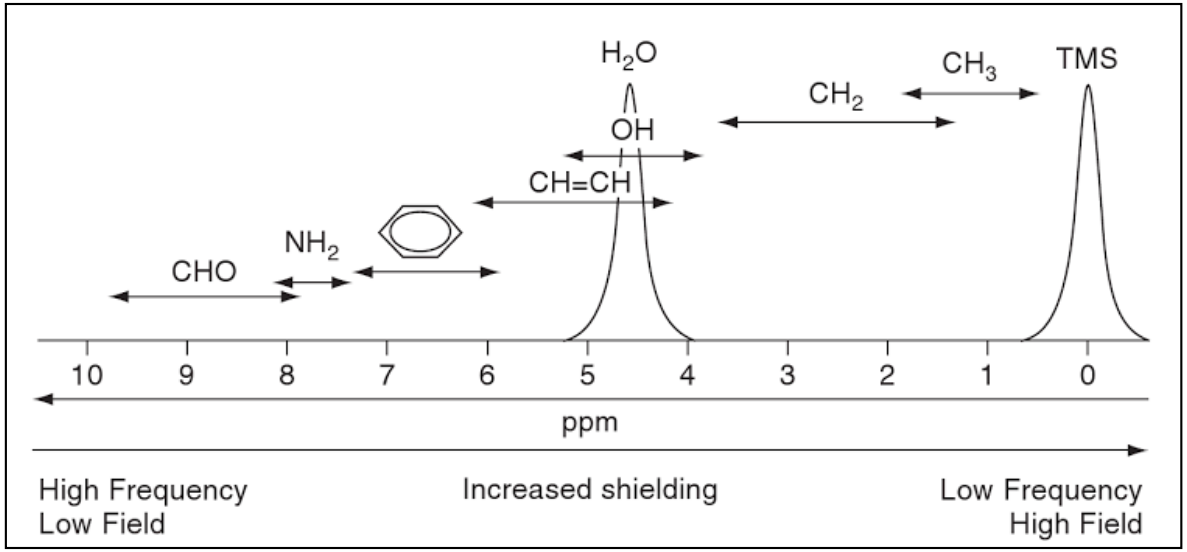

Water and Fat Molecules

- The two dominate fat peaks (1.3ppm and 0.9ppm) experience a lower local magnetic field (B_0) due to the electron shielding compared to water

- Fat precesses at a lower frequency than water

- Chemical shift is 3.5ppm

1.5T scanner the fat-water frequency difference (Δf)

$$\Delta f = (64\ \text{MHz})(3.5\ \text{ppm}) = (64 \times 10^6\ \text{Hz})(3.5 \times 10^{-6}) \approx \underline{\mathbf{220\ Hz}}$$

3.0T scanner the fat-water frequency difference (Δf)

$$\Delta f = (128\ \text{MHz})(3.5\ \text{ppm}) = (128 \times 10^6\ \text{Hz})(3.5 \times 10^{-6}) \approx \underline{\mathbf{440\ Hz}}$$

Phase Cycling

- Differences in precessional frequencies of water and fat cause signals to move in phase (IP) and out of phase (OOP) with one another.

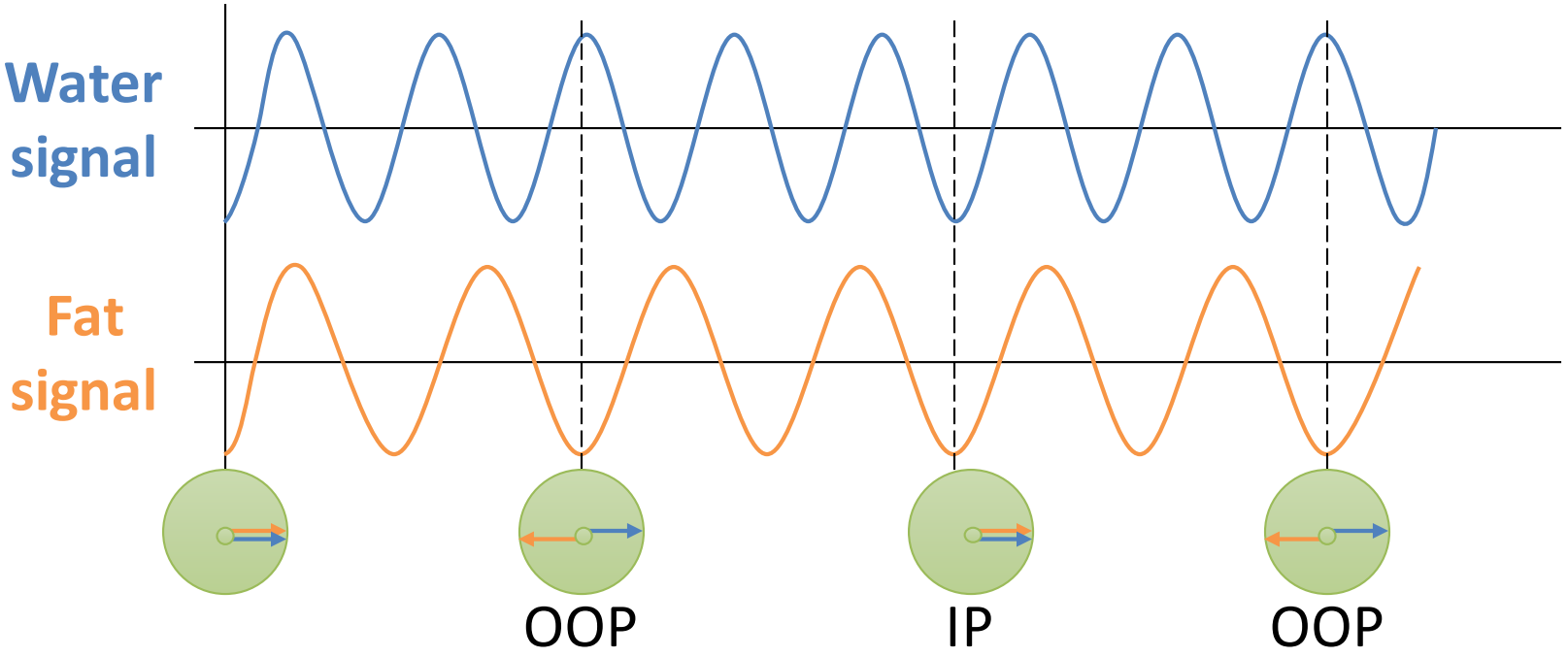

Chemical Shift (1st kind)

- Difference in resonant frequency of water and fat (chemical-shift). One of the few MR artefacts to occur in **frequency encoding direction**

- @ 1.5 T the difference = 220Hz, @ 3T = 440Hz

- Due to chemical shift, voxels containing fat will not have the expected resonant frequency and will be spatially misregistered in the final image

$$\omega_{fat} = \gamma . B_{fat}$$

$$\omega_{water} = \gamma . B_{water}$$

- Results in signal void (no water or fat) and build-up (superimposed water and fat) on opposite sides of the anatomy

Chemical shift, receiver bandwidth

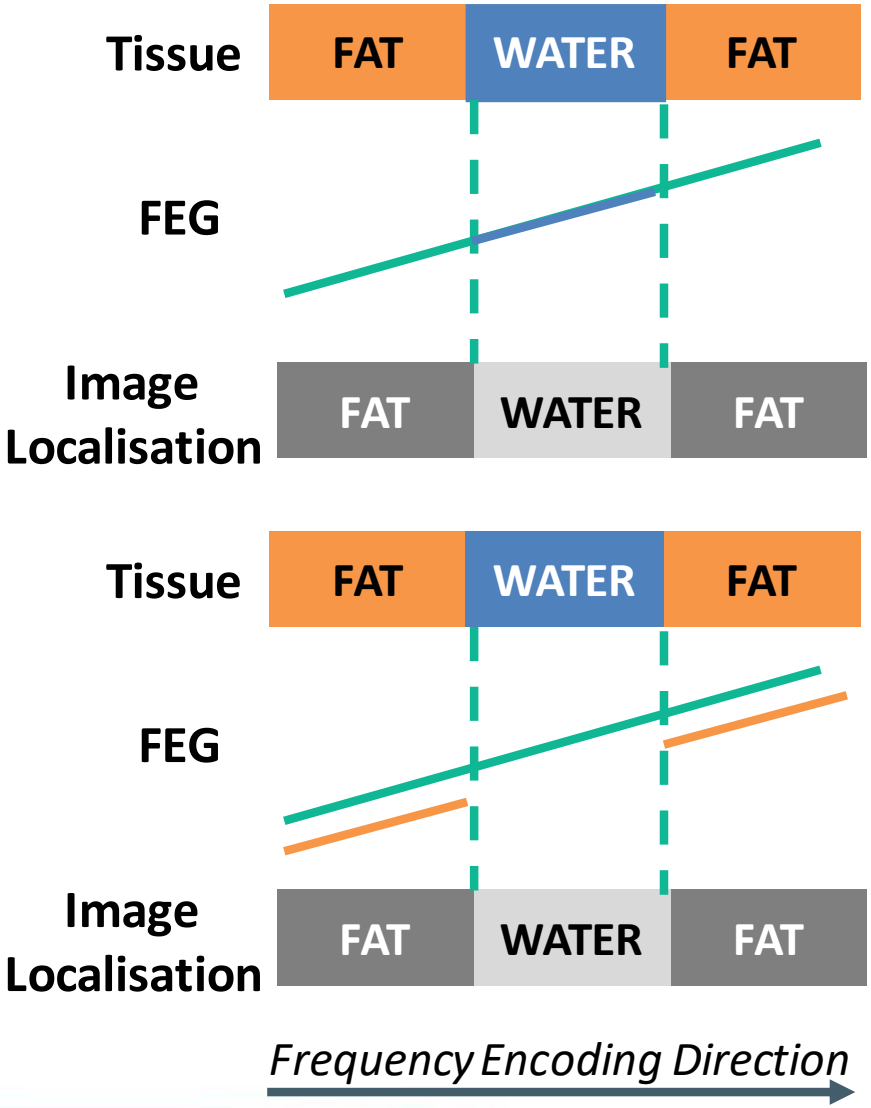

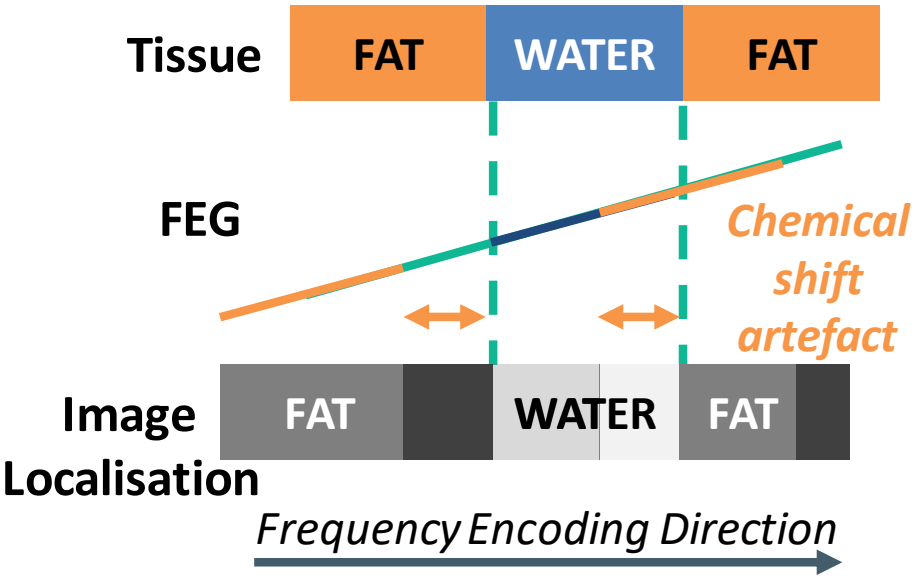

Chemical shift due to electron shielding

$\omega_{lower} = \gamma . B_{lower}$

Chemical shift, receiver bandwidth





Chemical Shift (1st kind)

- Chemical shift artefact is increased by higher B_0 or a deceased bandwidth (BW)
- If we decrease BW→ lower BW per pixel and thus fewer frequencies per pixel
- For example:
  - 256 x 256 image. 1.5T scanner.
  - BW decreased from 32 to 16 kHz
  - BW/ pixel = 16000/256= 62.5 Hz per pixel
  - 220 Hz/ 62.5 Hz/ pixel ~ 4 pixels misregistration
  - as opposed to ~ 2pixels at 32kHz BW
- Since chemical shift is increases with B_0 (440Hz fat-water separation at 3T), higher bandwidths are required to minimise the associated artefact

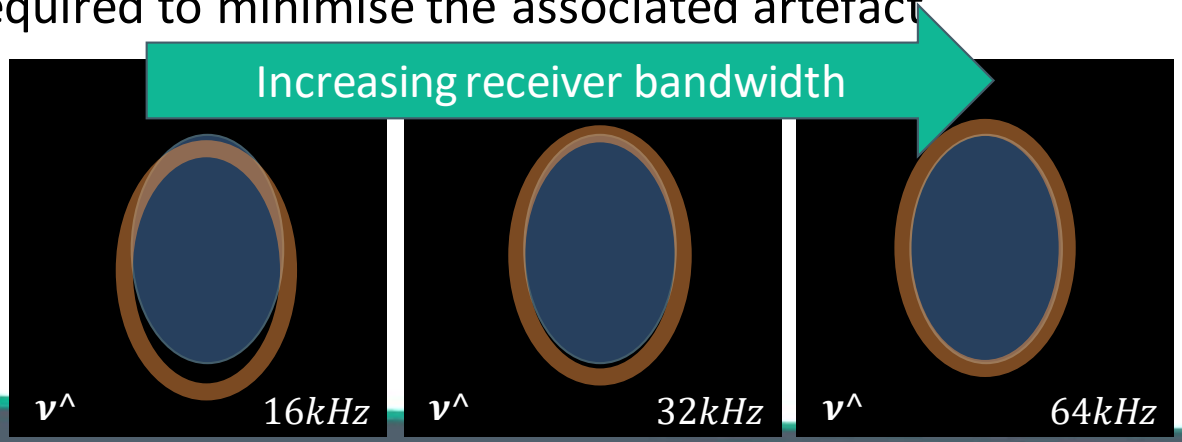

Chemical Shift (2nd kind) - Phase cancellation artefact

- 'black line', 'India ink' or 'phase cancellation artefact' occurs only on gradient echo sequences where fat and water are present in the same voxel

- The absence of 180° refocusing pulse causes phase shift between fat and water when echo is formed

- Difference in resonant frequency of water and fat leads to phase differences when echo is formed.
  - At 1.5T - every 4.4ms fat/water will be in-phase
  - At 2.2 ms fat/water are exactly out of phase

- For OOP TE's → out of phase voxels containing similar amounts of fat & water will cancel and produce a black line at tissue/fat borders

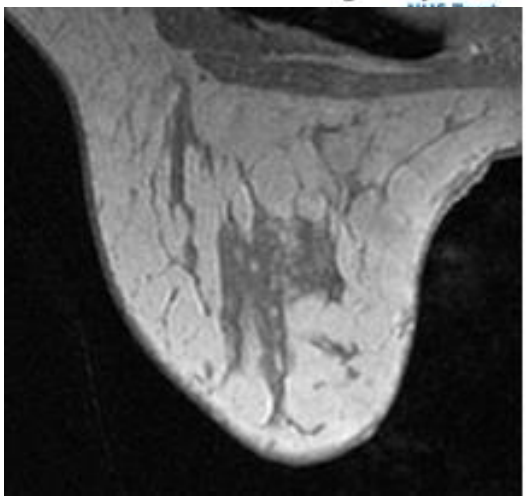

In-phase

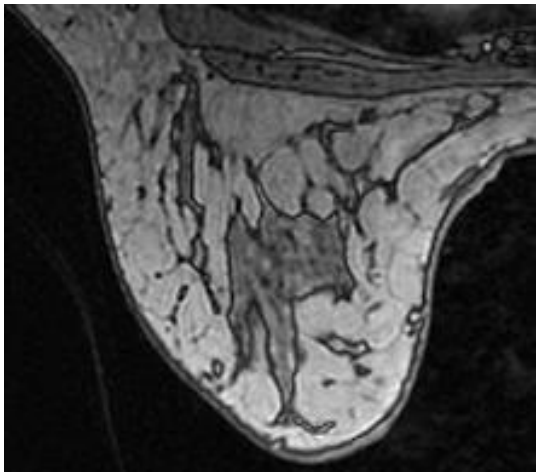

Out-of-phase

Fat-water swaps in Dixon MRI

DIXON swap artefact

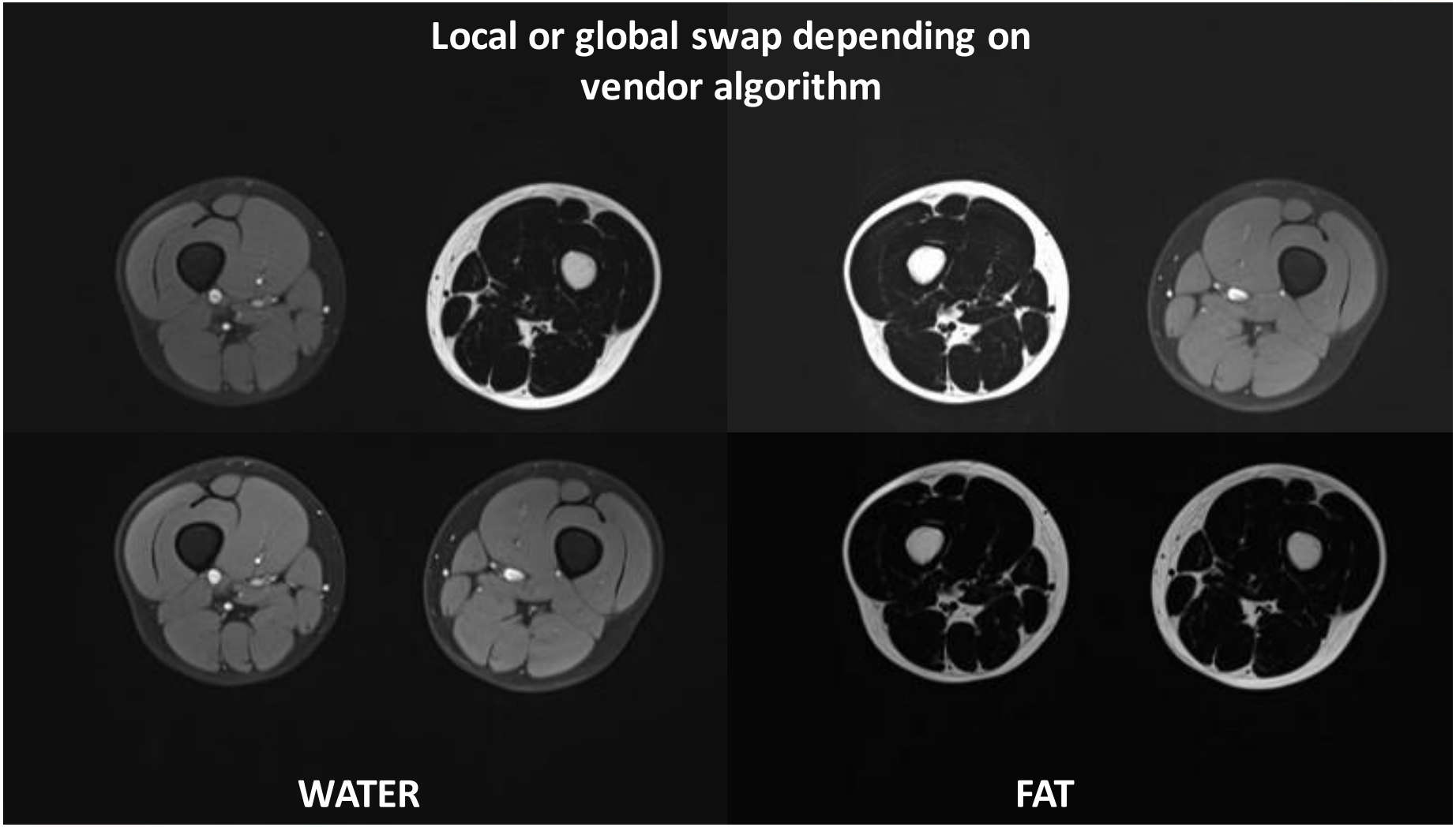

Fat-water swaps in Dixon MRI

DIXON swap artefact

T1+C – WATER ONLY

T1+C – FAT ONLY

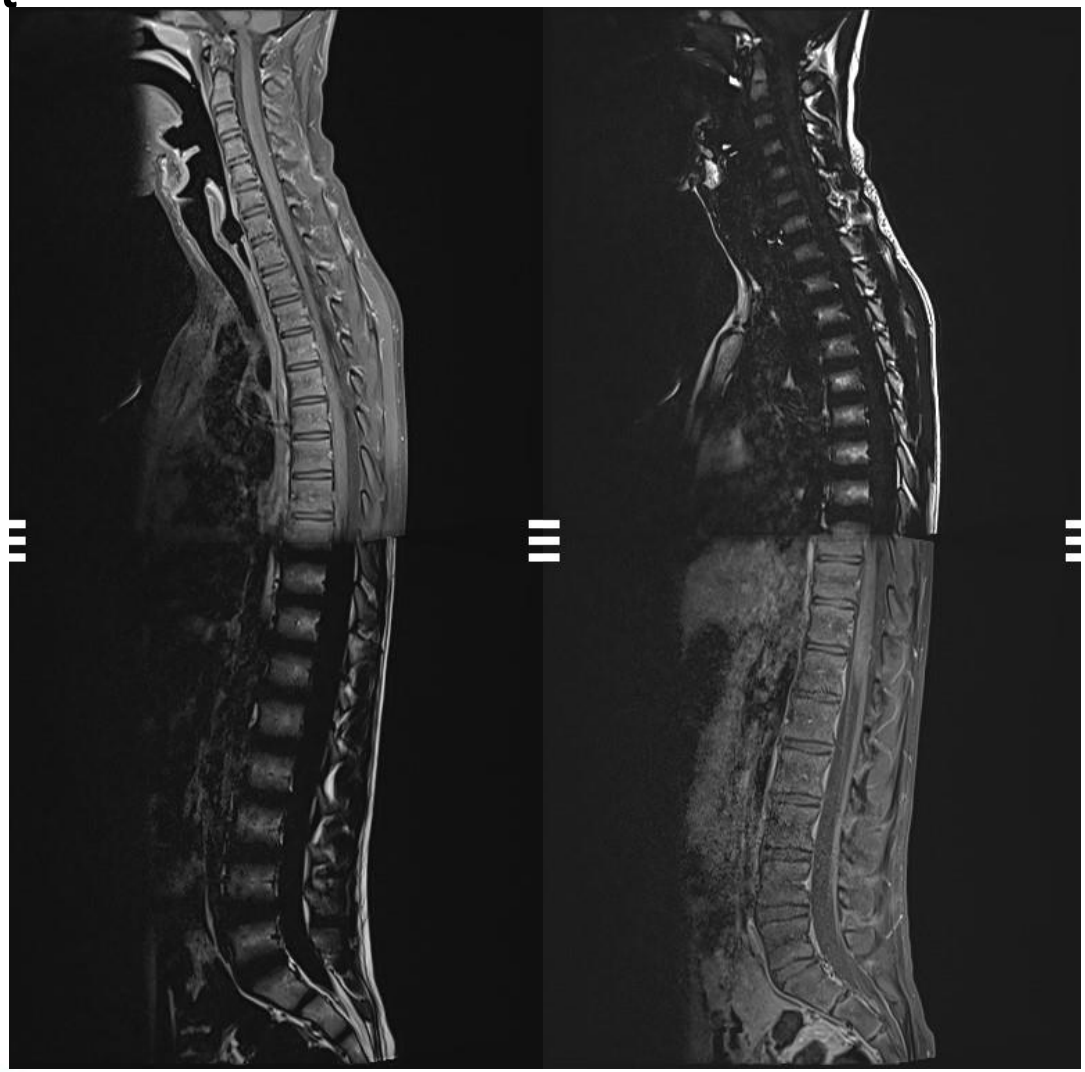

T1+C – FAT ONLY

T1+C – WATER ONLY

Poor geometry-factor with high acceleration factors in parallel imaging

Hull University Teaching Hospitals NHS Trust

No parallel imaging acceleration



SENSE Parallel imaging factor = 2.0



SENSE Parallel imaging factor = 2.5



SENSE Parallel imaging factor = 3.0

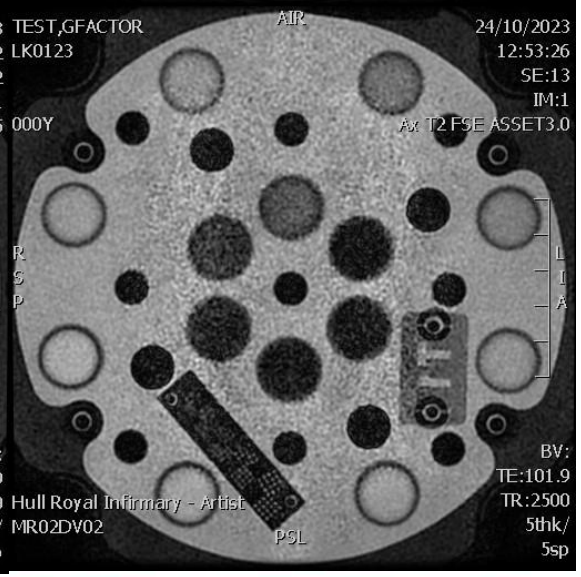

Poor geometry-factor with high acceleration factors in parallel imaging

Hull University Teaching Hospitals NHS Trust

No parallel imaging acceleration



ARC Parallel imaging factor = 2.0



ARC Parallel imaging factor = 2.5



ARC Parallel imaging factor = 3.0

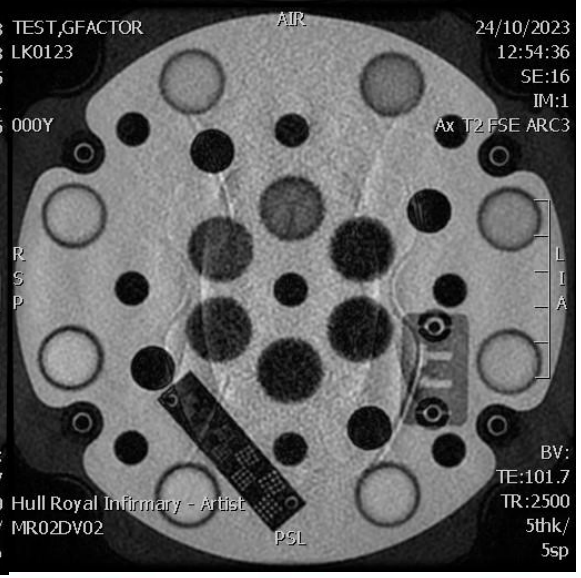

Poor geometry-factor with high acceleration factors in parallel imaging

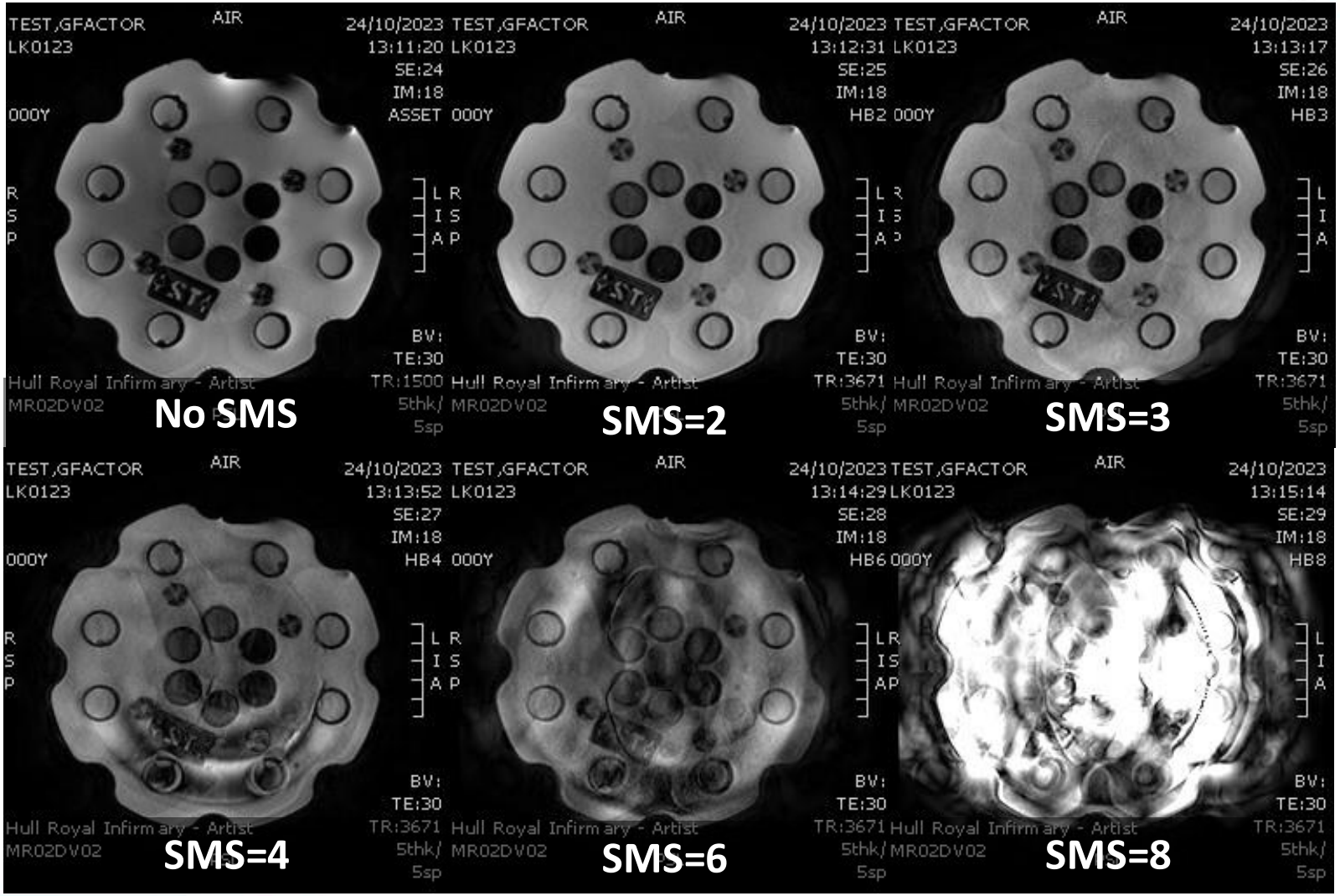

Poor geometry-factor with high acceleration factors in parallel imaging

Hull University Teaching Hospitals NHS Trust

No parallel imaging acceleration



ARC Parallel imaging factor = 2.0 Compressed Sense factor = 1.0



ARC Parallel imaging factor = 2.0 Compressed Sense factor = 1.4



ARC Parallel imaging factor = 2.0 Compressed Sense factor = 1.8



B_0 Field out of specification
Moiré fringes

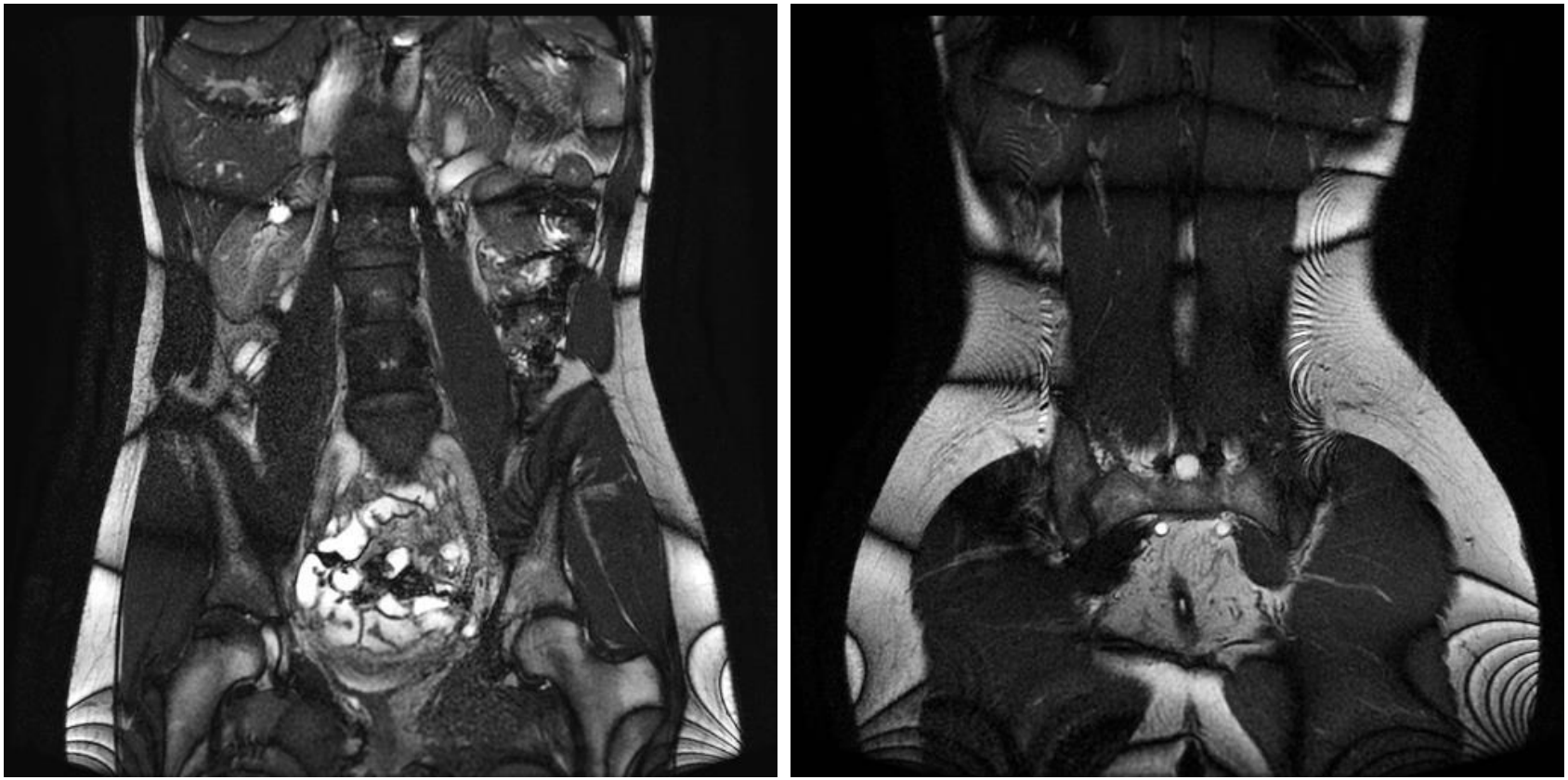

Due to non-perfect homogeneity of the B_0 field from one side of the body to the other, aliasing of one side of the body to the other results in superimposition of signals of different phases that alternatively add and cancel on gradient echo imaging.

B_0 Field out of specification SWI

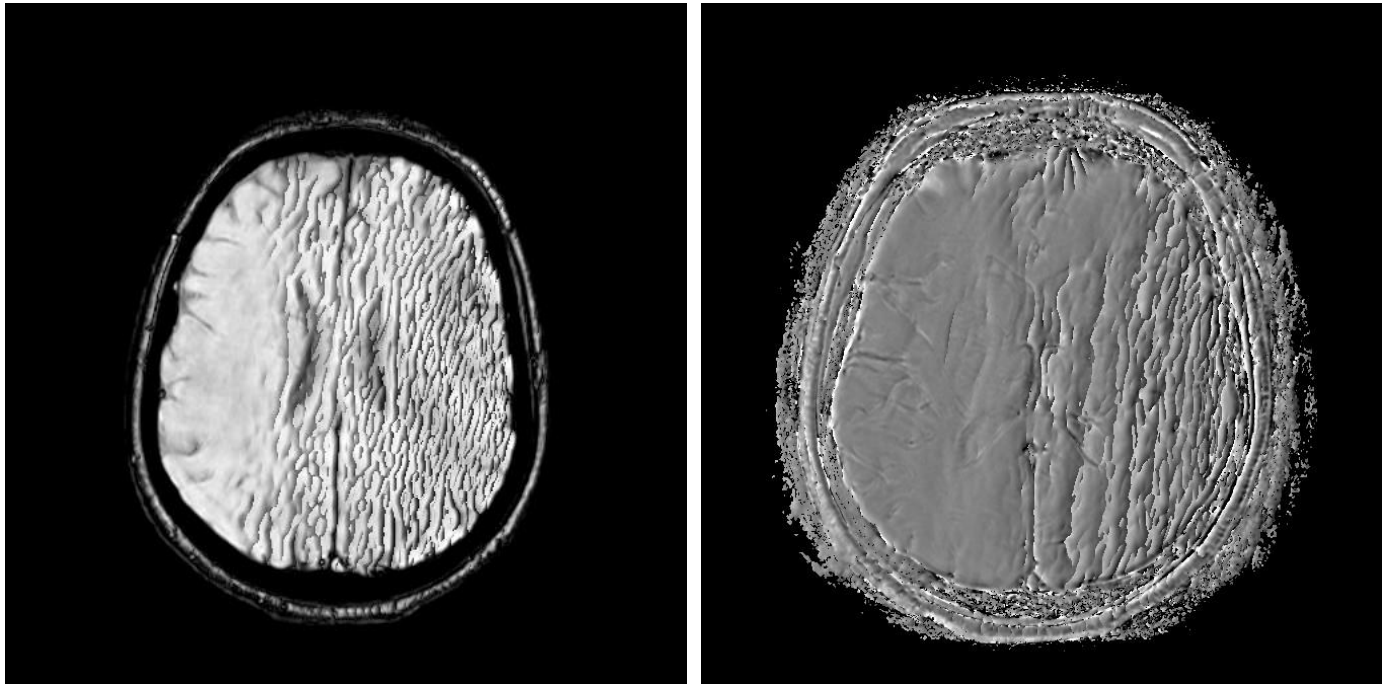

B_0 Field out of specification on mobile scanner.

Gradient Field Nonlinearity

- Gradient coils produce linear magnetic field gradients over a limited distance
- Scanning with large FOVs may include regions of gradient nonlinearity
  - i.e. whole spine imaging
- Produces image distortions, compressing image information at the FOV edge
- Unlike geometric distortions arising from B_0 magnetic field inhomogeneities or susceptibility differences, gradient field nonlinearities are predictable
- Most vendors apply a correction (2D/3D) to the images to stretch out the pixels resulting in a curved edge to large FOV images

2D/3D Geometry Correction

NHS
Hull University Teaching Hospitals
NHS Trust

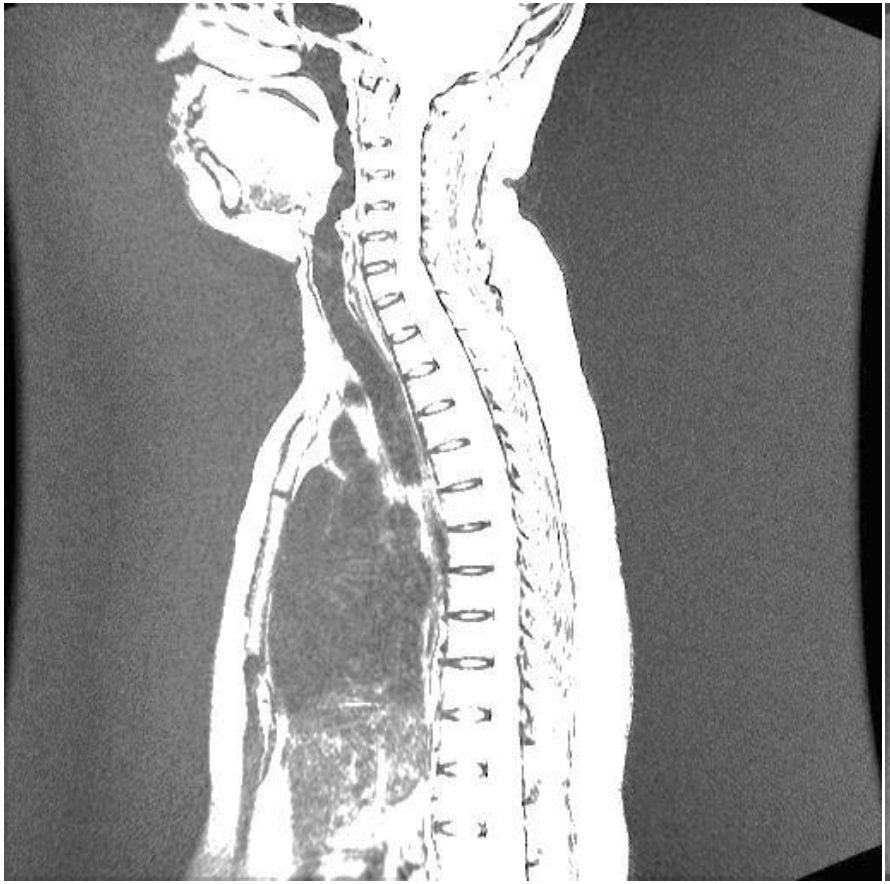

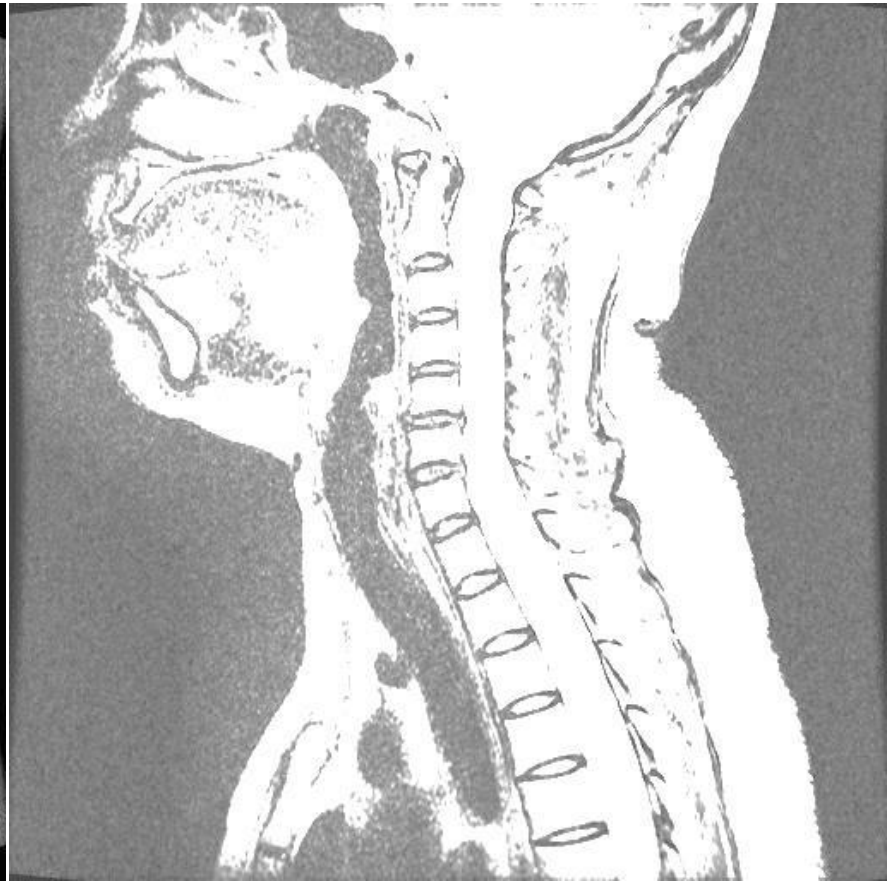

2D/3D Geometry Correction – 45cm FOV

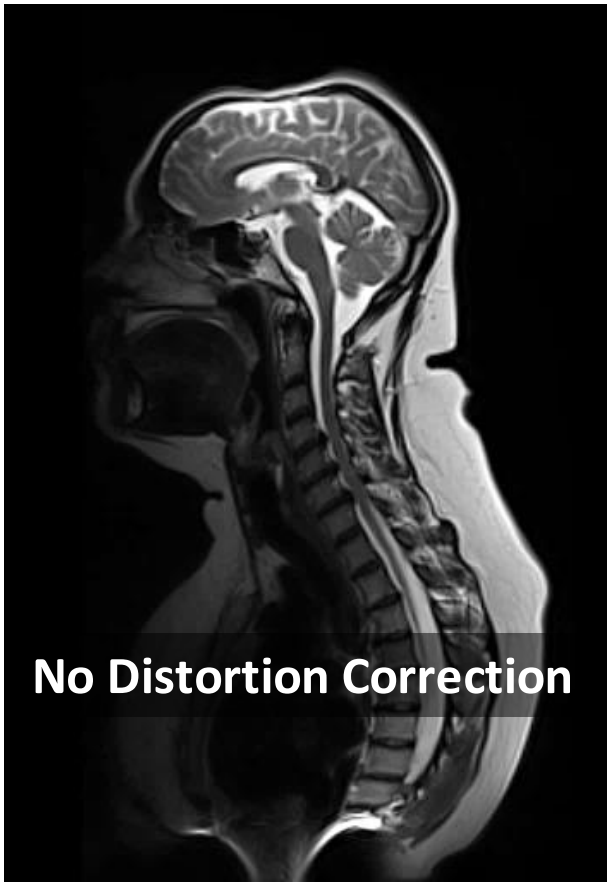

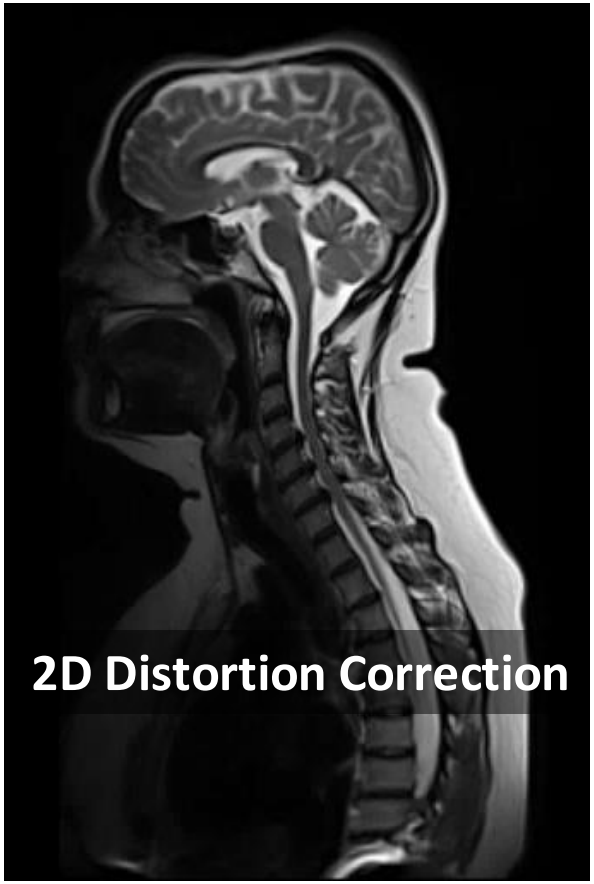

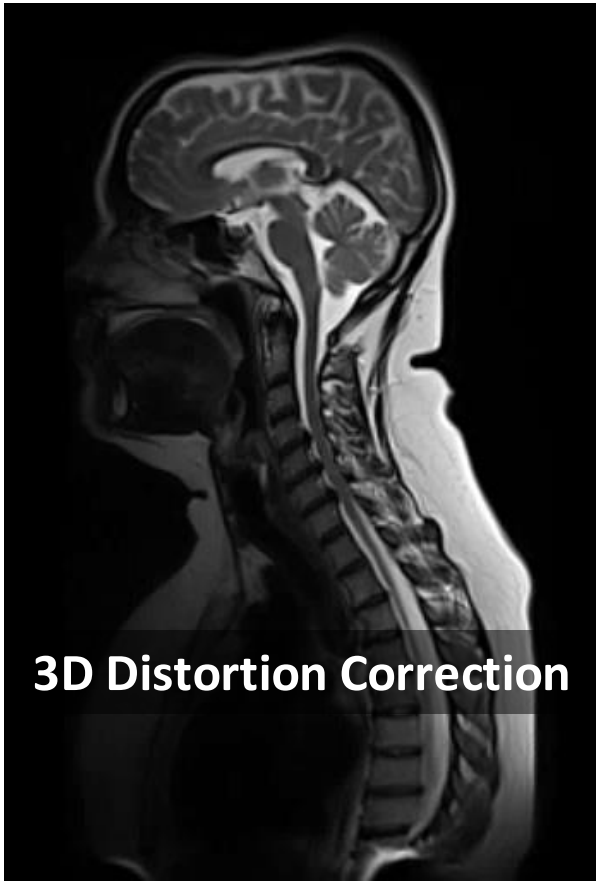

Calibration scan and RF artefacts

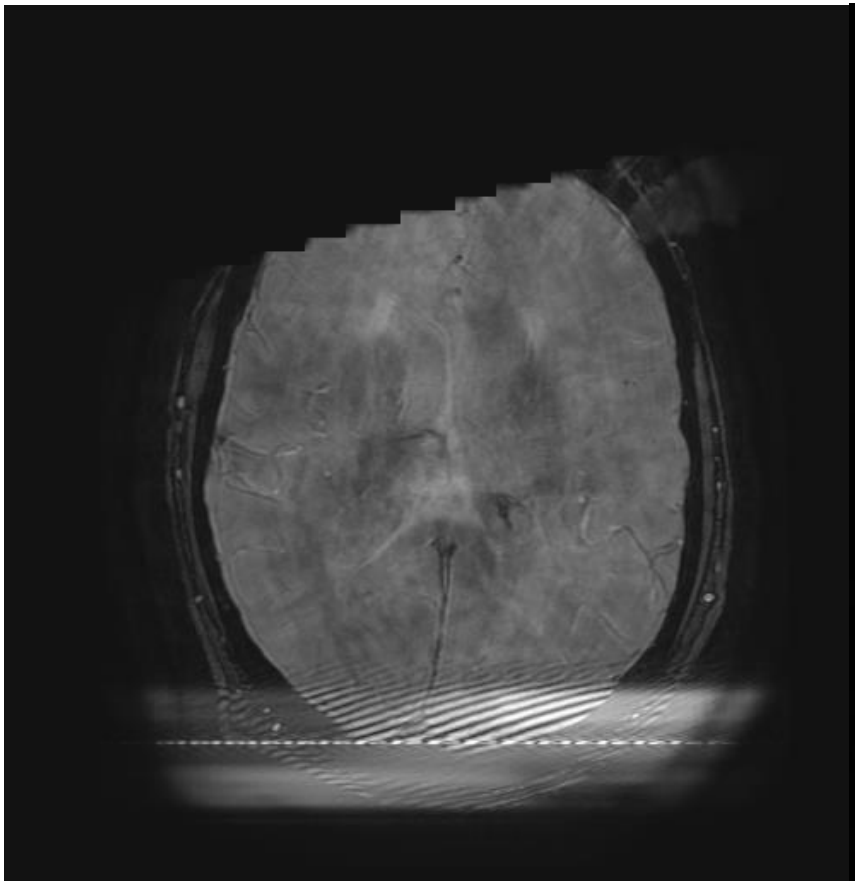

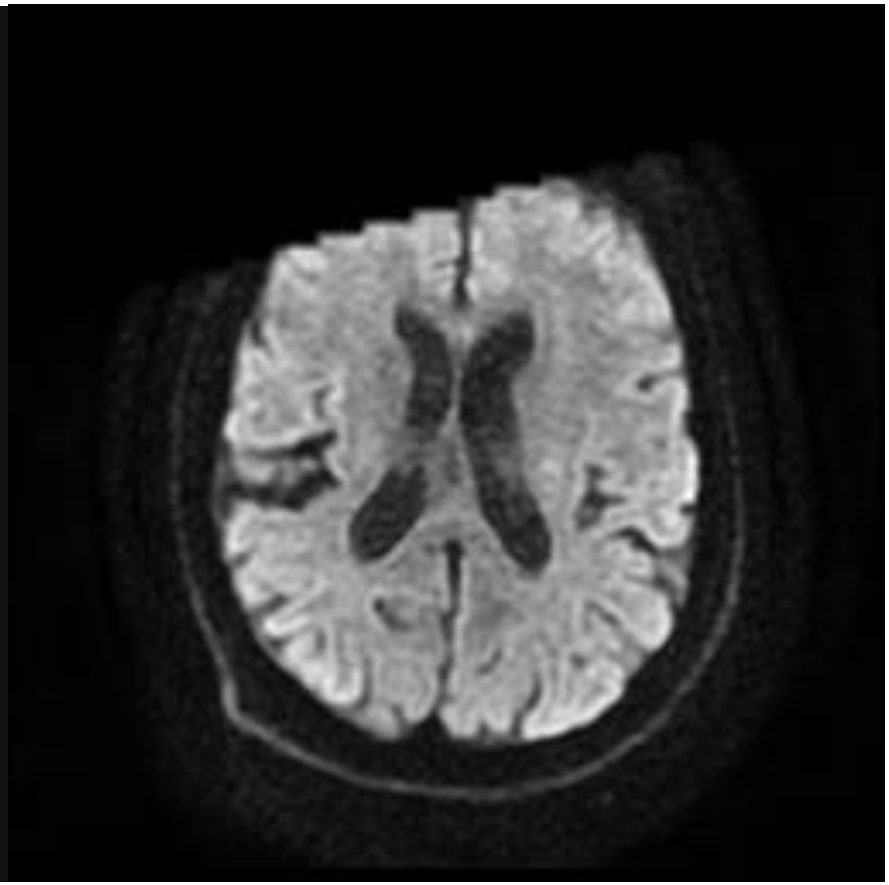

Cross-Talk

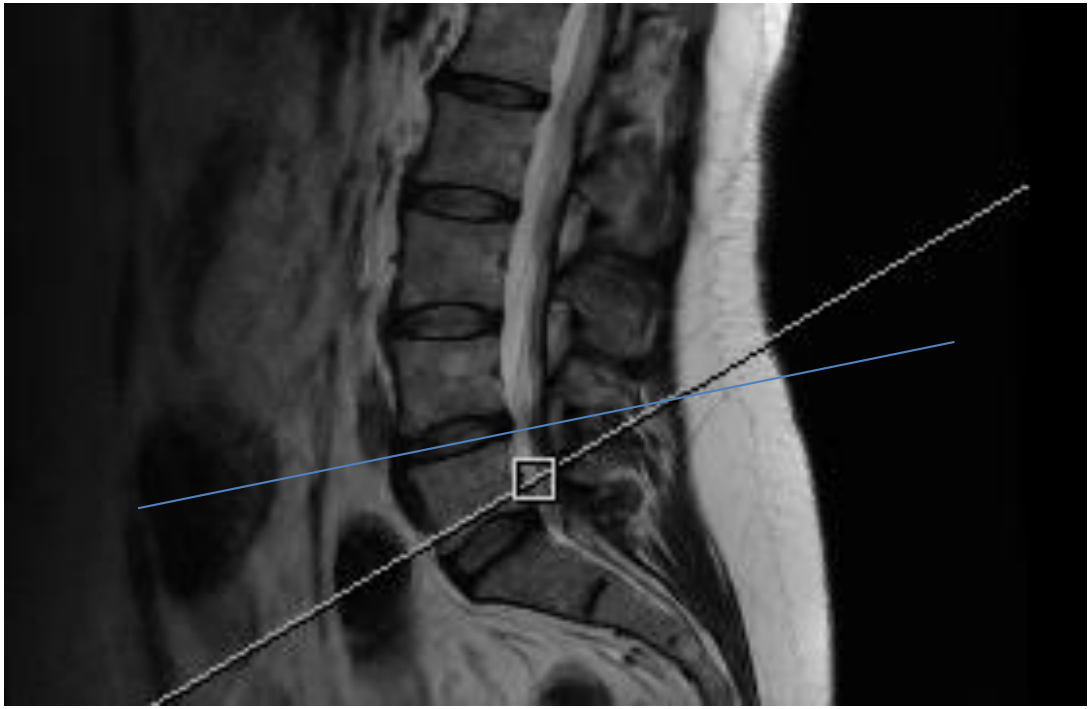

When multislice acquisitions overlap, the protons belonging to more than one slice become overly saturated.



Cross-Talk

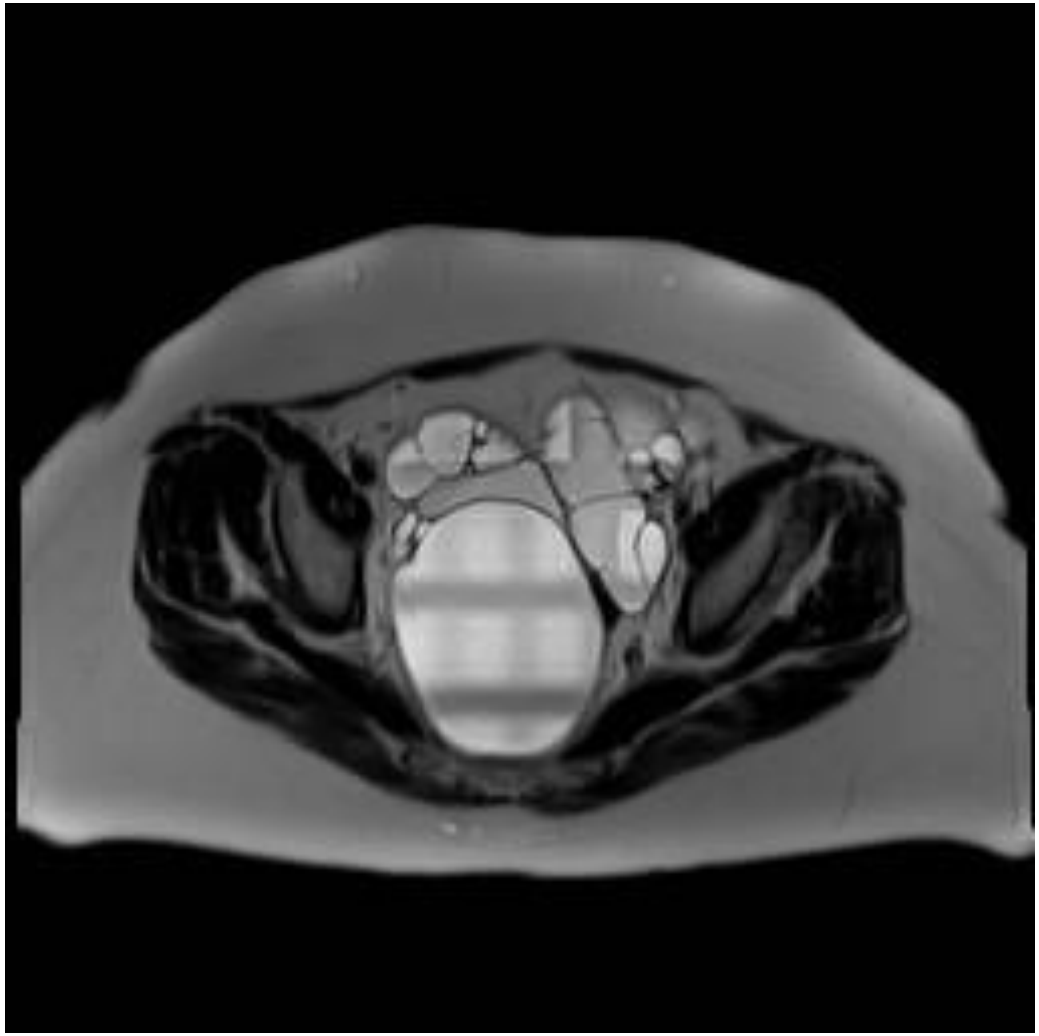

Other MR Artefacts

Cross-Talk

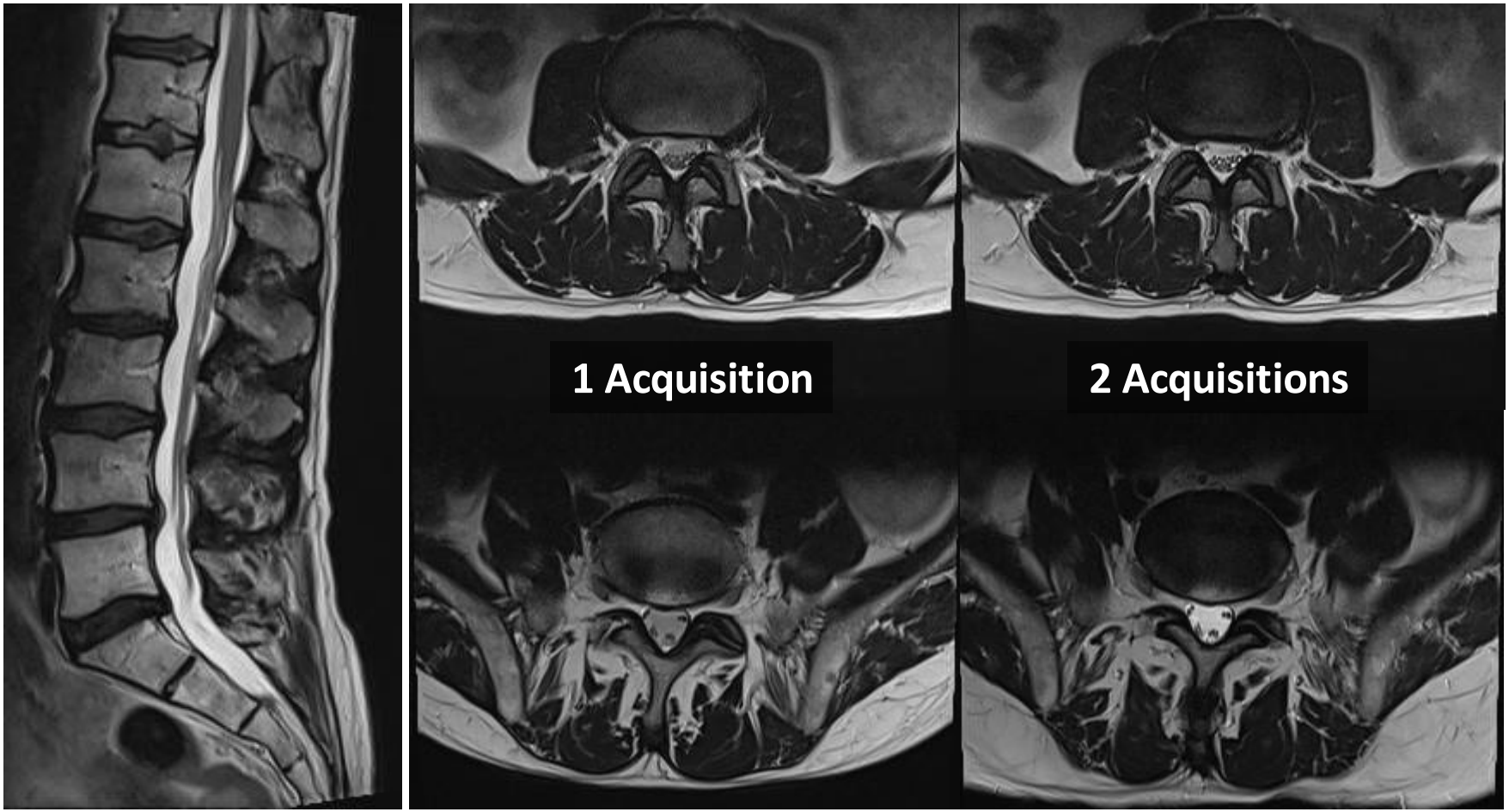

DIXON & B_0 Field out of specification at edge of FOV



- Due to non-perfect homogeneity of the B_0 field

Hull University Teaching Hospitals NHS Trust

Incorrect Coil Selection





Other MR Artefacts

Coil Failure

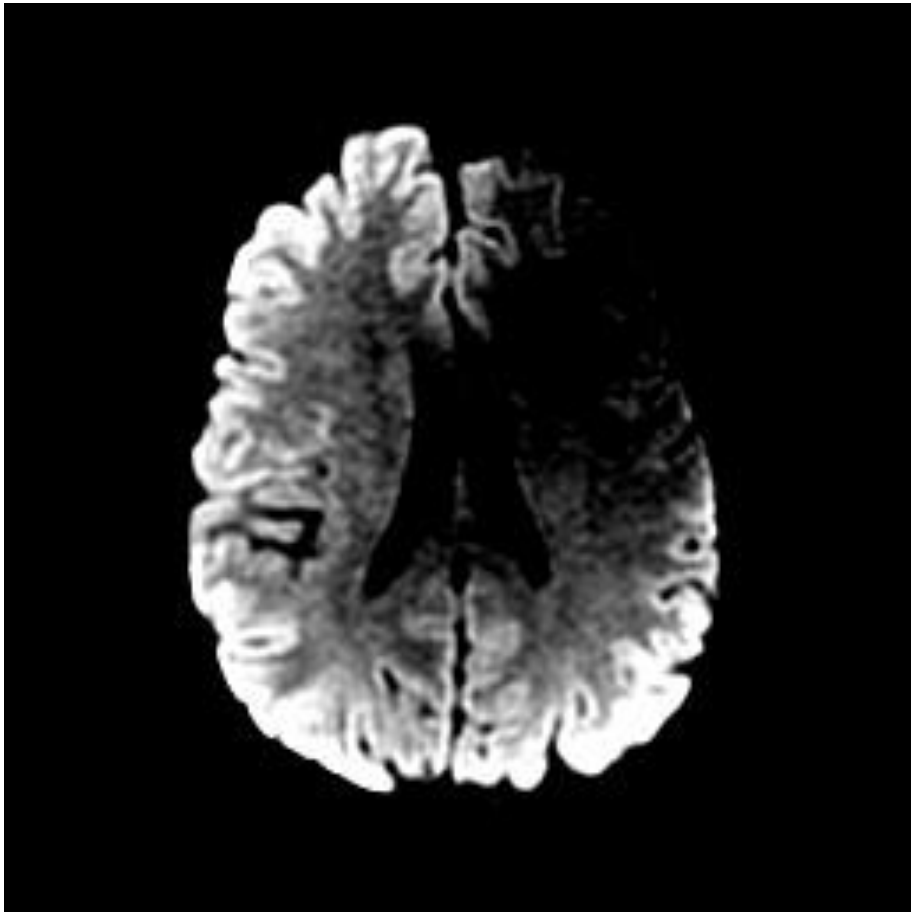

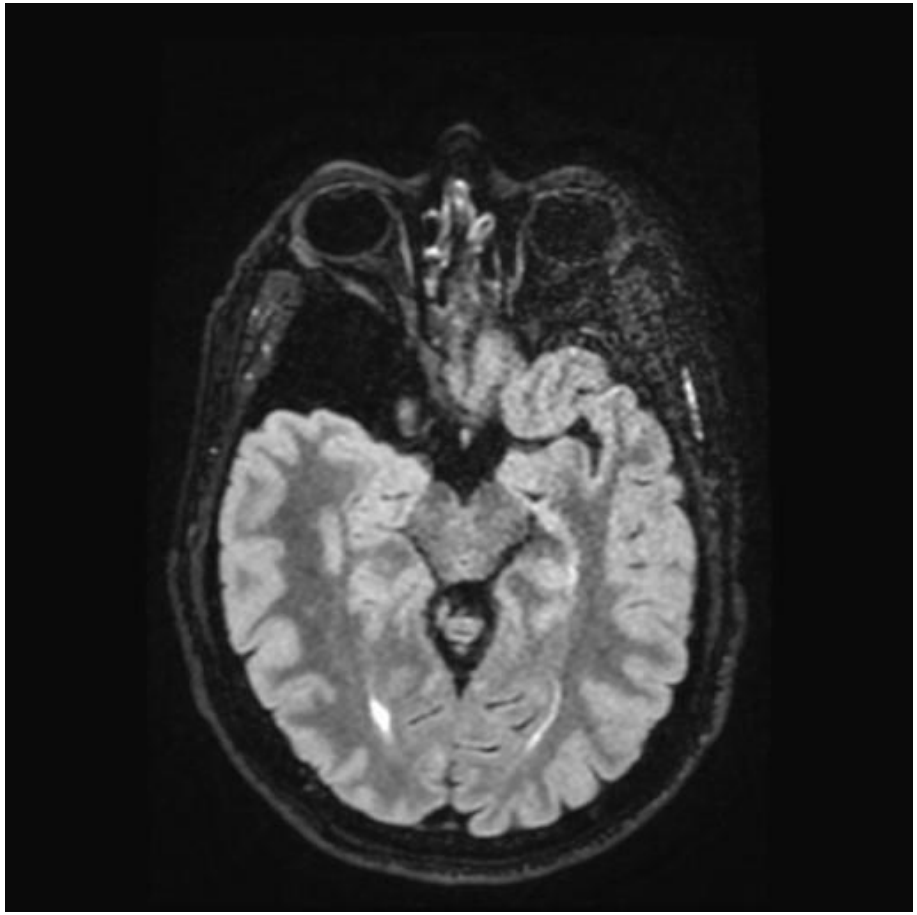

7.9 MR artefacts and artefact reduction techniques

- Motion artefacts, respiratory gating, navigated sequences, saturation bands, radial-type k-space acquisitions
  - *Motion/Flow artefacts principally occurs in phase encoding direction due to disparity in sampling times for frequency (msec) and phase (sec) encoding times. Due to change in anatomy location relative to encoding resulting in spatial blurring.*
  - *Optimise PE & FE direction. Gated (respiratory/ECG). Saturation bands. Optimise k-space sampling technique (radial). Alternatively use 'breath hold' or 'single shot' techniques. Anti-peristalsis drugs (buscopan)*

7.9 MR artefacts and artefact reduction techniques

- B_0 inhomogeneities, e.g. air/tissue interfaces or metal implants
  - *Artefacts occur at interfaces between materials of very different susceptibilities as local distortions are caused in the magnetic field. Natural boundaries e.g. air / tissue or tissue/bone. Also any metal (not just ferromagnetic)*
  - *Results in local distortion to B_0 field. Local field distortion can lead to precessional frequency shift → when G_{ss} is performed there is an absence of spin excitation and absence of signal*
  - *When signal is acquired → shift of spatial localisation which causes signal loss and/or image distortion.*

7.9 MR artefacts and artefact reduction techniques

- B_1 inhomogeneities especially at 3T
  - *inhomogeneities in the local transmitted magnetic field degrade image quality and cause spatially varying errors in the transmitted flip angle (FA)*
  - *More pronounced at 3T. Reduced using multi-transmit systems. Worse in fluid (ascites)*
- RF interference: instantaneous (RF spikes); continuous RF interface
  - *Zipper artefact (continuous)*
  - *Herringbone (instantaneous)*
- Phase wrap
  - *Two spatial locations share same phase information. Reduced by increased FOV or increasing phase oversampling or changing PE direction*
- Truncation artefact (Gibb's ringing)
  - *Caused when number of sampling points are low and sharp tissue boundaries (bright-dark). Inability for FT to appropriate sharp signal changes.*

7.9 MR artefacts and artefact reduction techniques

- Chemical shift, receiver bandwidth
  - *One of few artefacts to occur in frequency direction. Worse at high field strengths. Artefact reduced by increasing pixel bandwidth*
- Fat-water swaps in Dixon MRI
  - *Reconstruction artefact. Difficult to prevent. Look at fat-only images if suspicious.*
- Poor geometry-factor with high acceleration factors in parallel imaging
  - *Be aware of noise breakthrough artefacts or unaliasing artefacts*