NHS
Hull University Teaching Hospitals
NHS Trust

FRCR Lecture II



Imaging and Optimisation

Nuclear Medicine



Dr Helen Gill
Clinical Scientist
Nuclear Medicine Department
Castle Hill Hospital
Hull University Teaching Hospitals NHS Trust
email: helen.gill@hey.nhs.uk

Positional and Energy Co-ordinates

- PMT array detects light pulses from crystal
  - spatial (positional) information – X and Y signals
  - energy information – Z signal
- Z signal – the sum of the outputs of all PMTs
  - proportional to the total light output of the crystal



Pulse Height Analysis

- Gamma photons scatter
  - In the patient
  - Compton scatter in the crystal

Z-signal goes to PHA

- PHA sets
  - energy window
- PHA checks
  - the energy of the γ-ray
- If Z-signal acceptable
  - γ-ray is detected
  - position determined by X and Y signals

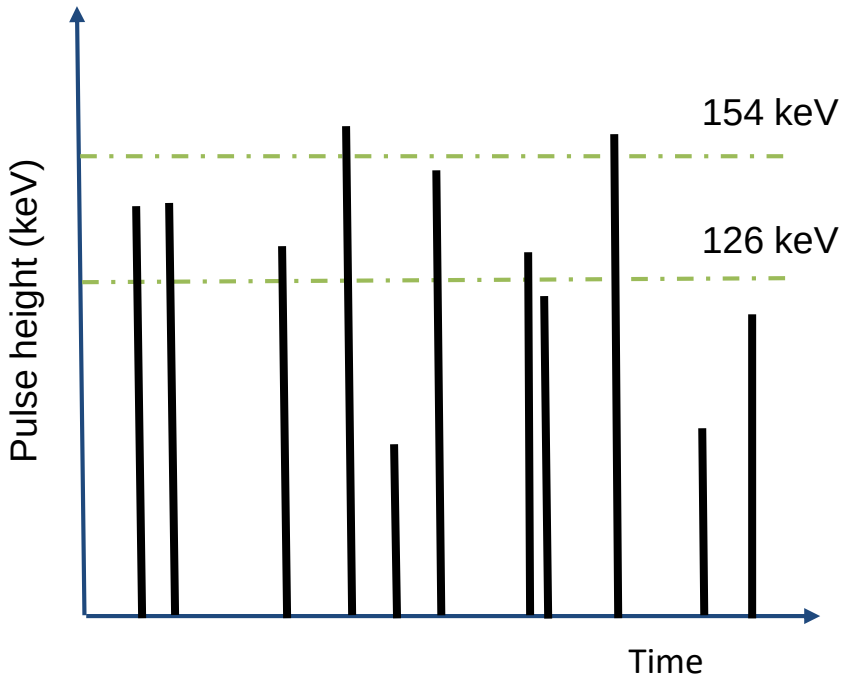

Idealised ^{99m}Tc Spectrum



Actual ^{99m}Tc Spectrum

- Scatter within the patient
- Compton scatter in the crystal

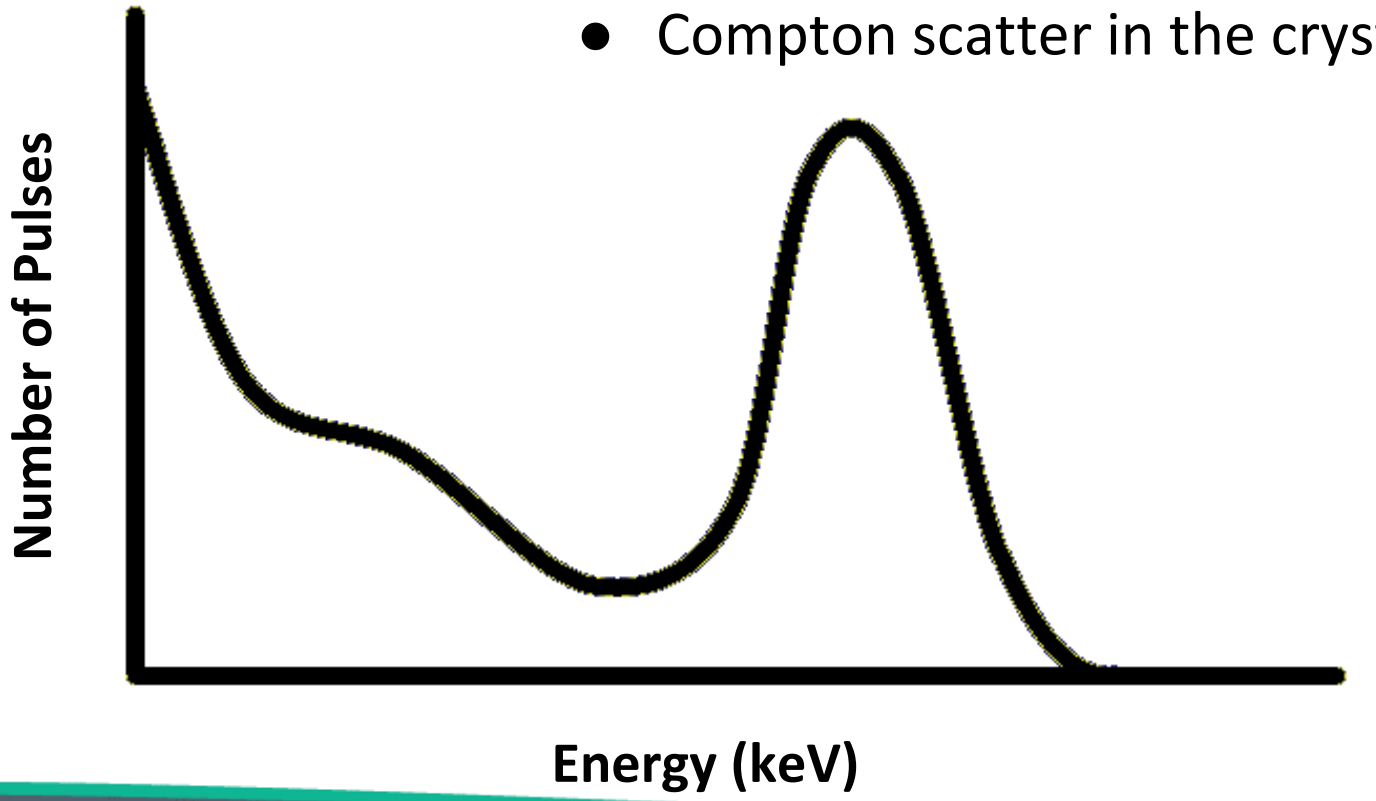

Energy Windows

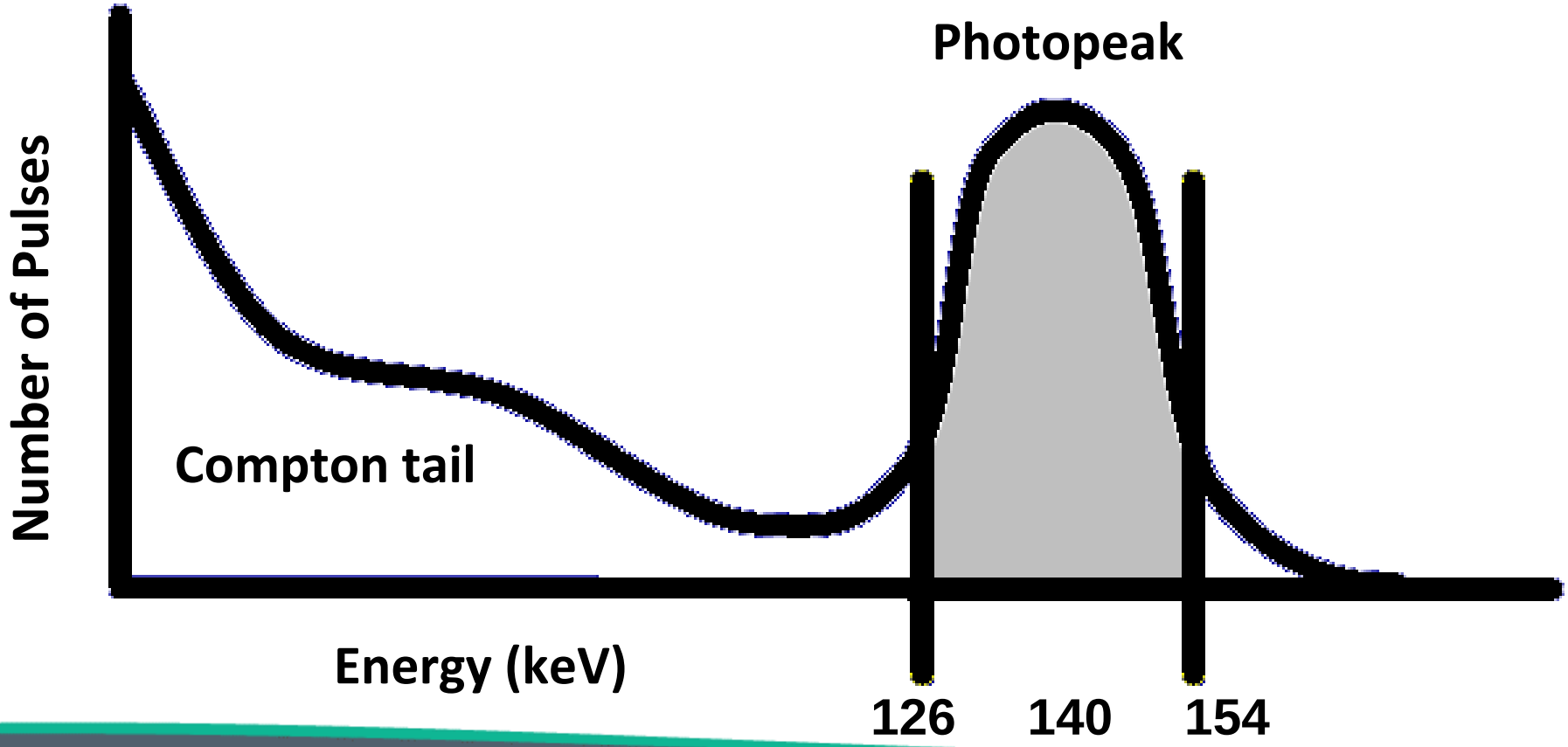

Hull University Teaching Hospitals NHS Trust
Remarkable people.
Extraordinary place.

Physical Measures of Image Quality

- Noise
  - Statistical uncertainty in the number of counts recorded
- Contrast
  - Difference in intensity in parts of the image corresponding to different concentrations of activity within the patient

Image Quality : Noise

- Any imaging system has statistical variations at all stages
  - Radioactive decay
  - Number of scintillation photons in crystal
  - Number of photoelectrons emitted from PMT photocathode / dynodes

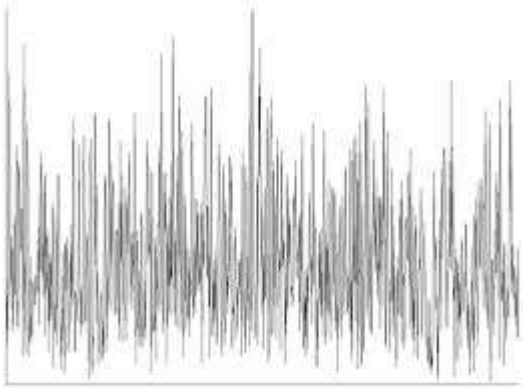



Image Quality : Noise

Noise = √(Mean Pixel Count)

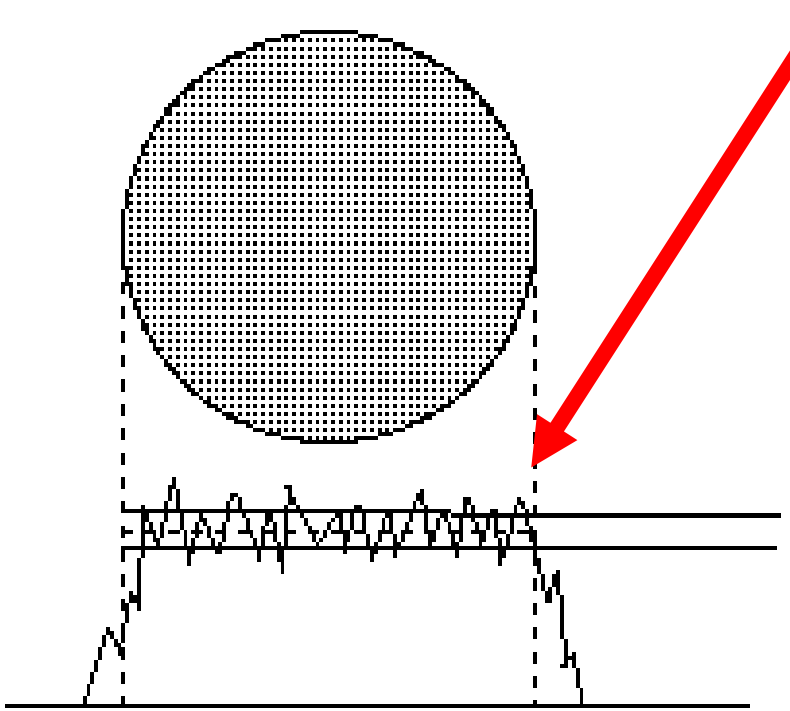

Mean Pixel Count	Absolute Noise	Noise (%)
100	10	10
10,000	100	1

Increased Counts → Reduced Noise

Image Quality : Contrast

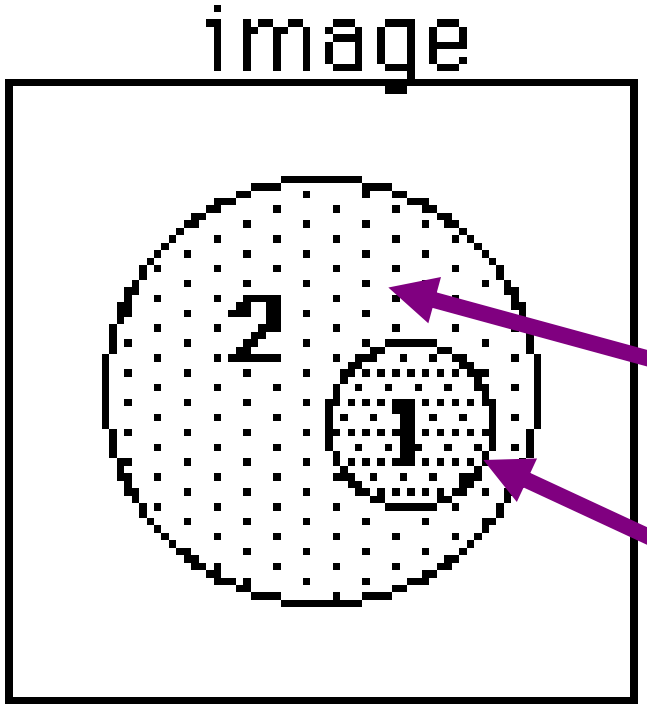

$$Contrast = \frac{(R_1 - R_2)}{R_2}$$

R_2: Background

R_1: Lesion

Image Quality : Recorded Counts

- Administered activity
  - diagnostic reference levels – ARSAC
- Uptake of tracer
  - radiopharmaceutical properties
- Attenuation / Scatter
  - patient size
- Acquisition time
  - typical imaging times: 3-60 minutes

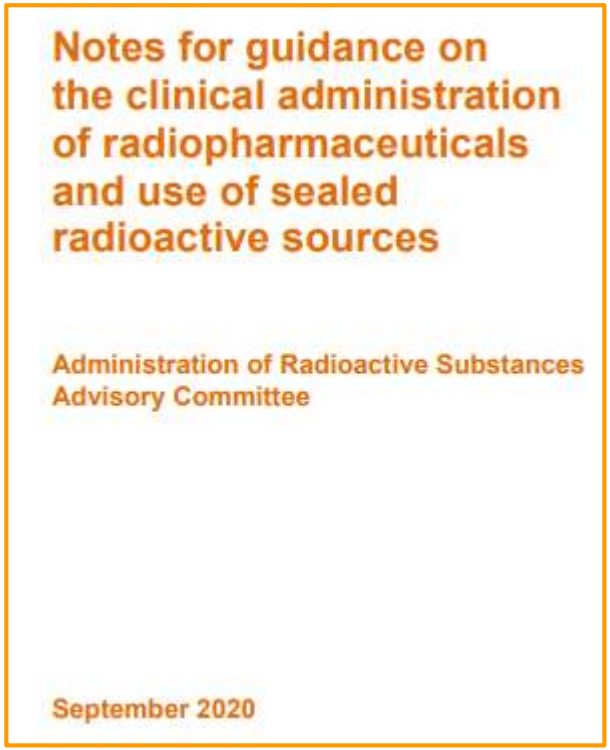

Image Quality : Patient Motion

- Long imaging times
  - limit to time patient can remain still
- Physiological motion
  - cardiac gating
  - respiratory gating

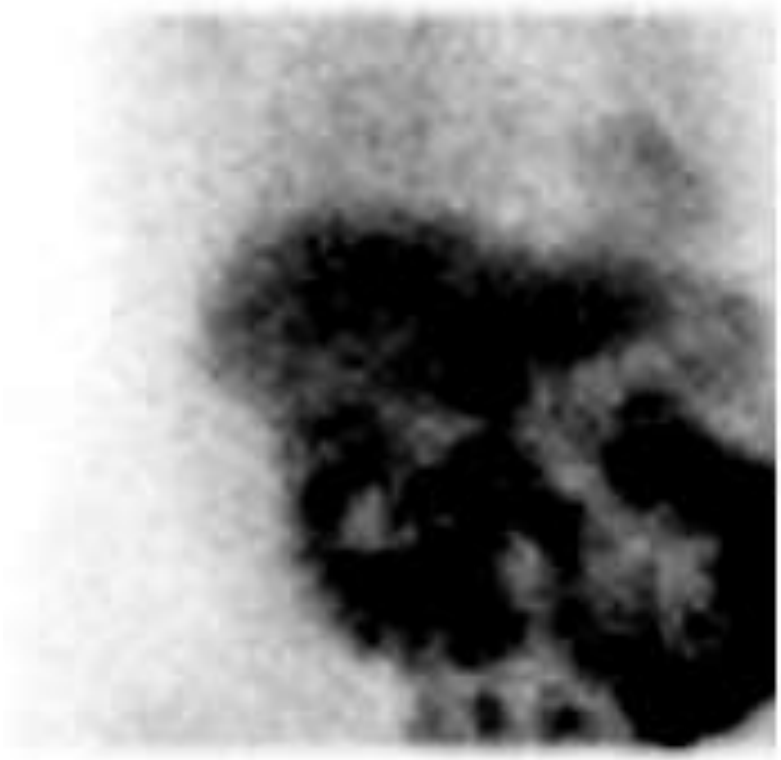

Image Acquisition Techniques

- Planar Imaging
  - Static
  - Dynamic
  - Multiple Gated (MUGA)
  - Whole Body
- Tomographic Imaging
  - Single Photon Emission Tomography (SPECT)
  - Positron Emission Tomography (PET)

Image Acquisition Techniques

- Planar Imaging
  - Static
  - Camera and organ within patient static
  - Images of physiological structure



Planar Imaging Static

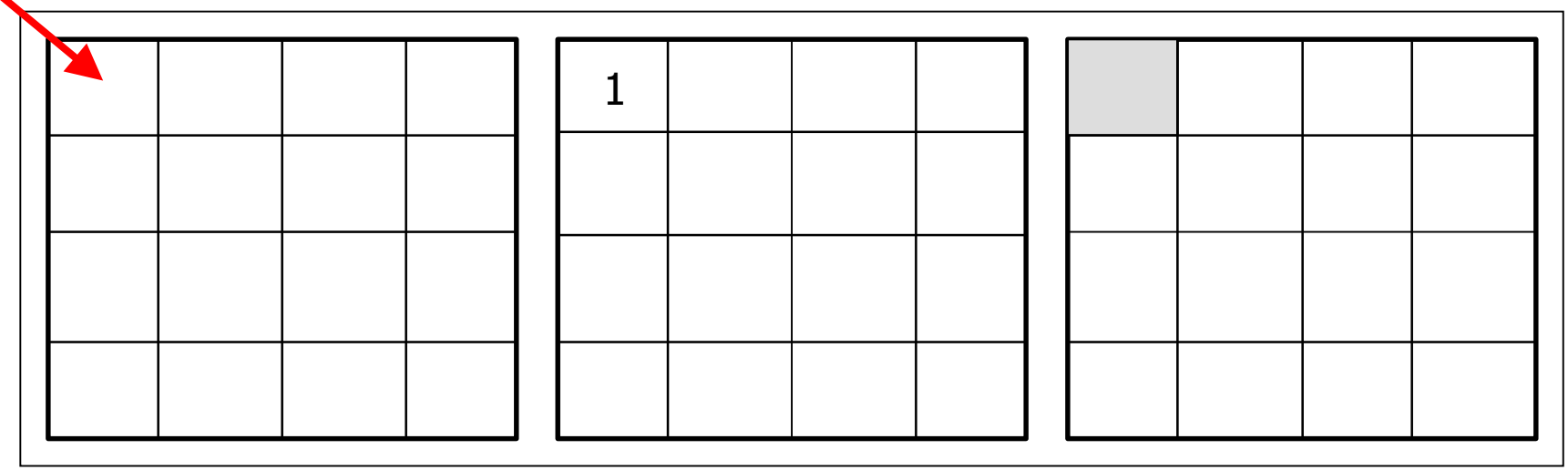

- Camera FOV divided into matrix of pixels
- Each pixel stores number of gamma rays detected at corresponding location on detector in the memory.

Planar Imaging Static

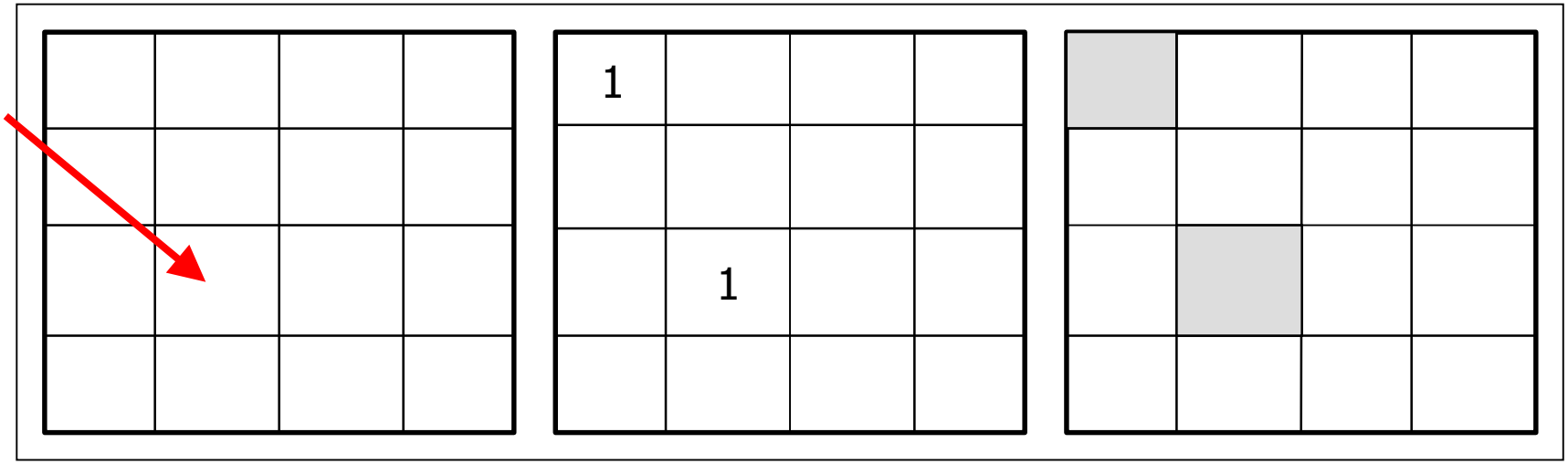

- Image is built up over time

Planar Imaging Static

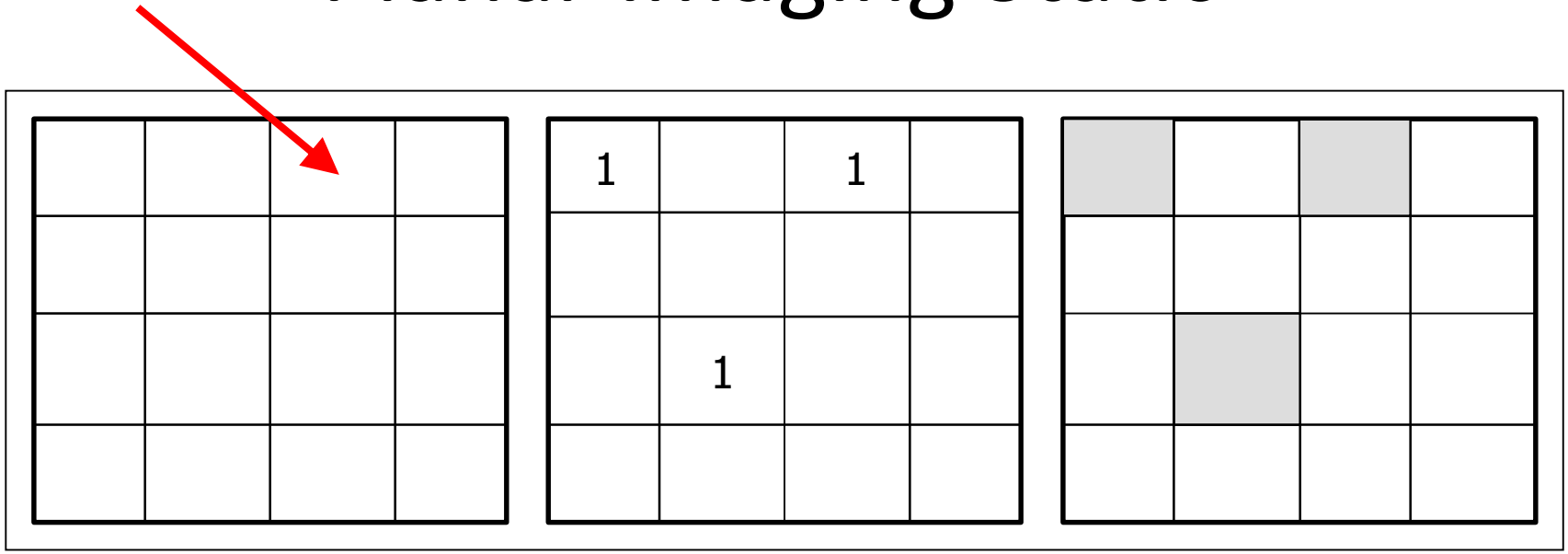

- Typical matrix sizes: 256^2, 128^2, 64^2

Planar Imaging Static

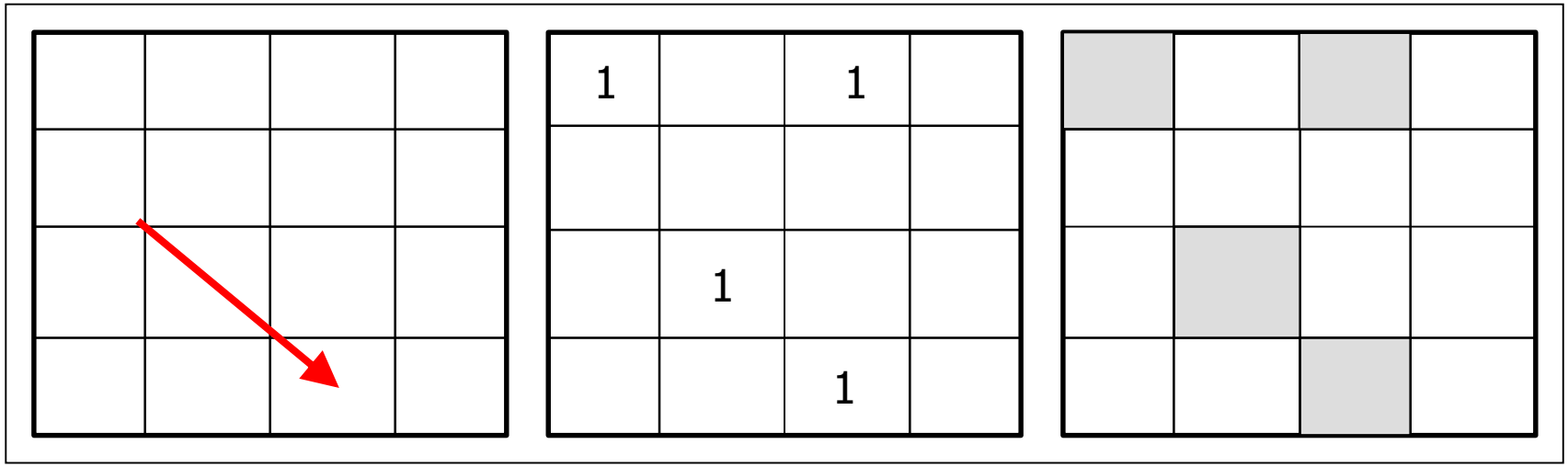

- Pixels darker that have detected more events

Planar Imaging Static

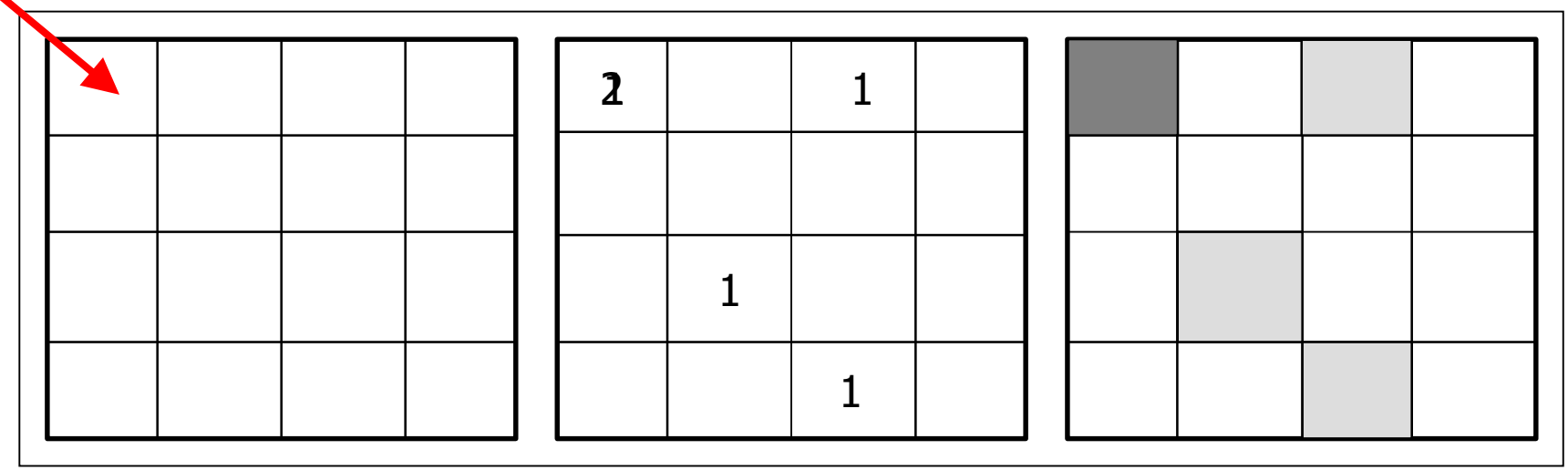

- Areas of increased uptake ‘hot spots’

Renal Imaging - DMSA

- Radiopharmaceutical
  - ^{99m}Tc-DMSA
- Imaged at 3-4 hours
- Effective dose
  - 0.7 mSv
- Investigates
  - renal scarring
  - non-functioning tissue
  - divided renal function
- Useful post UTIs

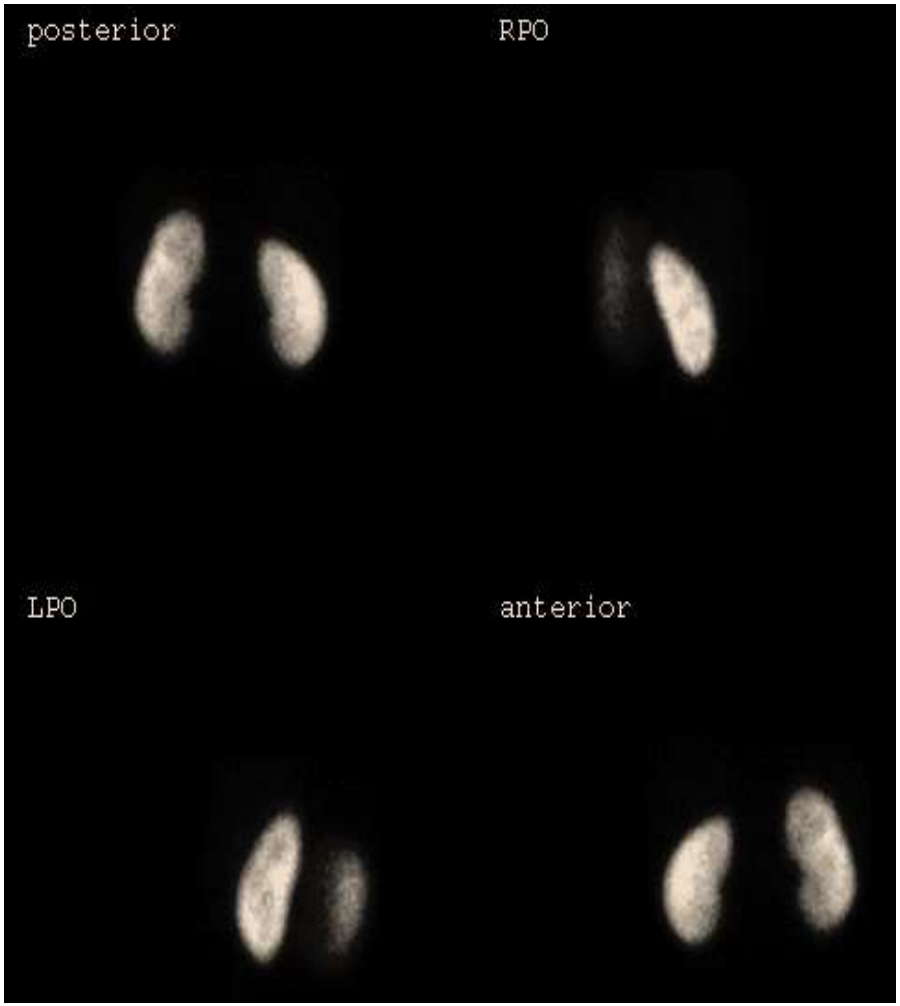

Case 1 – Normal Scan

- Divided function
  - Normal range: 45 - 55%
- Normal scan
  - bilateral smooth renal outlines
  - equal sized kidneys

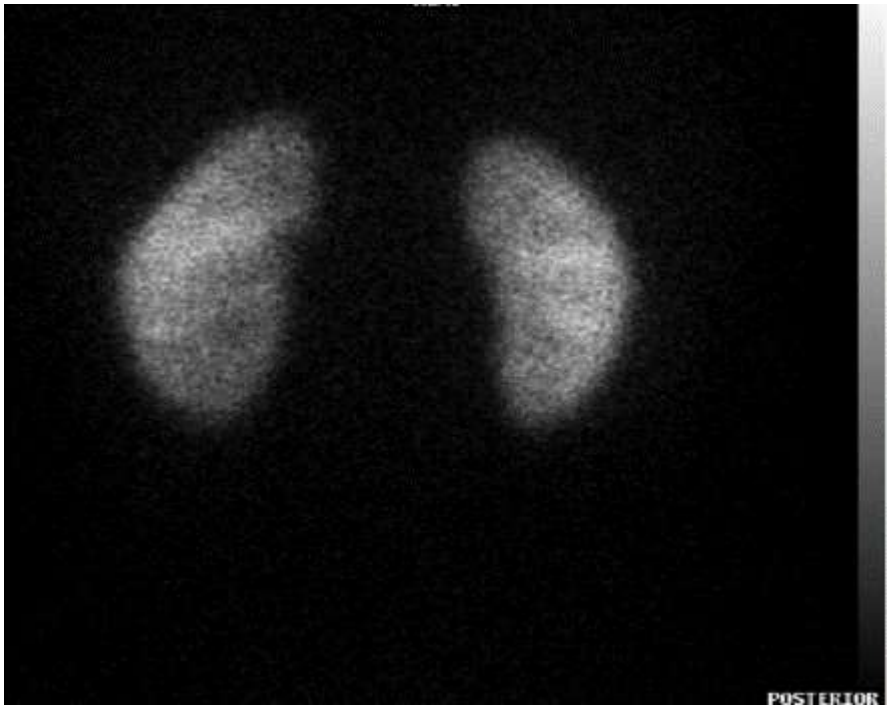

Case 2 – Renal Scarring

- More sensitive than ultrasound
- Focal scarring in left kidney
- Atrophic right kidney

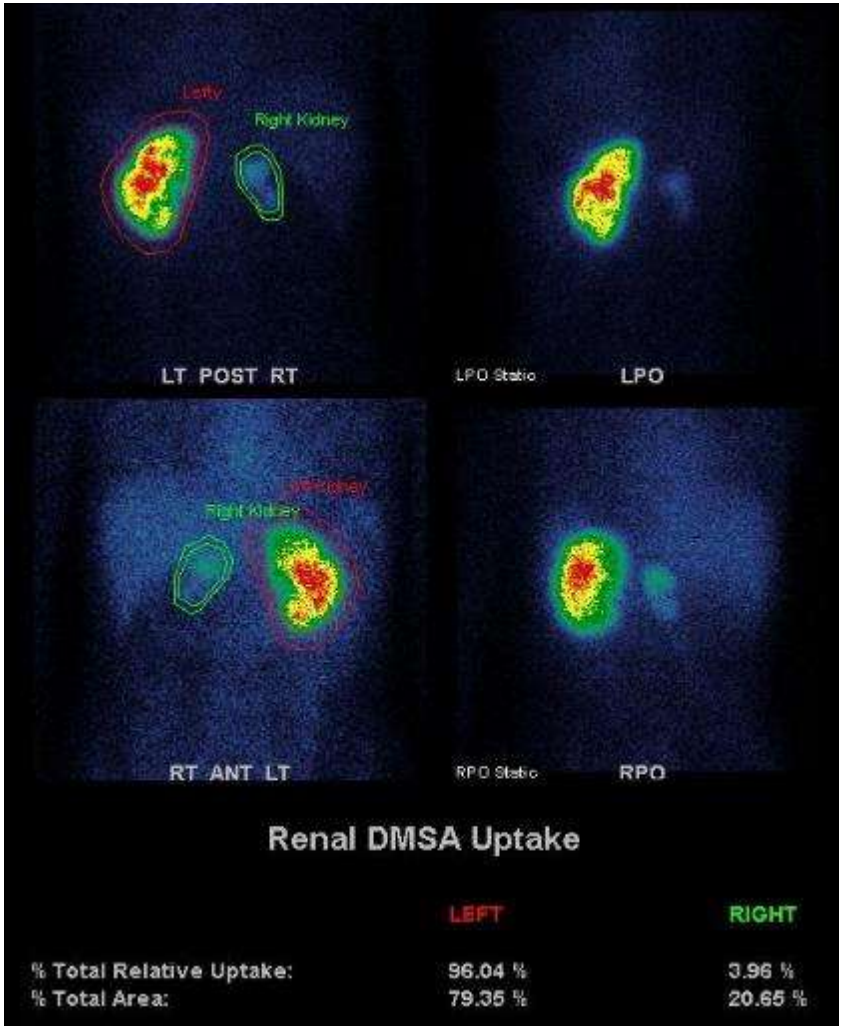

Image Acquisition Techniques

- Planar Imaging
  - Static
  - Dynamic
    - Camera and patient static,organ process moving
    - Images of physiological process



Dynamic Imaging

- Series of sequential static images
  - e.g. 90 frames each of 20sec
- Images
  - changing distribution of activity within the patient
- Examples include:
  - gastric emptying studies
  - lymphoscintigraphy
  - diuretic renography



Diuretic Renography

- Radiopharmaceutical
  - ^{99m}Tc-MAG3
- Imaged immediately
- Effective dose
  - 0.7 mSv
- Investigates
  - suspected obstruction
  - dilated system
  - pre-transplant donor assessment



Case 1: Normal Study

Hull University Teaching Hospitals NHS Trust

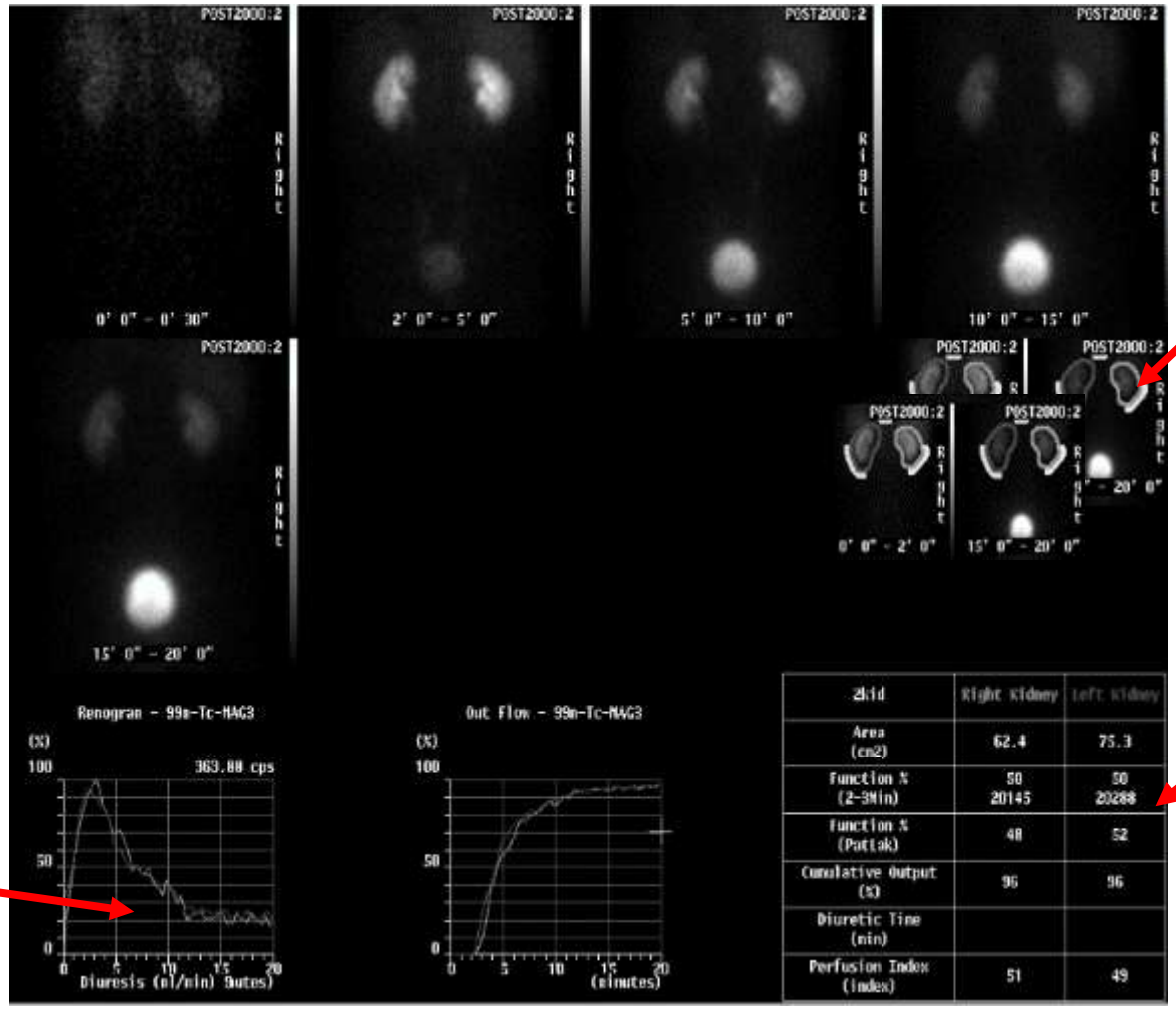

Regions of Interest (ROI)

Curves showing changing renal activity over time

Split Renal Function

Case 2: Obstructed System

Hull University Teaching Hospitals NHS Trust

Rising time-activity curves on both kidneys

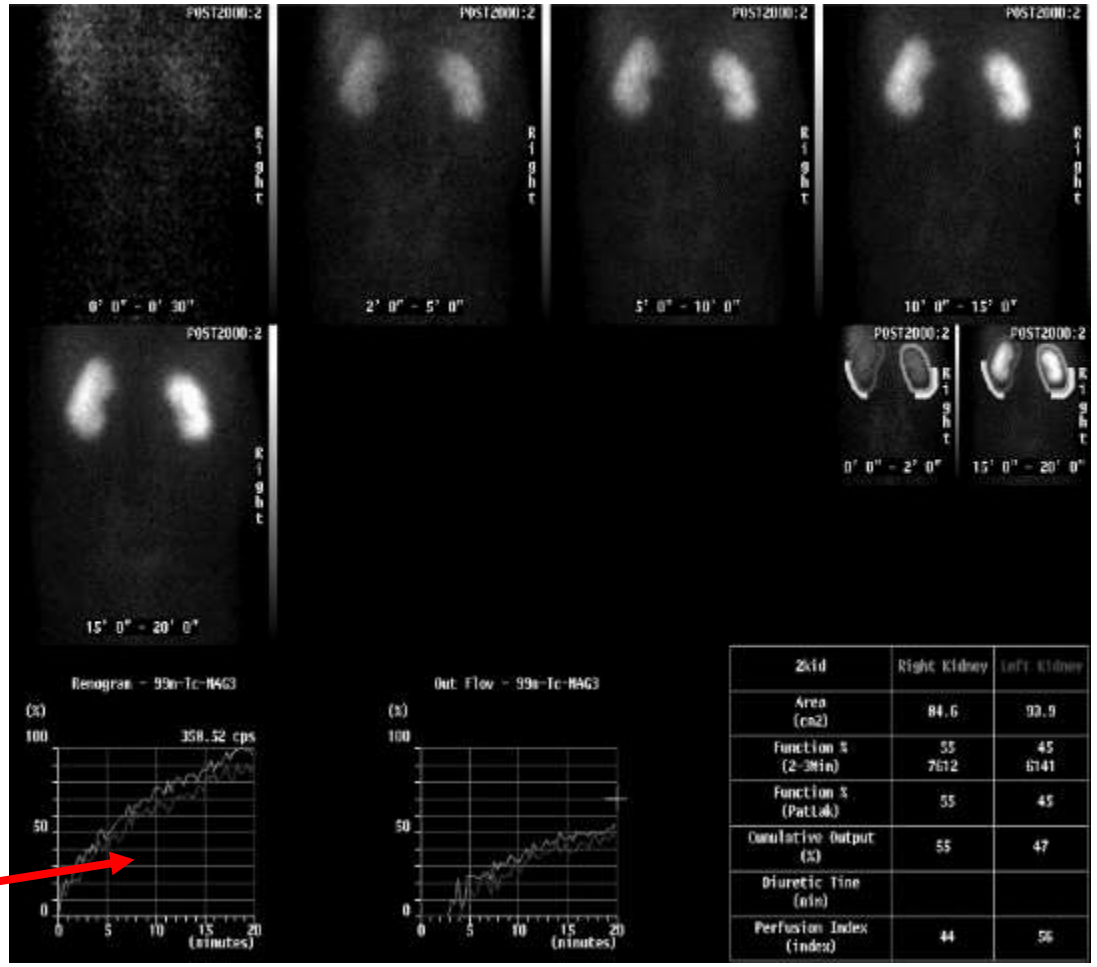

Image Acquisition Techniques

- Planar Imaging
  - Static
  - Dynamic
  - Multiple Gated (MUGA)





Multiple Gated Acquisition Imaging (MUGA)

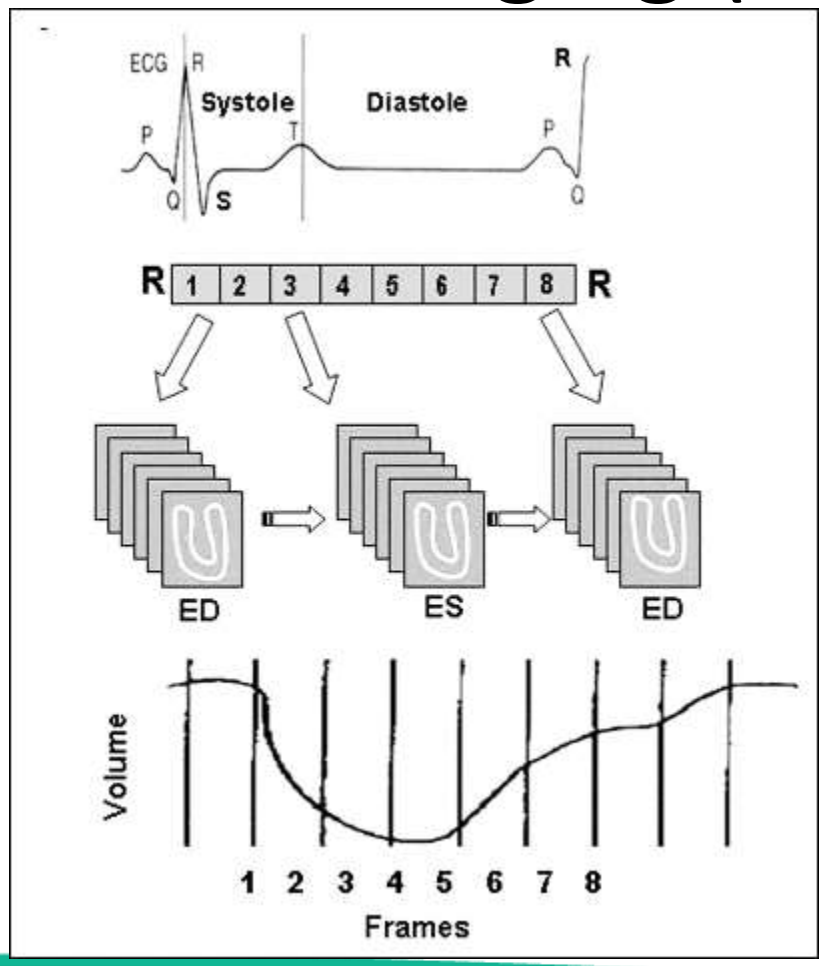

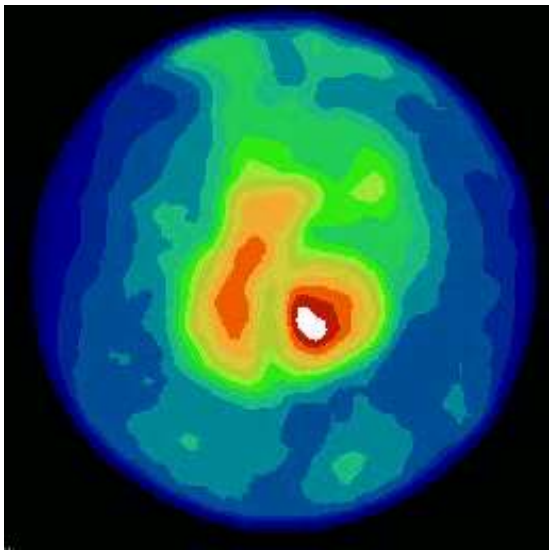

- Multiple images/frames acquired over each cardiac cycle
- ‘Build up’ acquisition over many cycles

Radionuclide Ventriculography (RNVG)

- Radiopharmaceutical
  - Tc-99m labelled red cells
- Imaged immediately
- Effective dose
  - 6 mSv
- Investigates
  - left ventricular function
  - regional wall motion



- Allows precise/repeatable measurement of LVEF
  - left ventricular ejection fraction

Radionuclide Ventriculography

- LVEF value
- Cardiotoxic drugs

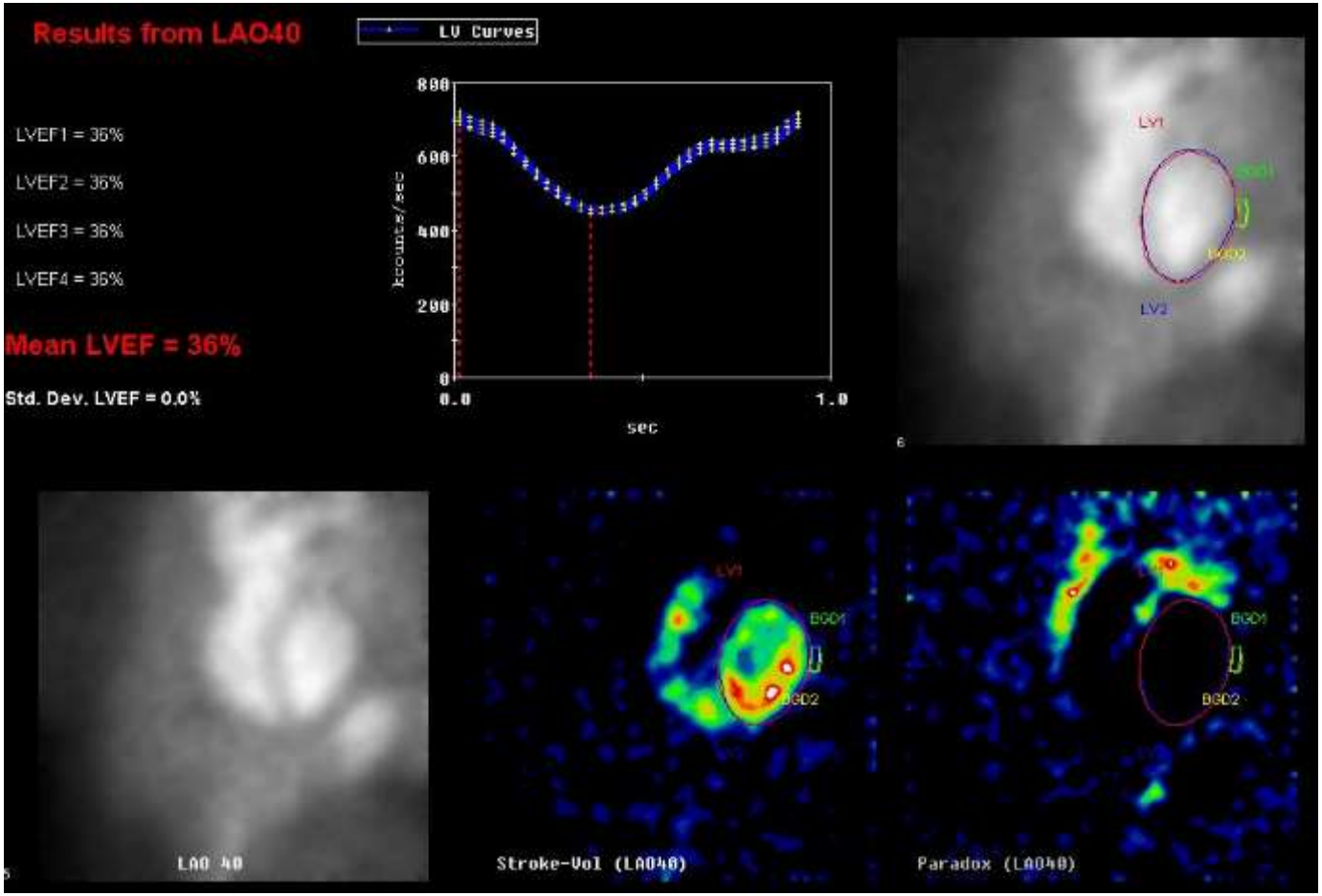

Image Acquisition Techniques

- Planar Imaging
  - Static
  - Dynamic
  - Multiple Gated (MUGA)
  - Whole Body / Continuous



Whole Body Imaging

- A window (or ramp)
  - opens along the camera face
  - and then slowly scans down the body
- Ramps down as camera
  - reaches the preset end of the body
- Sensors on the camera (PSD's)
  - ensure detectors remain close to the patient



Case 1

- Radiopharmaceutical
  - ^{99m}Tc-HDP
- Imaged at 3-4 hrs
  - High bone to soft tissue ratio
- Effective dose 3 mSv
- Symmetry
- Kidneys and bladder

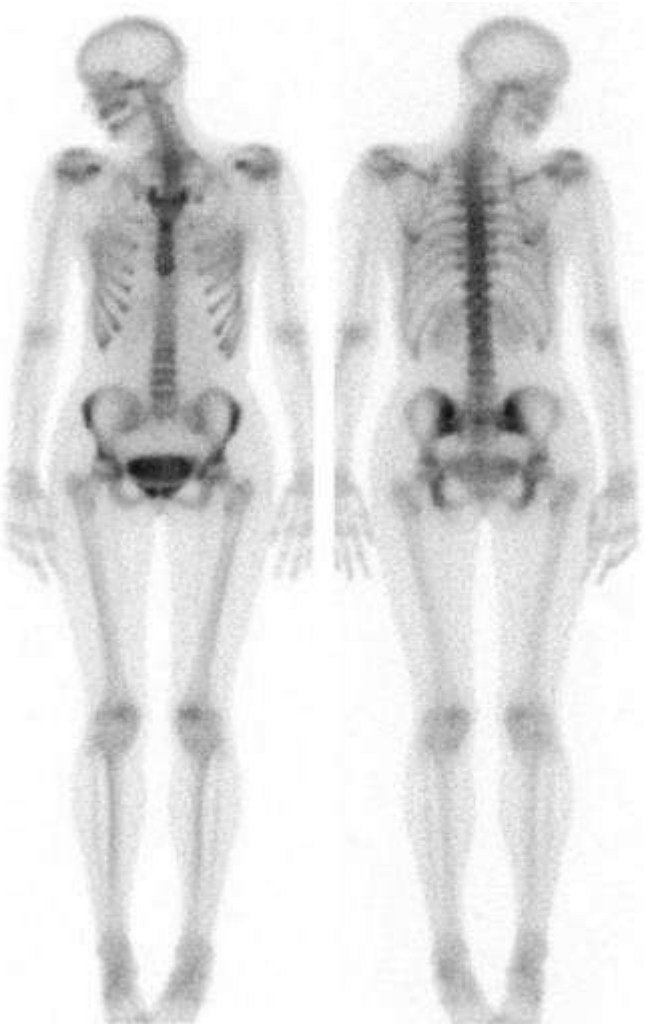

Case 2

- Focal uptake
  - throughout axial skeleton
- Osteo*blastic* metastases
  - breast and prostate
  - high sensitivity
- Osteo*lytic* metastases
  - Renal, breast, lung, myeloma
  - Reduced sensitivity

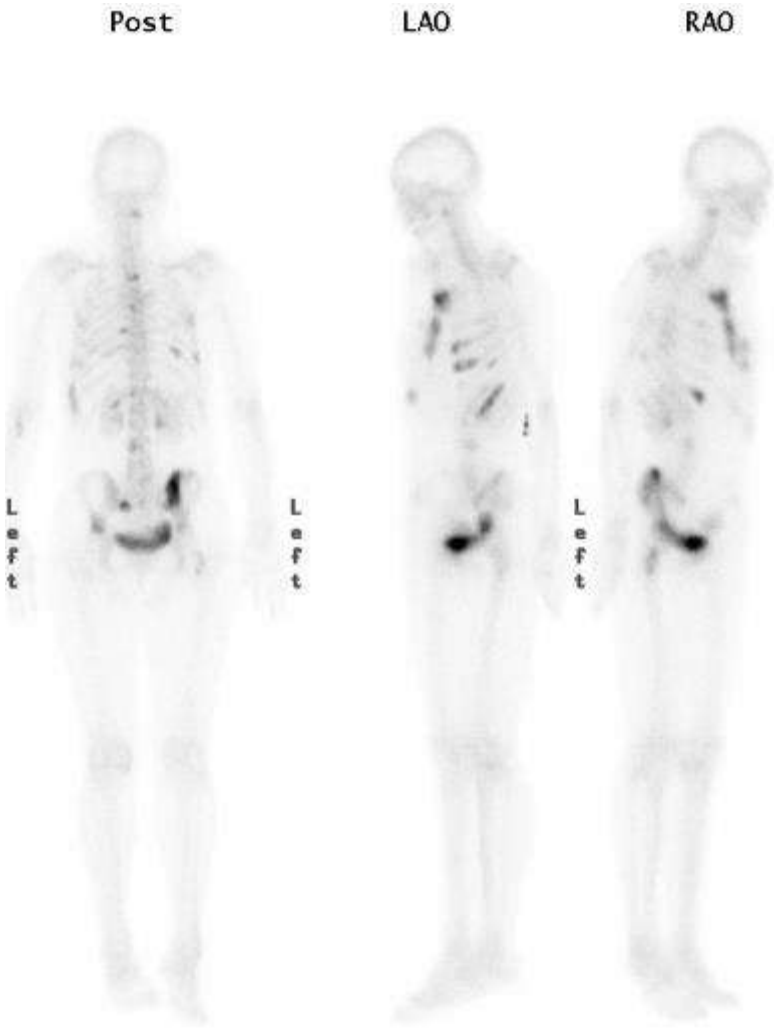

NHS
Hull University Teaching Hospitals
NHS Trust

Remarkable people.
Extraordinary place.

Case 3

- Superscan
- Non-visualisation of
  - kidneys
  - soft tissue
- Poor visualisation of
  - limb bones
- Diffusely increased
  - Skeletal uptake
- Causes
  - widespread metastases

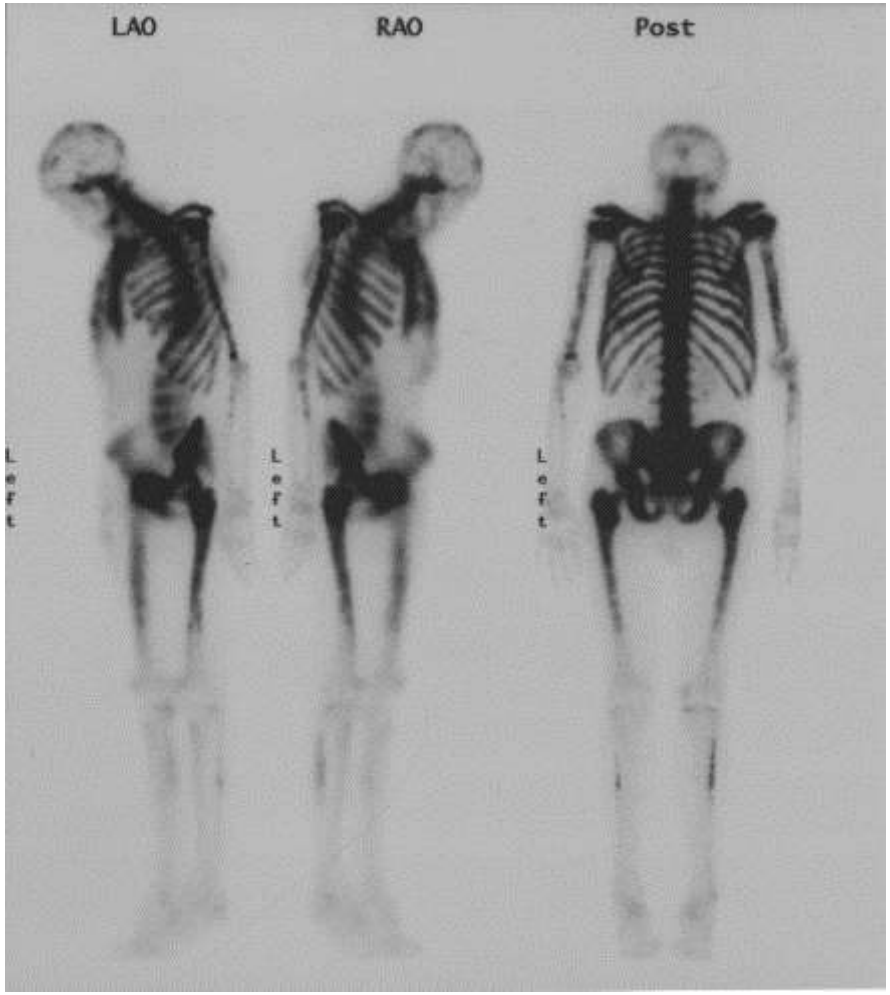

Pitfalls of Planar Imaging

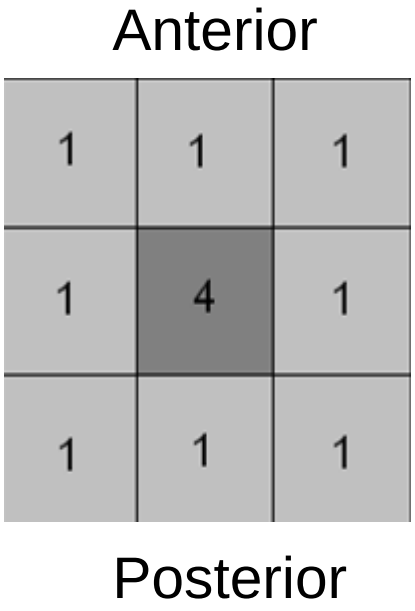

- Planar imaging
  - 2D representation of 3D distribution of activity
  - No depth information

Pitfalls of Planar Imaging

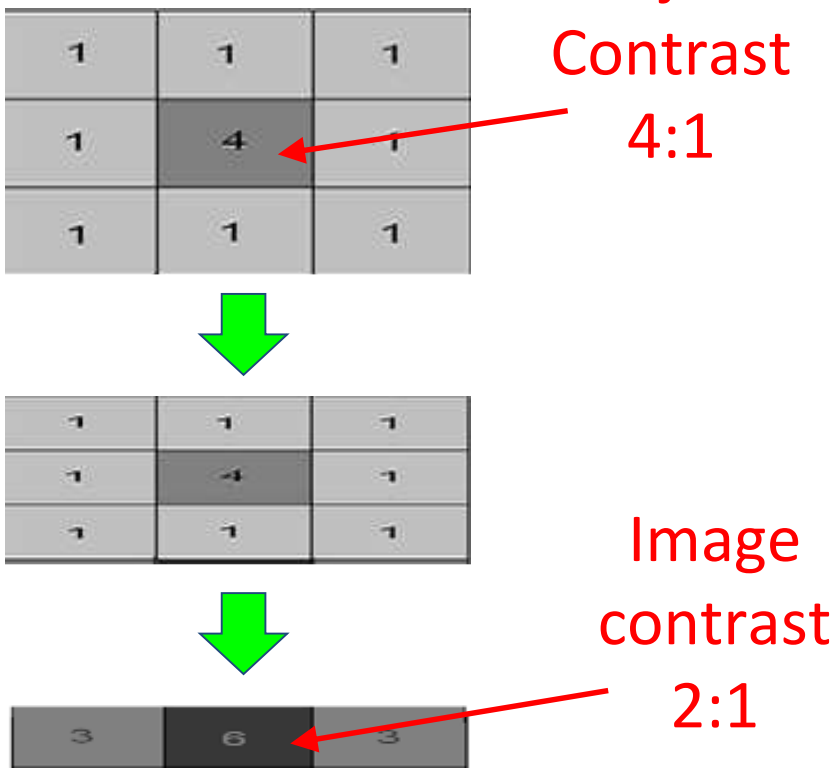

- Planar imaging
  - Structures at different depths superimposed
  - Loss of contrast


Thank you for listening