NHS
Hull University Teaching Hospitals
NHS Trust

FRCR Lecture III



SPECT Imaging

Nuclear Medicine



Dr Helen Gill
Clinical Scientist
Nuclear Medicine Department
Castle Hill Hospital
Hull University Teaching Hospitals NHS Trust
email: helen.gill@hey.nhs.uk

Image Acquisition Techniques

- Tomographic Imaging
  - Single Photon Emission Tomography (SPECT)
  - Positron Emission Tomography (PET)

Advantages

- 3D localisation and depth information
- Attenuation correction

Tomographic Imaging - SPECT

- SPECT improves contrast for 'cold' lesions
- Important in myocardial perfusion imaging (MPI)
- Reduced perfusion in normal myocardium
- Example of anterior reversible defect

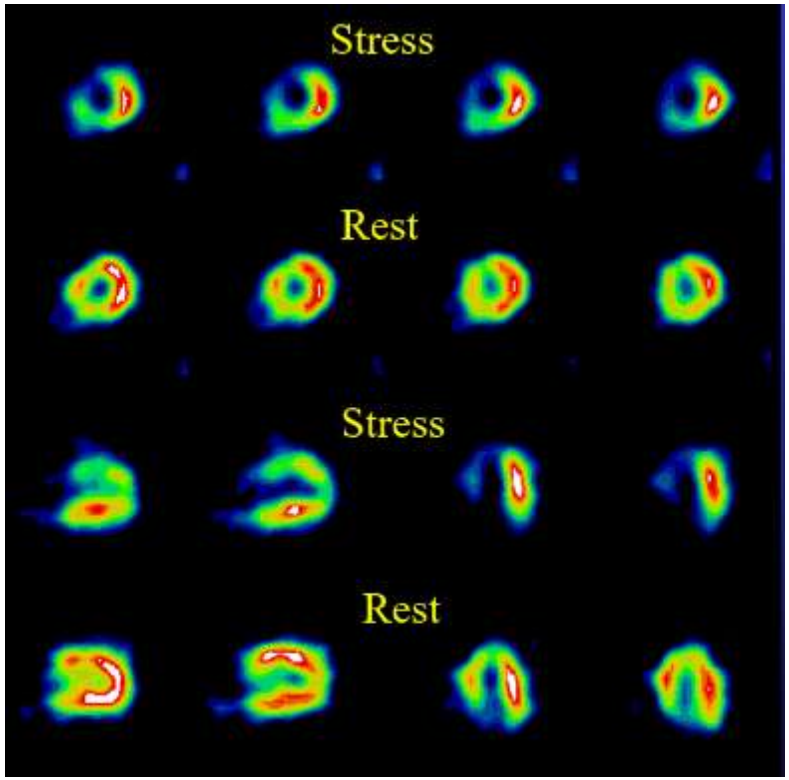

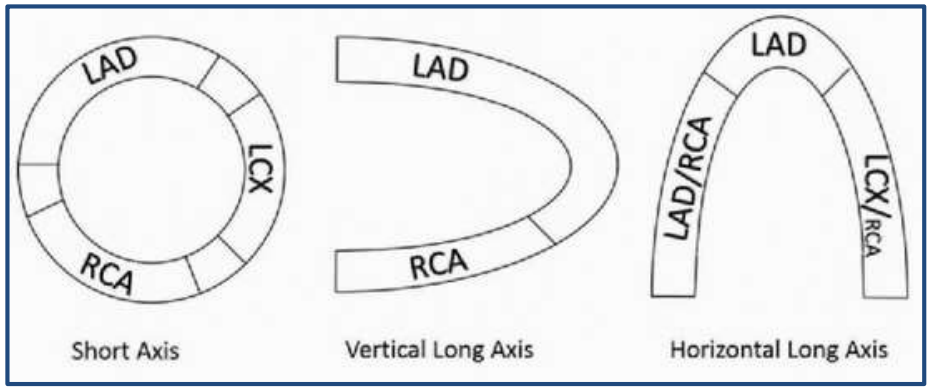

Tomographic Imaging - SPECT

γ/X-rays SPECT

Isotope	Half-life (hr)	Energy (keV)
^{99m}Tc	6.0	140
^{111}In	67.3	171 & 245
^{123}I	13.2	159
^{201}Tl	73.0	69-83

Tomographic Imaging - SPECT

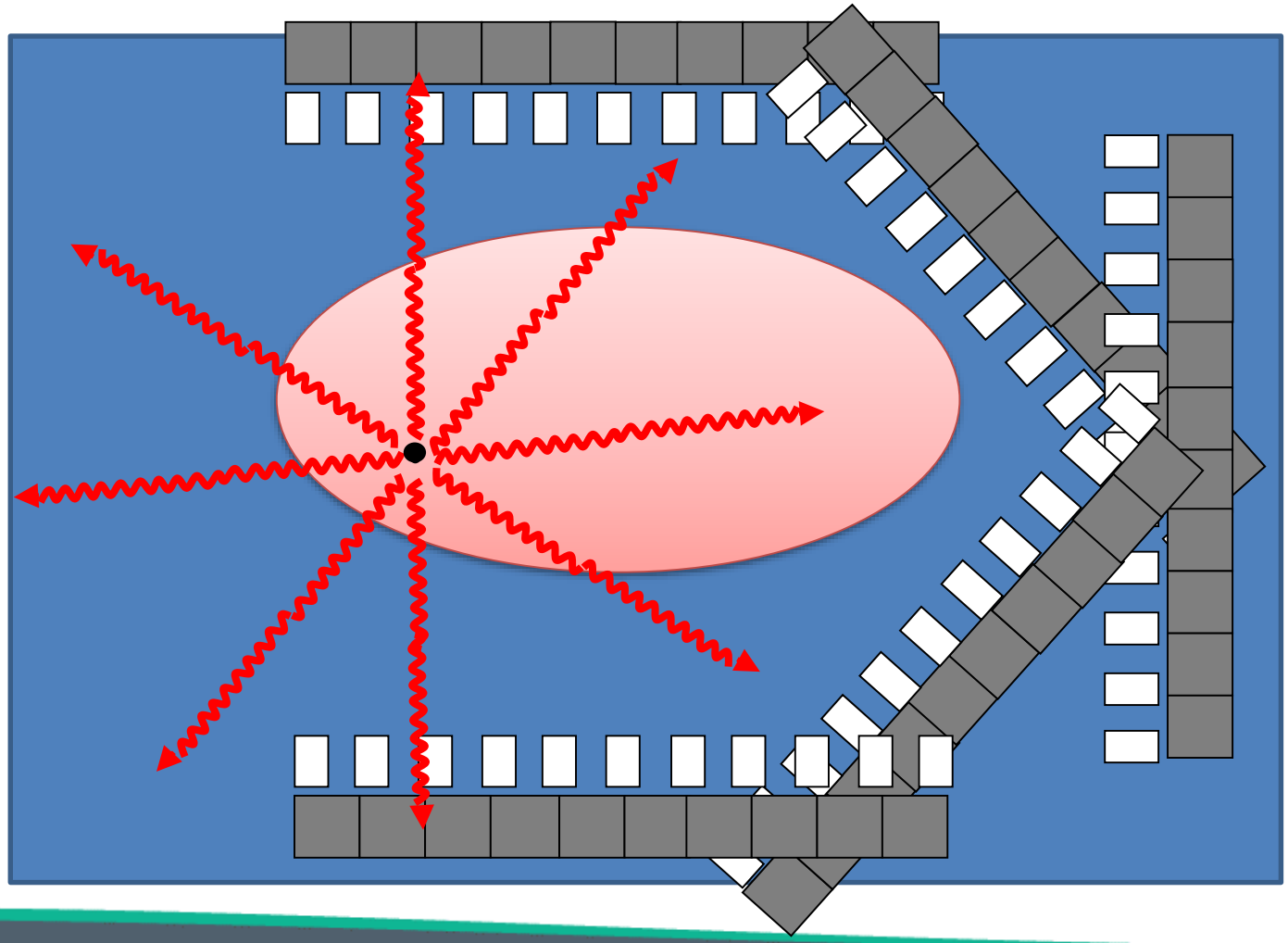

Tomographic Imaging - SPECT

- Multiple planar projections acquired at set angles
- Projections processed
  - Filtered Backprojection
  - Iterative Reconstruction



SPECT Image Acquisition

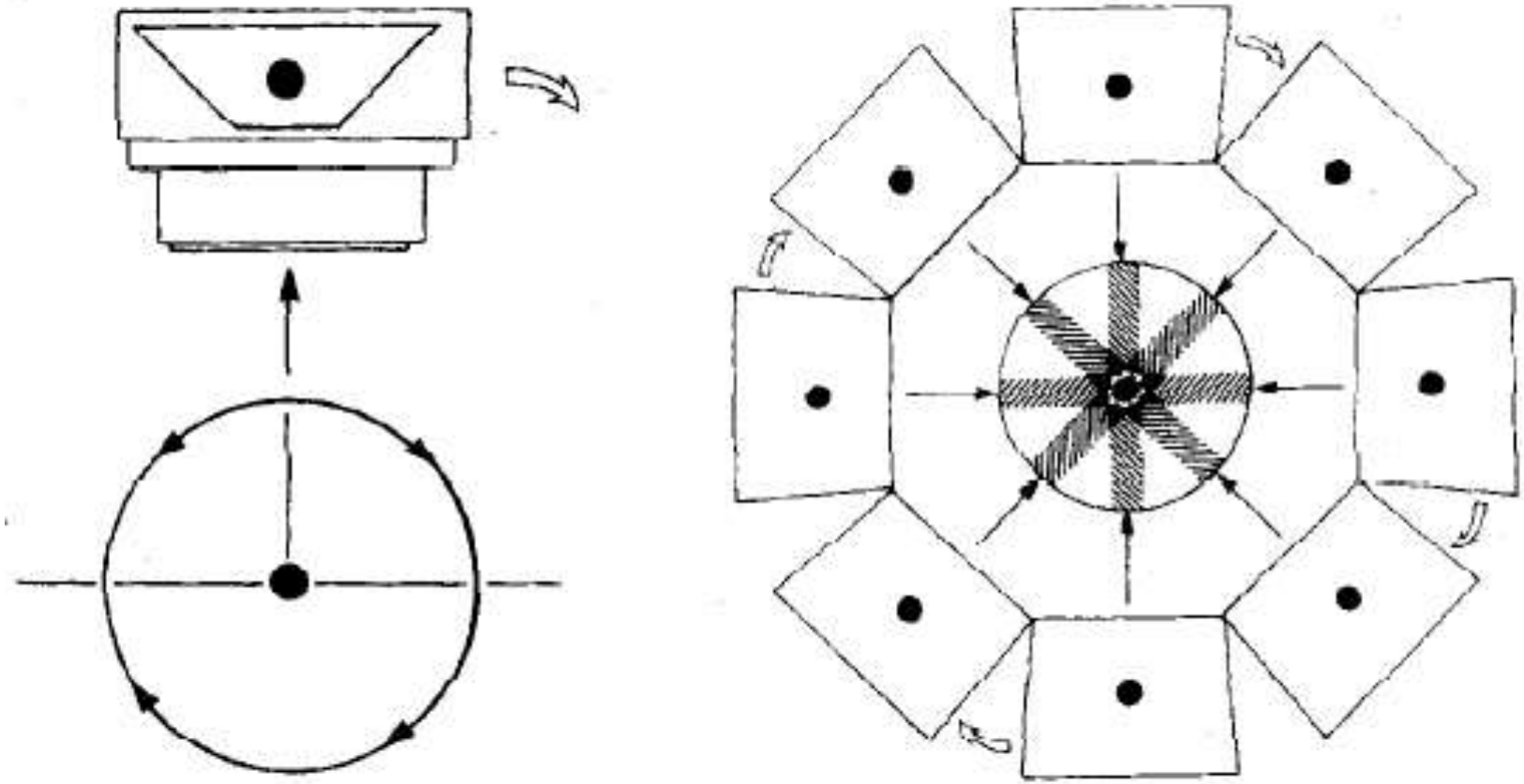

SPECT Image Acquisition

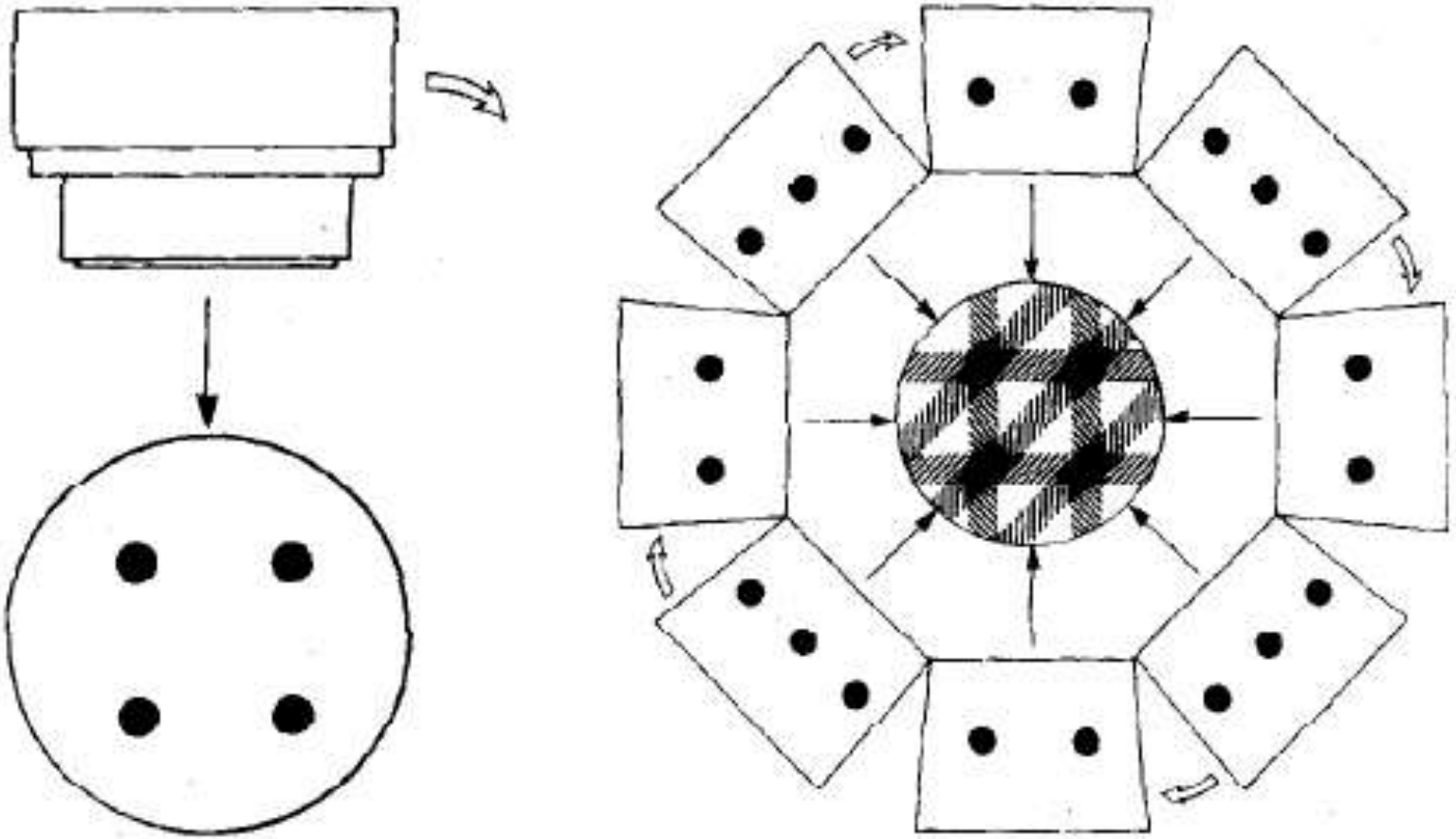

Image Backprojection

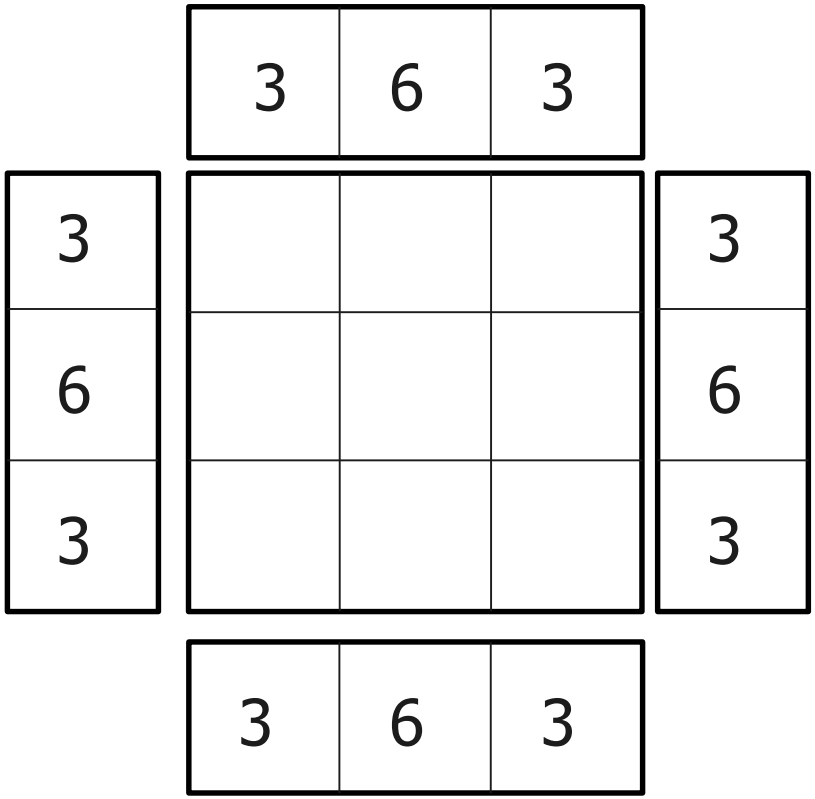

- Backproject each planar image onto the 3D image matrix

Backprojection - Image 1

Image 1

3	6	3
1	2	1
1	2	1
1	2	1

- Image 1 projection backprojected onto the 3D image matrix

Backprojection - Image 1 & 2

Hull University Teaching Hospitals NHS Trust

Image 1

Image 2

	3	6	3
3	2	3	2
6	3	4	3
3	2	3	2

- Planar images 1 and 2 backprojected onto the 3D image matrix

1	1	1
2	2	2
1	1	1

Backprojection- All Images

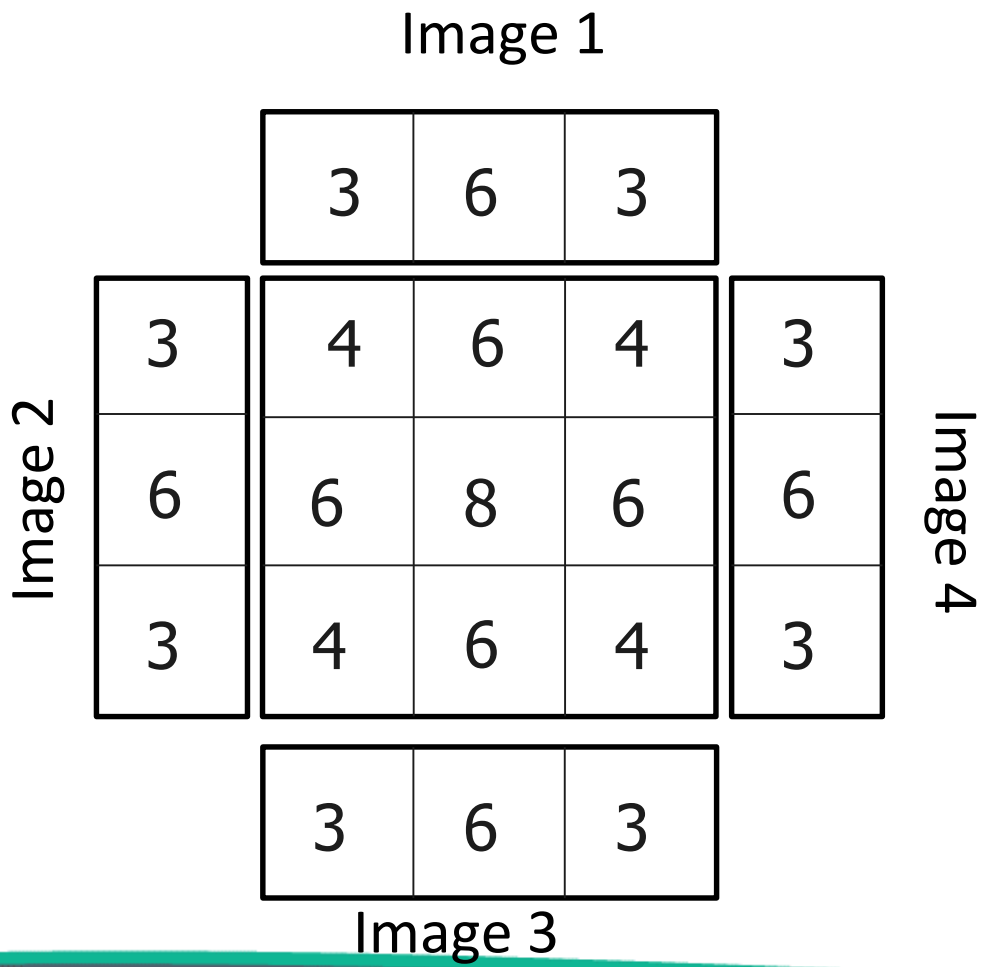

- All image projections backprojected onto the 3D image matrix
- The values now represent the reconstructed image

Backprojected 3D Image

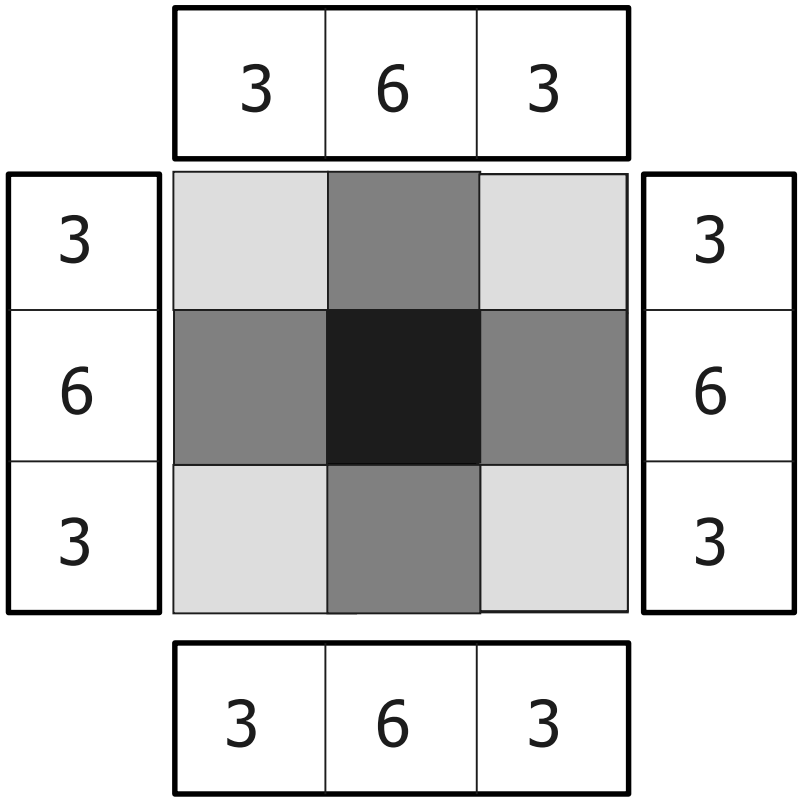

- Backprojected image created from number of counts in each pixel
- Two angle projection
- More projections better reconstruction



Filtered Backprojection FBP

NHS
Hull University Teaching Hospitals
NHS Trust

- Mathematical way to reconstruct a tomographic image

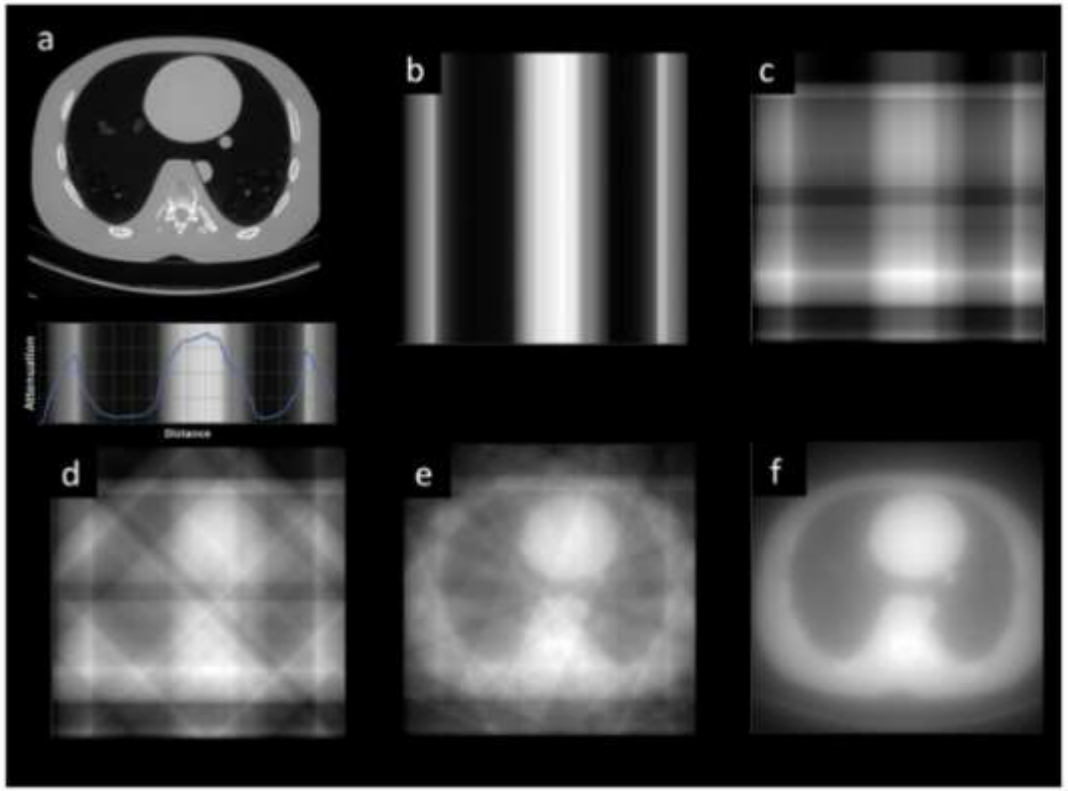

Remarkable people.
Extraordinary place.

Problems with FBP Reconstructed Images

- Crude representation of distribution of activity
- Blurring even with infinite number of projections
- Need to filter out the low spatial frequency components in the projections
- Use a ramp filter

Ramp Filter

- Utilises a RAMP filter
  - To suppress blurring
  - Used for all routine tomographic reconstructions



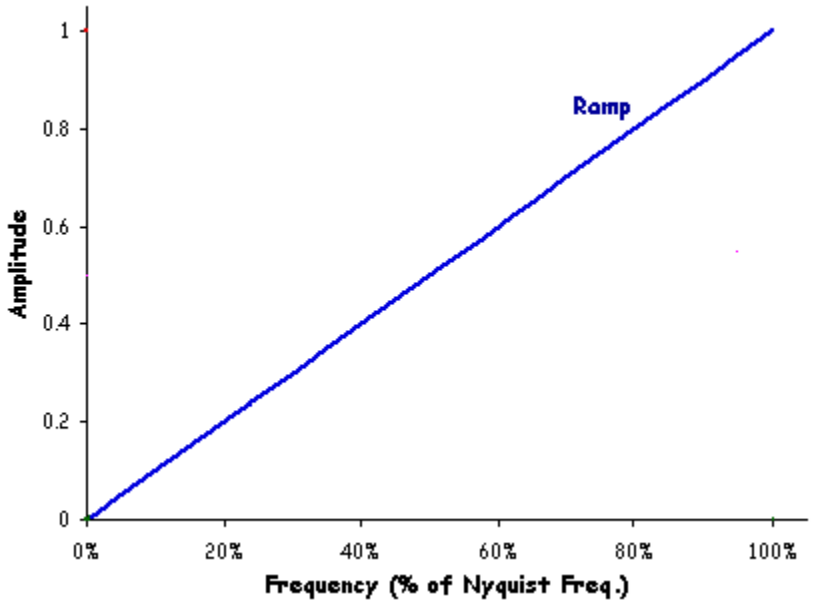

Smoothing Filter

- RAMP filter + smoothing filter
  - goal is to create an image easier to “read”



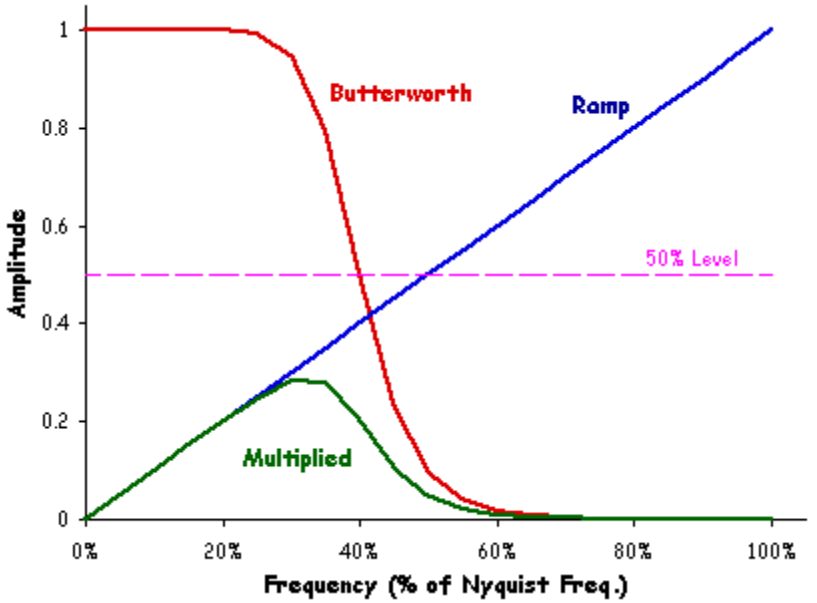

Disadvantages of FBP

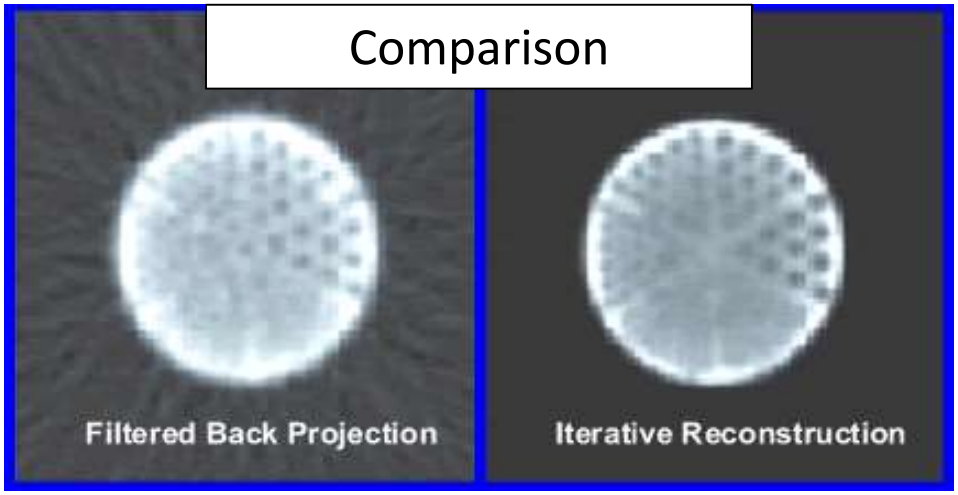

FBP can :

- introduce noise and streaking artefacts
- degrade spatial resolution

FBP cannot :

- apply attenuation correction

Iterative Reconstruction (IR)

- It is NOT a new technique
  - pre-dates filtered backprojection
- Computationally intensive
  - long reconstruction times
  - requires fast computers for reconstruction

What is it ?

- Reconstruction based on successive “guesses” of the image
- Computer refines expected projections in comparison to those acquired
- This IR is “Maximum Likelihood Expectation Maximisation” (MLEM)

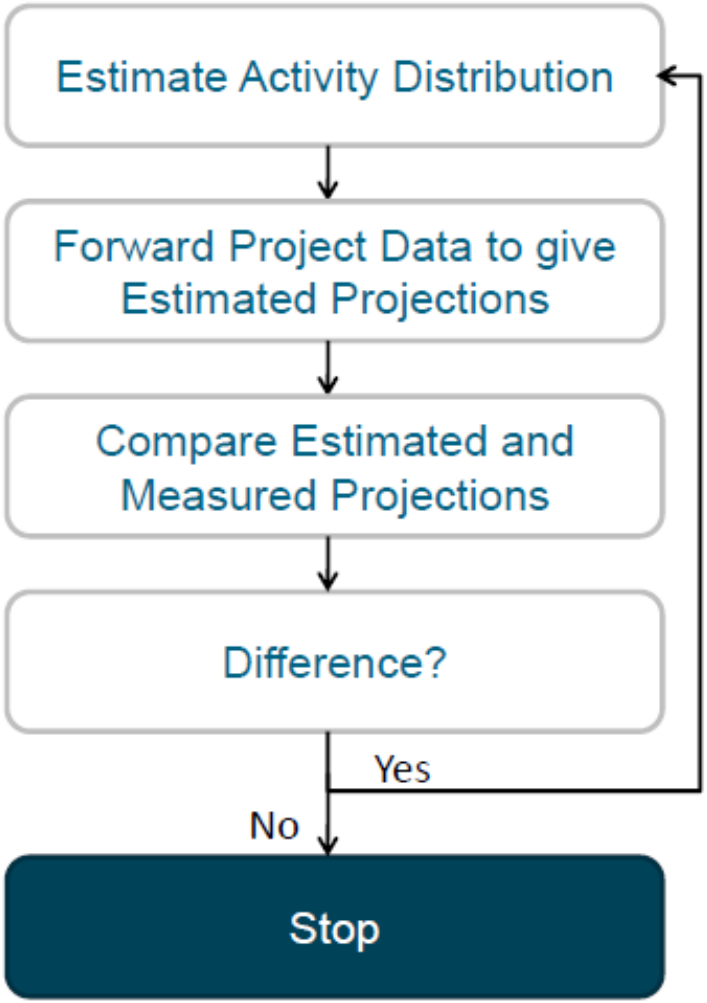

Iterative Reconstruction

- Since iterative reconstruction makes estimates it can be used to correct for image degradation due to :
  - Attenuation
  - Scatter
  - Loss of image resolution

What is attenuation ?

- The removal of photons as it passes through matter
- Attenuation is caused by :
  - absorption
  - scatter



Attenuation Correction (AC) What does it do ?

NHS
Hull University Teaching Hospitals
NHS Trust

- Aim :
  - to correct for attenuation suffered by the organ of interest
- Attenuation effects :
  - can be interpreted with training
- AC :
  - boosts the counts from deepest organs
  - image represents actual activity in the organ
  - leads to improved quantitation and image quality
  - can improve the diagnostic accuracy of the scan

Remarkable people.
Extraordinary place.

Attenuation Correction How does it do it ?

- Raw SPECT image with attenuation effects
- Create attenuation map
- Need to have transmission properties through the body



CT AC Method

A CT image :

- is a transmission image
- is a cross sectional array of attenuation coefficients at different angular projections
- can be reconstructed into an image attenuation map
- can be registered to the SPECT data



CT AC Method

Hull University Teaching Hospitals NHS Trust

Tissue attenuation coefficients

Attenuation effects





AC SPECT image



SPECT data

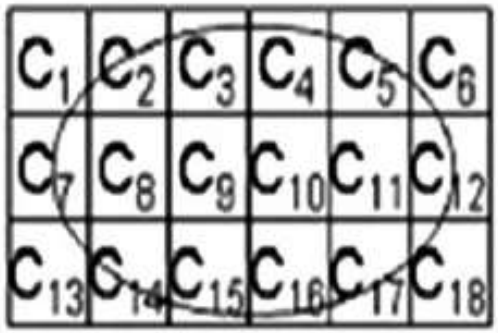

Image attenuation map

X

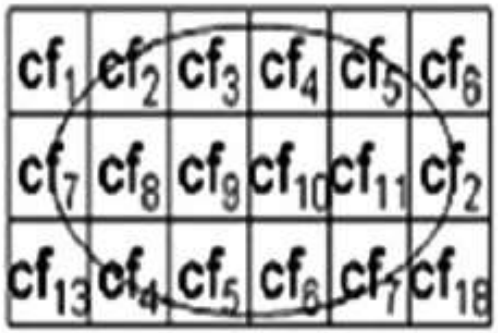

=

AC SPECT data

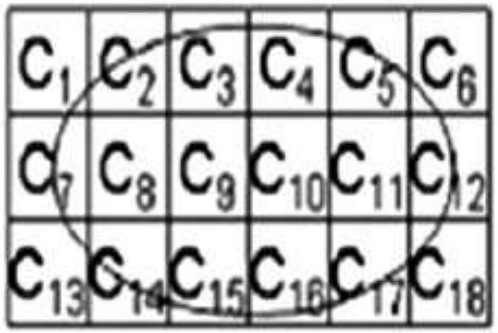

CT AC Method





+

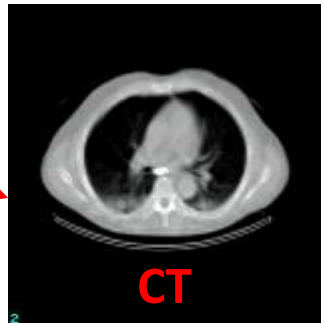

Attenuation Correction

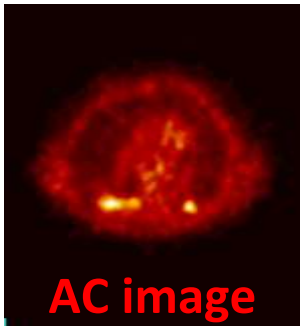



Image Registration (Fusion)

Resolution Recovery (RR)

Spatial resolution

- worsens with increasing

  distance from the collimator

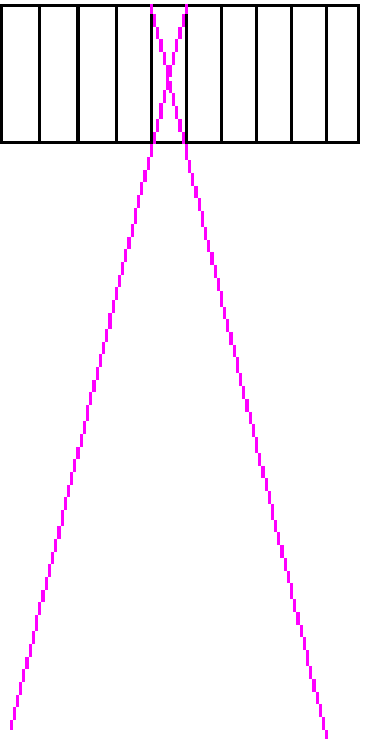

Resolution losses modelled

- put into iterative reconstruction

Resolution Recovery

- Better modelling means better images
- Fewer counts needed to get acceptable images
  - shorter acquisitions
  - lower doses

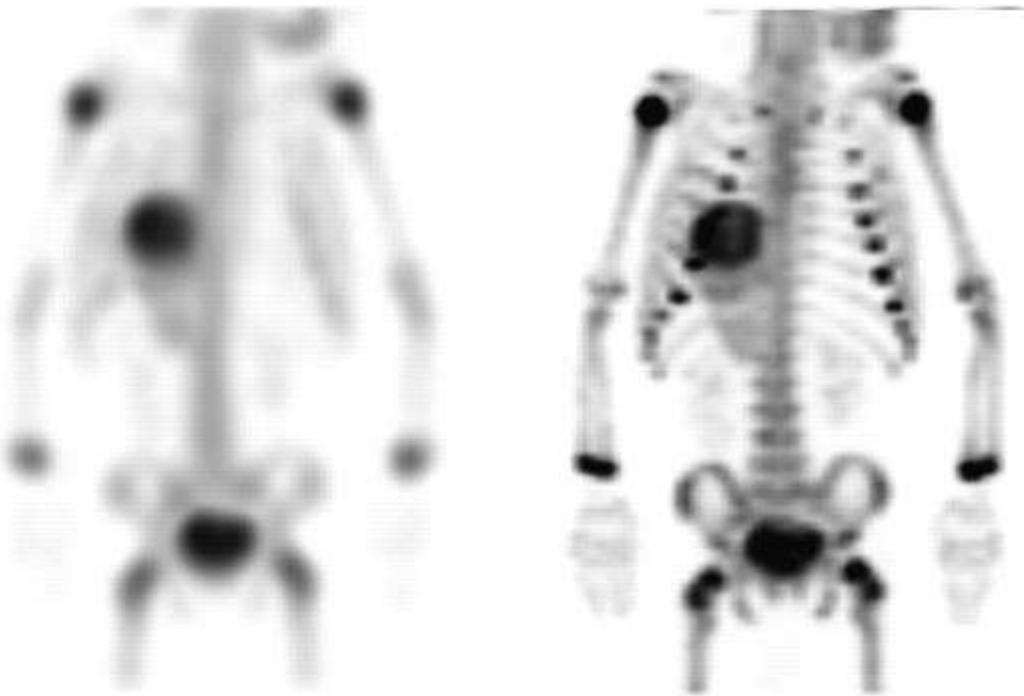

Full counts
FBP

Half counts
OSEM 3D

SPECT Applications
Cardiology



Myocardial Perfusion Imaging (MPI)

- Coronary artery blood flow proportional to uptake of radiopharmaceutical in heart
- Stress and rest studies performed
- Stress - exercise or pharmacologic stress
- Gated SPECT (unless in AF)
- Radiopharmaceuticals
  - ^{99m}Tc-MIBI or Tetrofosmin (13mSv)
  - ^{201}Tl (thallous chloride) (14mSv)
- To look at wall motion, thickening and ejection fraction

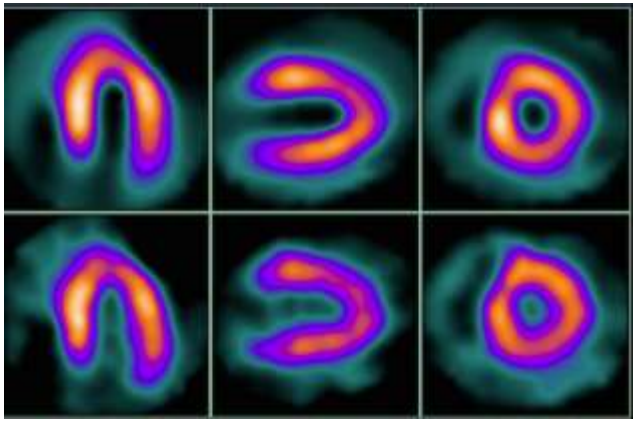

Case 1: Reversible Ischaemia

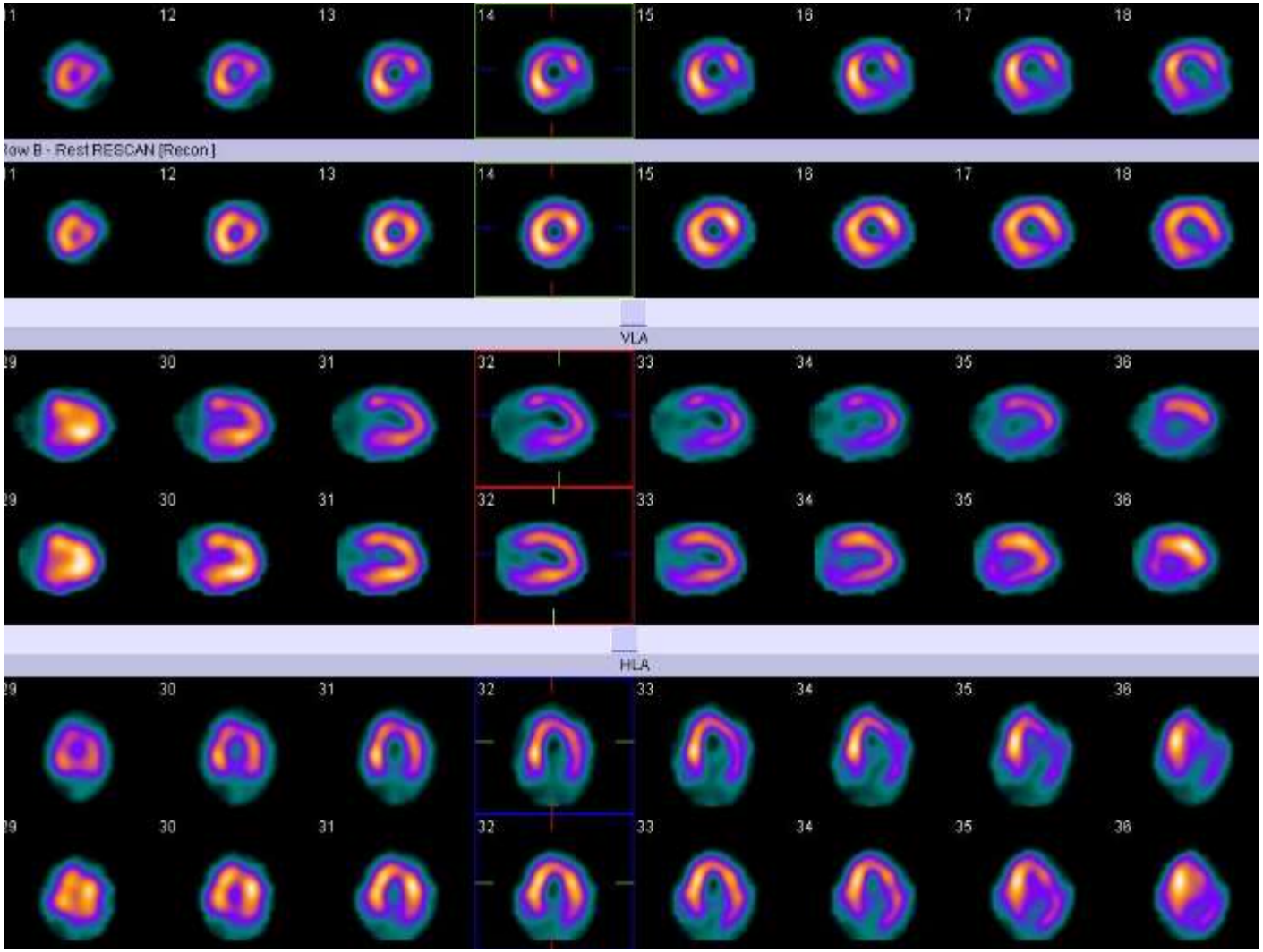

NHS
Hull University Teaching Hospitals
NHS Trust

Remarkable people.
Extraordinary place.

Case 2: Infarct

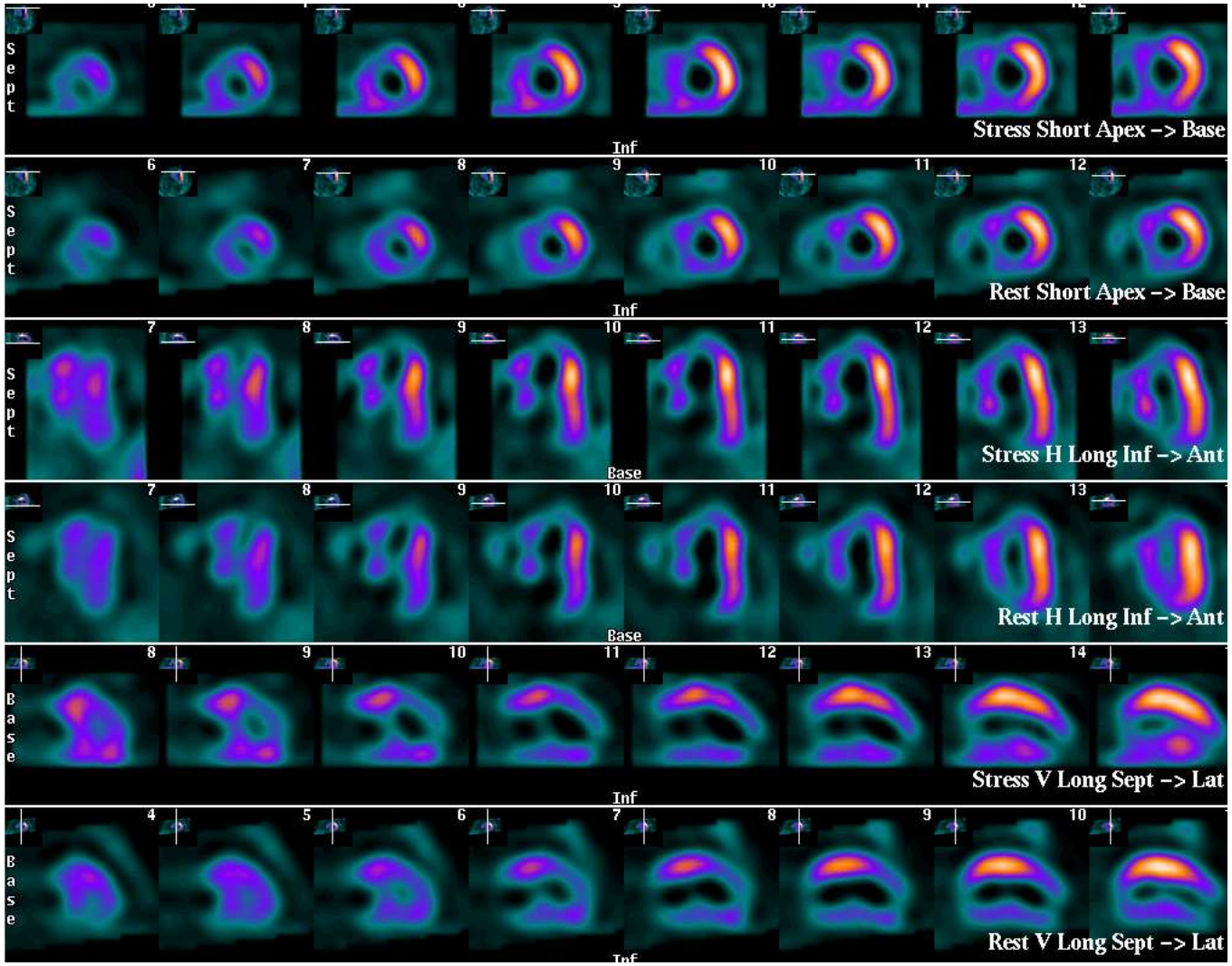

Hull University Teaching Hospitals NHS Trust

Remarkable people.
Extraordinary place.

SPECT Applications
Oncology

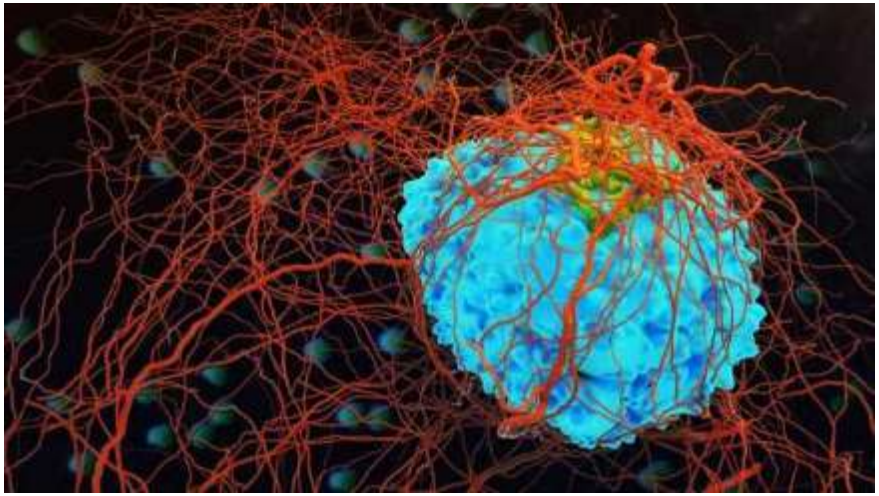

Bone SPECT



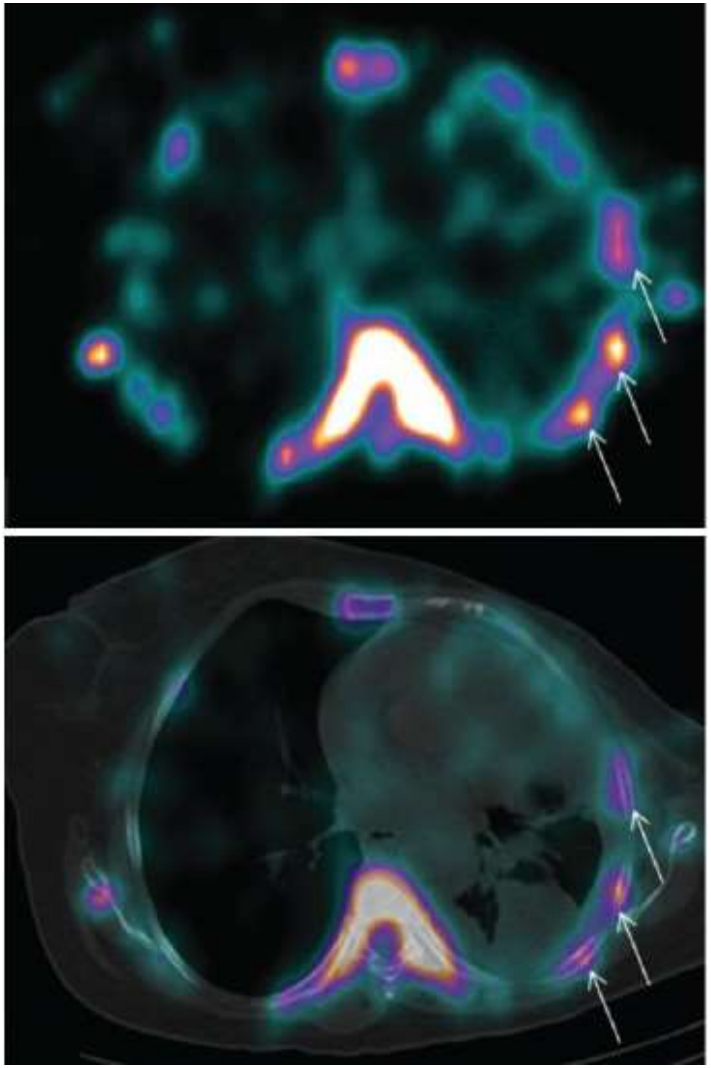

SPECT Applications
Neurology

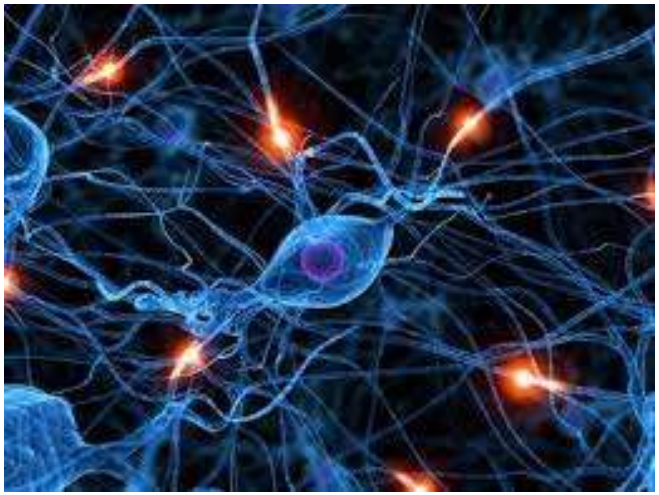

DaTSCAN Brain Imaging

- Radiopharmaceutical ^{123}I-Ioflupane
- Imaged at 3-6 hours
- Effective dose 4.4 mSv
- Differentiates between ET, Drug-induced parkinson's and Parkinsonism syndromes
- Assesses the severity of Parkinsonism syndromes



Case 1: Normal Scan

- Ioflupane binds to pre-synaptic dopamine transporters
- **Normal appearance is comma shaped putamen**
- Abnormal “full stop” shape of one or both putamen

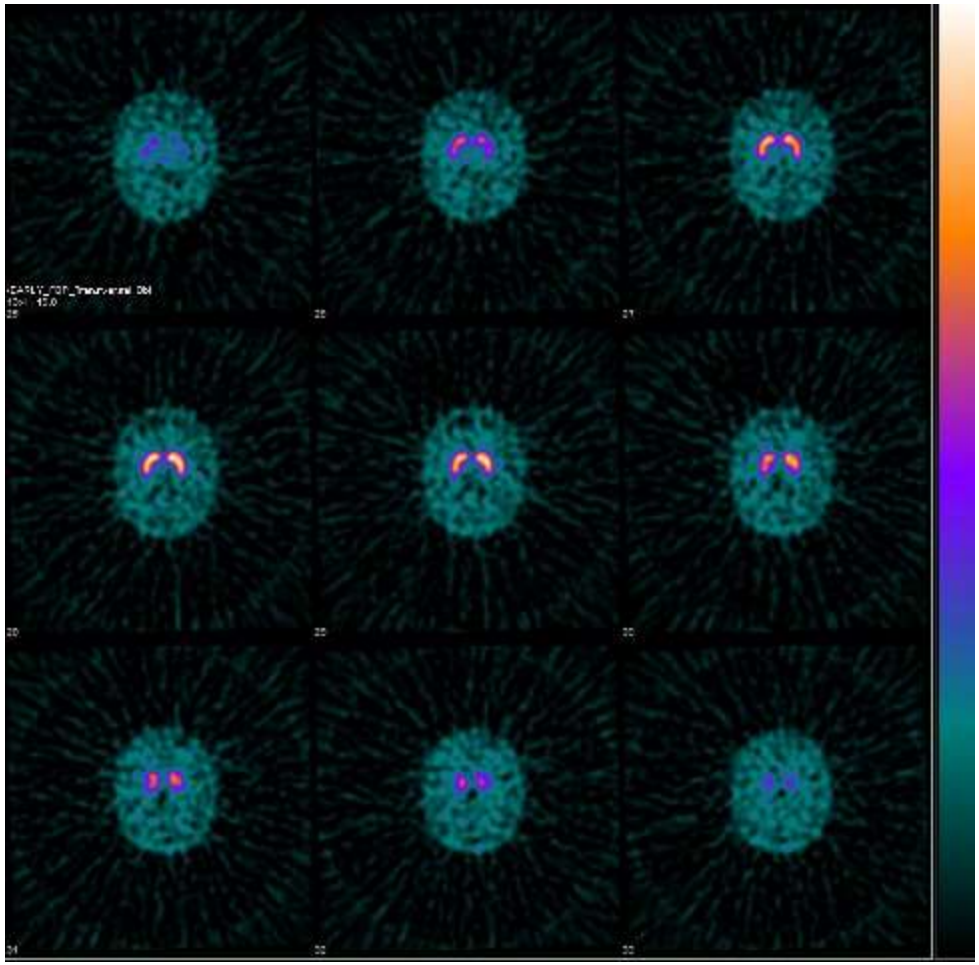

Case 2: Abnormal Scan

NHS
Hull University Teaching Hospitals
NHS Trust

- Clinical details : parkinsonium
- Findings : symmetrical reduced uptake throughout the striata particularly the putamen
- **Consistent with Parkinson's disease or parkinsonism syndromes**

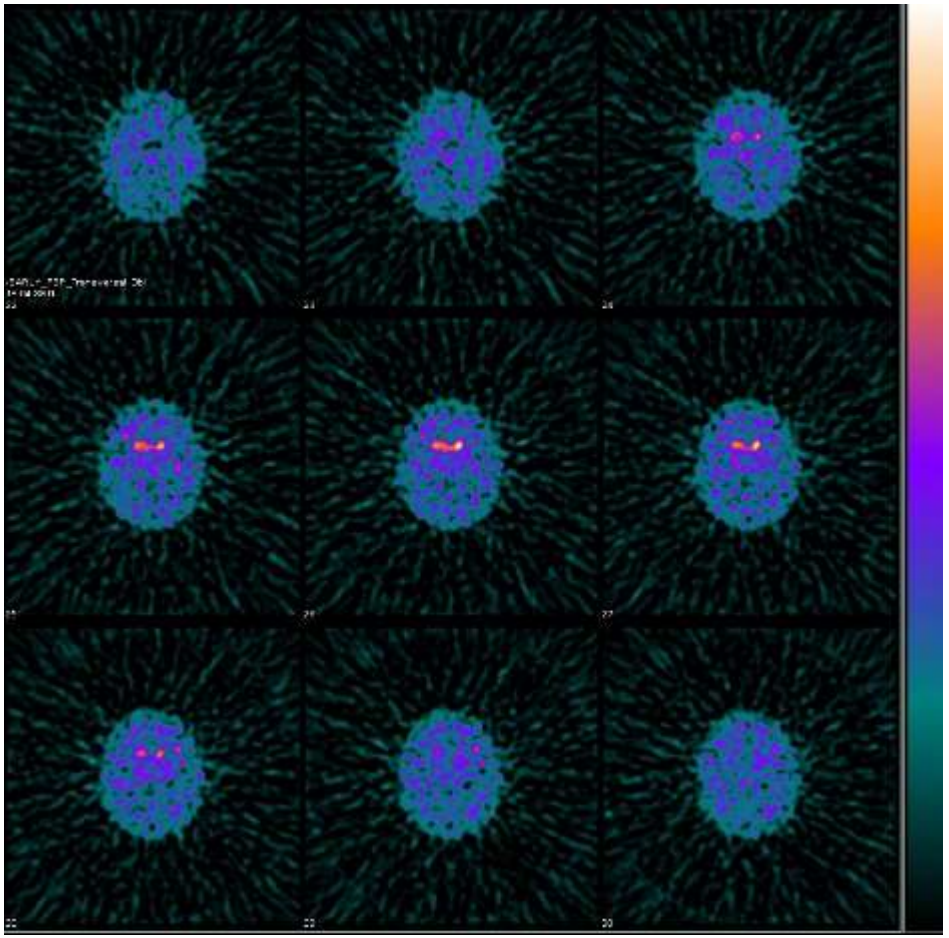

Case 3: Abnormal Scan

Hull University Teaching Hospitals NHS Trust

Severely abnormal

- Significantly reduced uptake
- Possibly dementia with Lewy bodies, Parkinson's disease

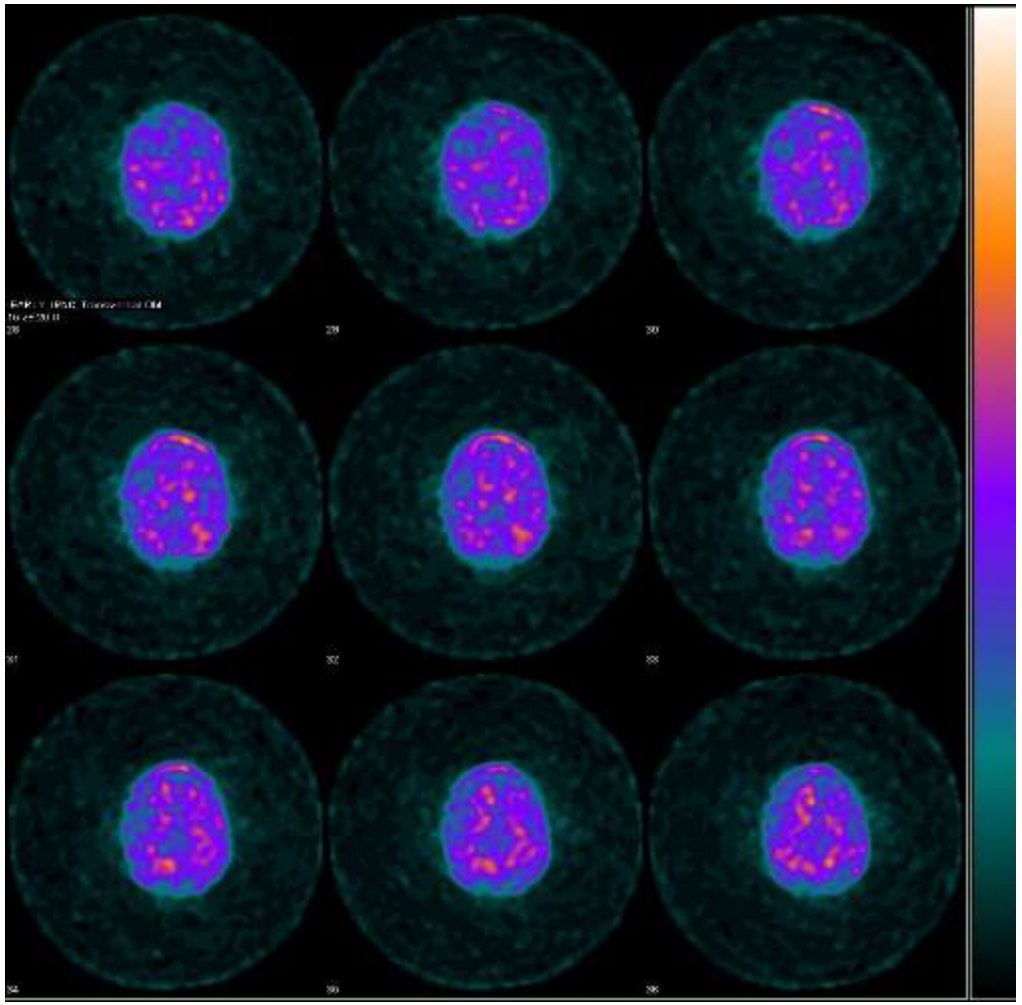

Thank you for listening

